

The Use of an Implantable Doppler Flow Probe in Kidney Transplantation: First Report in the Literature

Jeremy Crane, Nadey Hakim

Abstract

Objectives: After a kidney transplant, surveillance of the graft blood supply is crucial. Any delay in detecting compromised graft perfusion affects organ survival. Current practice uses Doppler ultrasound to monitor vessel patency and graft perfusion and is performed repeatedly after kidney and pancreas transplant. We have used an implantable probe that allows for easy vessel attachment and safe, continuous, audible monitoring of vascular anastomoses. It has been used to observe microvascular tissue transplants, free flaps, and pediatric liver transplants, but as yet, it has not been used to monitor kidney allografts. We feel a transplanted kidney could benefit greatly from continuous blood flow monitoring.

Materials and Methods: To assess the feasibility of the probe in a renal transplant patient, we used the probe in 15 consecutive transplant recipients.

Results: Only 1 Doppler ultrasound was ordered during the 15 admissions compared with scans that are routinely ordered. There were no complications and all probes were removed easily.

Conclusions: This probe can identify transplanted organs that are threatened owing to flagging or cessation of the blood supply, and allow for immediate intervention. This technique may save precious organs. Further controlled studies are needed to assess the use of the probe in routine clinical practice.

Key words: Renal, Surveillance, Vascular, Artery, Postoperative

Introduction

Historically, ultrasound scanning has been the foremost imaging tool for assessing a transplanted kidney and its associated blood supply postoperatively.^{1,2} Doppler ultrasound measurement of kidney allograft blood flow is a valuable predictor for graft survival and also relates to early graft survival.¹

After a kidney transplant, surveillance of the graft blood supply is crucial. Graft thrombosis is the most common early complication causing preventable kidney graft loss.³ A delay in detecting compromised graft perfusion consequently affects organ survival. Current practice involves Doppler ultrasound to monitor vessel patency and graft perfusion. It is performed repeatedly after kidney and pancreas transplant but has inherent problems. We assessed the feasibility of using the Implantable Cook-Swartz Doppler Flow Probe (Cook Medical Inc., Bloomington, IN, USA) in 15 kidney transplant recipients in place of our routine serial ultrasound scans.

Patients and Methods

The Implantable Doppler Cook-Swartz flow probe 20-MHz crystal (Figure 1) attached to a silicone cuff (Figure 2) was placed in 15 live donor-related kidney transplant patients (10 women, 5 men; age range, 20-67 years). Our postoperative monitoring protocol was as follows:

Day 1: Monitor continuously, noting any change in signal.

Day 2: Monitor once per hour.

Day 3: Monitor every 2 hours.

From the Hammersmith Hospital - Imperial College Kidney and Transplant Institute London, United Kingdom

Address reprint requests to: Prof. Nadey S Hakim, MD, PhD, Surgical Director Transplant Unit, Imperial College Healthcare NHS Trust, Du Cane Road, London W12 0HS, United Kingdom

Phone: +44 785 0503297 Fax: +44 207 4318497 E-mail: nadey@globalnet.co.uk

Experimental and Clinical Transplantation (2011) 2: 118-120




Figure 1. Probe before implantation.

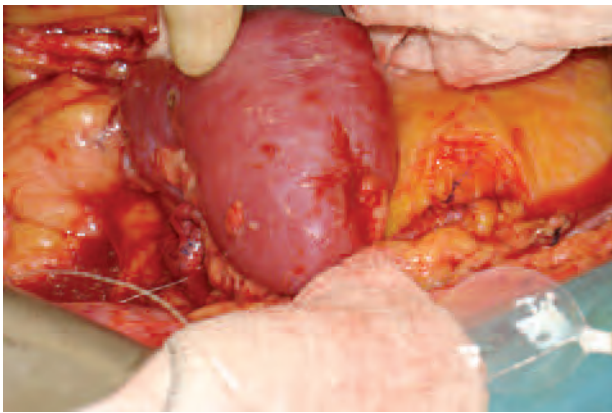


Figure 2. Probe around renal artery.

Day 4: Monitor every 3 hours.

Day 5: Monitor every 4 hours.

Monitoring is discontinued after day 5, and the probe is removed on days 5 through 7. Probe removal requires gentle traction on the wire; 1/10th lb (50 g) pressure disengages the crystal from the cuff that remains permanently in place around the vessel. In our series, 13 of the transplanted kidneys had only 1 artery, with 2 kidneys having 2 arteries. In these 2 patients, a probe was attached to only 1 of the arteries. There were no instances of anastomotic damage caused by probe removal. There have also been no untoward consequences found in the literature or from the manufacturer suggesting any long-term risks of leaving the cuff around the vessel.

Results

All 15 transplants were followed as per protocol. Only a single Doppler ultrasound for each patient was ordered during the 15-day hospital stay

compared with frequent scans routinely ordered. There were no complications, and all probes were straightforwardly removed at 7 days.

Discussion

The following is standard practice in our institution: Immediately after a kidney transplant, a radiologist performs a Doppler ultrasound in the recovery unit. If the scan is satisfactory, another scan is performed 12 to 24 hours later. Any clinical concerns during that interim necessitate additional scans.

As mentioned, ultrasound scanning has been, and still is, the mainstay for monitoring transplants, but there are drawbacks to it. The scans are expensive, frequently involving off hours, and require mobilization of bulky ultrasound machines to the patients' bedside. Radiologists with varying experience perform the scans, and this inconsistent operator dependency can lead to misleading interpretation. Visualizing and quantifying the blood flow to a transplanted kidney by means of ultrasound poses difficulties despite the operator. The transplanted vessels may be deep from the skin surface and obscured by the overlying bowel; made worse in the obese patient and in the presence of postoperative edema. There may be considerable depth to deal with if the kidney is sited intraperitoneally; exploring the vessels in this context is particularly difficult. Vessels to the transplanted kidney can be multiple, and the variability of recipient's external iliac vessel diameter can make discerning which vessels must be imaged difficult for the ultrasonographer. Pressing the transducer against the skin over a recent incision to obtain adequate contact causes considerable discomfort to the patient. There is also a risk of infection as wound dressings are removed to apply the ultrasound transmission gel to the skin. Ultrasound scanning in this fashion has been reported to lead to nosocomial infections.^{4,5} Wound infection is problematic, as transplant patients are immunosuppressed secondary to chronic kidney disease, compounded by immunosuppressants prescribed for graft rejection.

When a presumed thrombosis in the transplanted vessels is flagged as a concern by the radiologist, immediate intervention usually requires revisiting the operating theatre for exploration. Because of issues involved with variable duplex interpretation, exploratory surgery often confirms a healthy

transplanted organ. Repeat surgery is therefore unnecessary and is associated with considerable morbidity. This has been the case in our institution.

An isolated post transplant ultrasound scan may be unhelpful,² and there are issues (some already mentioned) concerned with serial ultrasound scans. Therefore, an additional method of monitoring blood flow to transplants has been sought. A possible alternative or adjunct is the Implantable Cook-Swartz Doppler Flow Probe. The implantable probe allows for easy attachment and safe, continuous monitoring of vascular anastomoses. It has been successfully used to survey the integrity of the blood supply to microvascular tissue transplants, free flaps, and pediatric liver transplants,⁶⁻⁹ but not yet in kidney (or pancreas) transplant. Use of a continuous blood flow monitoring device may help reduce the complications outlined above instead of using serial ultrasound scanning alone. It may help prevent unnecessary repeat exploratory surgery—a chief motivating factor in seeking improved transplant imaging.

The probe potentially saves precious organs. It can monitor continuously or periodically, as required, and can instantly identify diminishing or loss of blood flow and allow the earliest intervention. Other advantages include obviating the need for bulky ultrasound machines at the bedside, decreasing expensive use of radiologic facilities, and could ultimately reduce the number of patients undergoing unnecessary exploratory procedures.

This study illustrates the feasibility of the probe. Further studies with quantitative data and a suitable control group are needed to consider the probe for use in clinical practice.

References

1. Lebkowska U, Malyszko J, Lebkowski W, et al. The predictive value of arterial renal blood flow parameters in renal graft survival. *Transplant Proc.* 2007;39(9):2727-2729.
2. Baxter GM. Ultrasound of renal transplantation. *Clin Radiol.* 2001;56(10):802-818.
3. Matas AJ, Humar A, Gillingham KJ, et al. Five preventable causes of kidney graft loss in the 1990s: a single-center analysis. *Kidney Int.* 2002;62(2):704-714.
4. Weist K, Wendt C, Petersen LR, Versmold H, Rüden H. An outbreak of pyodermas among neonates caused by ultrasound gel contaminated with methicillin-susceptible *Staphylococcus aureus*. *Infect Control Hosp Epidemiol.* 2000;21(12):761-764.
5. Merz E. Transducer hygiene – an underrated topic? [in English and German]. *Ultraschall Med.* 2005;26(1):7-8.
6. Cronin DC 2nd, Schechter L, Lohman RF, et al. Advances in pediatric liver transplantation: continuous monitoring of portal venous and hepatic artery flow with an implantable Doppler probe. *Transplantation.* 2002;74(6):887-890.
7. Smit JM, Whitaker IS, Liss AG, Audolfsson T, Kildal M, Acosta R. Post operative monitoring of microvascular breast reconstructions using the implantable Cook-Swartz doppler system: a study of 145 probes & technical discussion. *J Plast Reconstr Aesthet Surg.* 2009;62(10):1286-1292.
8. Oliver DW, Whitaker IS, Giele H, Critchley P, Cassell O. The Cook-Swartz venous Doppler probe for the post-operative monitoring of free tissue transfers in the United Kingdom: a preliminary report. *Br J Plast Surg.* 2005;58(3):366-370.
9. Kind GM, Buntic RF, Buncke GM, Cooper TM, Siko PP, Buncke HJ Jr. The effect of an implantable Doppler probe on the salvage of microvascular tissue transplants. *Plast Reconstr Surg.* 1998;101(5):1268-1273; discussion 1274-1275.