

A Fast and Safe Living-Donor "Finger-Assisted" Nephrectomy Technique: Results of 225 Cases

Nadey S. Hakim, Vassilios Papalois, Ruben Canelo

Abstract

Renal transplant remains the treatment of choice for end-stage renal disease. It improves both the quality of life and the quantity of life in recipients. We present a living-donor nephrectomy technique that is less invasive than the conventional open flank incision. This technique involves only 1 incision and is smaller than the one used in the laparoscopic technique. We have successfully introduced this new technique at our center. The procedure may be done safely and is applicable in all potential donors regardless of the body mass index of the donor or the size of the surgeon's hands. It provides excellent grafts and has allowed us to expand our living-donor program.

Key words: *Kidney transplant, Technique, Body mass index, BMI, Graft function*

Renal transplant remains the treatment of choice for end-stage renal disease. It improves both the quality of life and the quantity of life in recipients. The number of patients on the United Kingdom transplant waiting list is projected to rise to more than 5000 by 2010 (1). Increasing the donor pool is therefore of utmost importance. A living-related donor offers advantages to the recipient, which include less delay between renal failure and rehabilitation, posttransplant renal function that

occurs immediately, and lower dosages of immunosuppressive drugs. The major disincentive for living donors is pain, scarring, and morbidity associated with large incisions.

We present a living-donor nephrectomy technique that is less invasive than the conventional open flank incision, which is 15 to 20 cm. This technique involves only 1 incision that is smaller than the one used in the laparoscopic technique (which is 7 to 8 cm). We have successfully introduced this technique at our center over an 8-year period; however, the instrumentation used in this technique has only been available over the last 4 or 5 years and therefore, we have restricted our results to the last 36 months.

Materials and Methods

All donors undergo a magnetic resonance angiography (MRA) prior to the nephrectomy (Figure 1). The patient is positioned in the lateral decubitus position with the table maximally flexed (Figure 2). An initial 4.0-cm transverse incision is made anterior to the 11th rib (Figure 3). All muscle layers are cut in the line of the incision, without rib

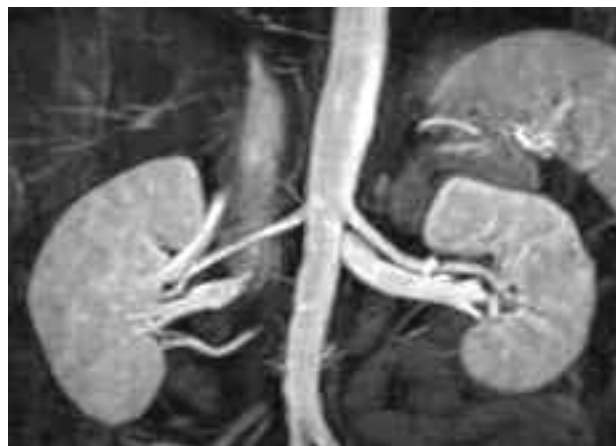

Figure 1. Magnetic resonance angiography of the kidneys.

From The West London Renal and Transplant Centre, Imperial College Healthcare NHS Trust, Hammersmith Hospital

Acknowledgment: The authors are grateful for support from the National Institute for Health Research Biomedical Research Centre funding scheme.

Address reprint requests to: Professor Nadey S. Hakim, KCJSJ, MD PhD FRCS FACS FICS (Hon), First Max Thorek Professor of Surgery, Surgical Director, The West London Renal and Transplant Centre, Imperial College Healthcare NHS Trust, Hammersmith Hospital, Du Cane Road, London W12 0HS

Phone: +447850503297 Fax: +4420743118497 E-mail: nadey@globalnet.co.uk

Experimental and Clinical Transplantation (2008) 4: 245-248

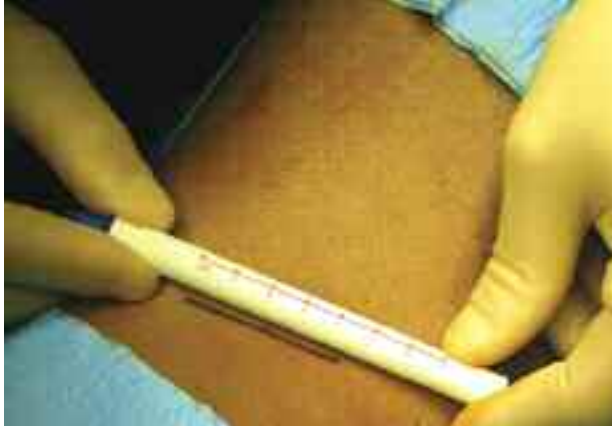

Figure 2. Position and incision. On the operating table, the patient is rolled into the lateral position with the tip of the 11th rib directly overlying the flexed part of the operating table. After the patient is secured, the table is flexed to allow the greatest possible separation between the iliac crest and the lower costal margin.

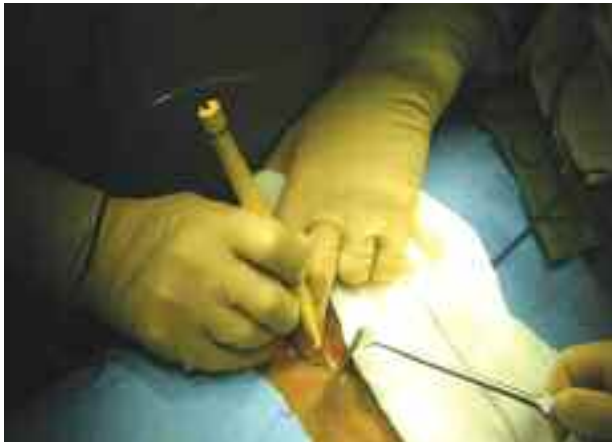

Figure 3. Skin incision. A 3- to 5-cm incision is made along the 11th rib without rib resection.

resection. The kidney is exposed from pole to pole and from its greater curvature to the hilum both anteriorly and posteriorly (Figure 4). The ureter and its attachments are exposed and stapled with an ETS-Flex (Ethicon, Inc, Somerville, NJ, USA) endoscopic articulating linear cutter (Figure 5). The articulating linear cutter applies 3 staple lines proximally and 3 distally and has a flexible and rotating end (Figure 6,7). The ETS-Flex can be used to transect the gonadal vein (Figure 8). After the hilum has been cleaned so that only the renal vein and renal artery remain, these vessels are stapled with the ETS-Flex cutter (Figure 9,10,11). This technique allows enough space for the fingers to dissect the kidney, and therefore, we called it the *finger-assisted technique* as compared with the hand-assisted laparoscopic technique. By the end of the procedure, the size of the incision is the same as when we started (Figure 12).

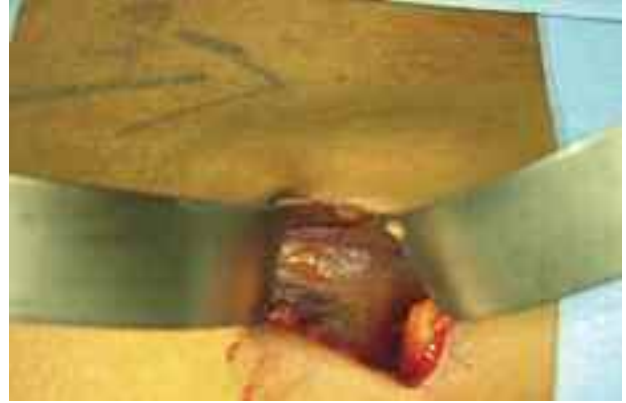

Figure 4. Exposure of the kidney. The kidney is exposed from pole to pole and from its greater curvature to the hilum both anteriorly and posteriorly.

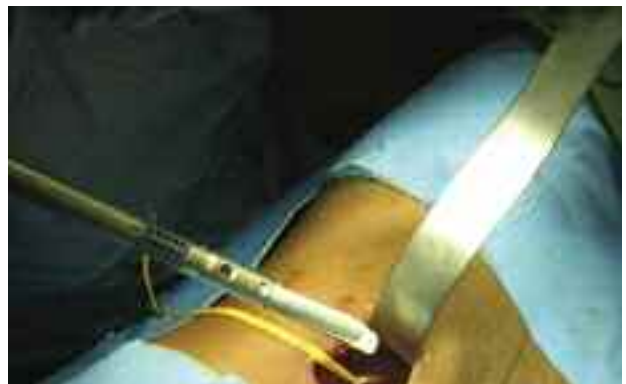

Figure 5. Identification of the ureter. The ureter and its attachments are exposed and stapled with the ETS-Flex endoscopic articulating linear cutter.



Figure 6. Use of the ETS-Flex endoscopic articulating linear cutter. The articulating linear cutter applies 3 staple lines proximally and 3 distally. The cutter has a flexible and rotating end.

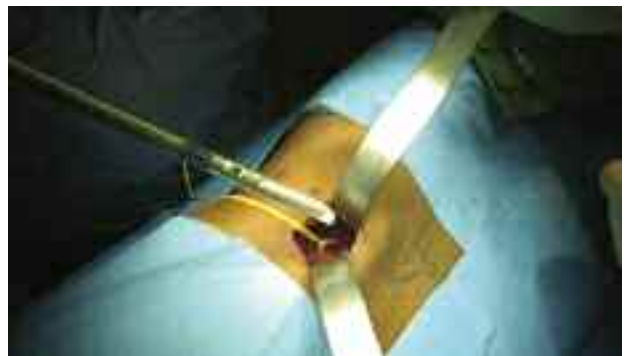

Figure 7. Transection of the ureter.

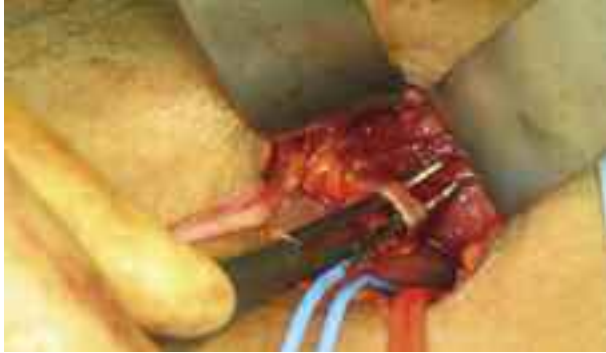

Figure 8. The gonadal vein.

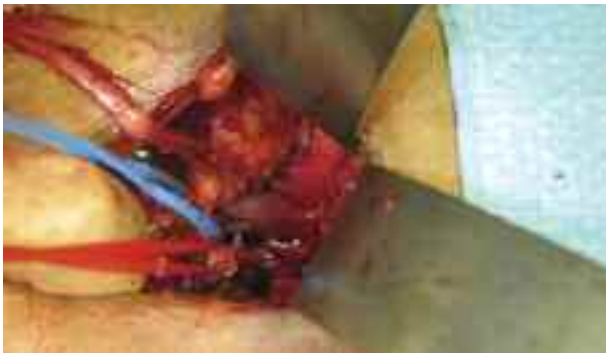

Figure 9. Exposure of the vessels. After the hilum has been cleaned so that only the renal vein and renal artery remain, these vessels are stapled with the ETS-Flex cutter.

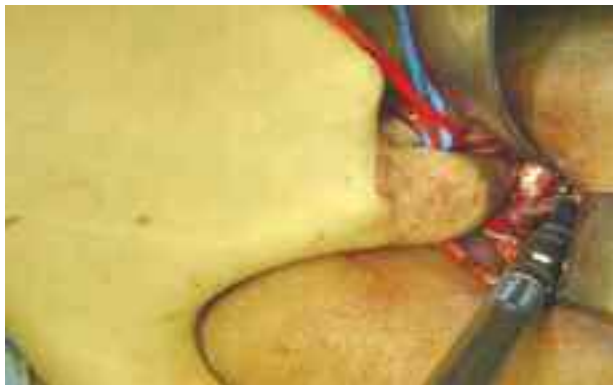


Figure 10. Transection of the renal artery.

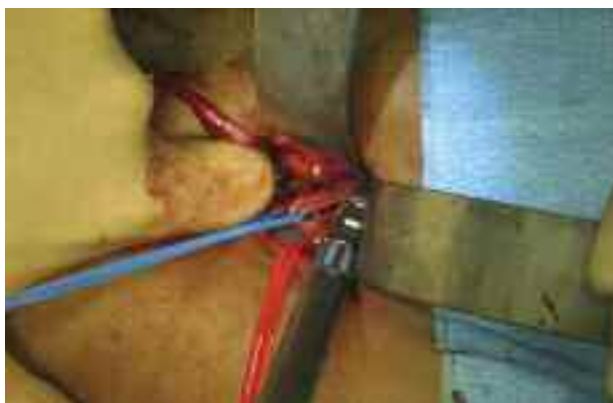

Figure 11. Transection of the renal vein.

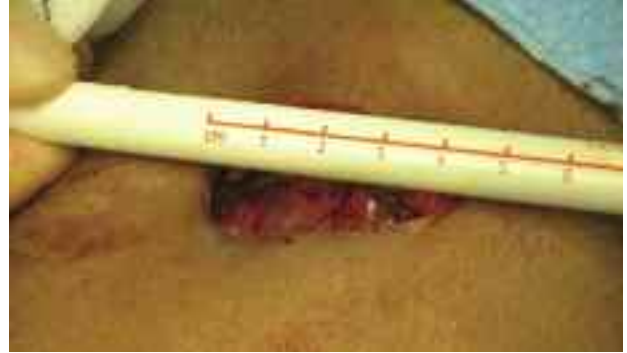

Figure 12. The incision measures 4.5 cm after completion of the nephrectomy.

Data are presented as means \pm standard deviation or median with range where appropriate.

Results

Over a 36-month period between July 2005 and June 2008, 225 patients (104 men, 121 women; mean age, 43.2 ± 11.6 years; median body mass index, 27.0 kg/m^2 ; range, $17.5\text{-}44.0 \text{ kg/m}^2$) underwent a live-donor nephrectomy using the finger-assisted technique, with a median follow-up of 18 months (range, 1-36 months). Most donors underwent a left nephrectomy, while 22 donors (9.8%) underwent a right nephrectomy. The median length of the skin incisions was 6.6 cm (range, 4.0-10.0 cm). Multiple vessels were present in 81 patients (36%). The median time to kidney removal from the donor was 82 minutes (range, 30-180 minutes). The median total operative time was 124 minutes (range, 50-220 minutes). The median estimated blood loss was 115 mL (range, 20-450 mL). The median time of warm ischemia was 4.0 minutes (range, 1.5-10.0 minutes). The median length of hospital stay was 5 days (range, 2-8 days). Postoperative complications included pain and urinary tract infection in 4 patients (1.8%). All donors had excellent cosmetic results and early return to daily activities, and all recipients had primary graft function.

This prospective series has demonstrated that a modified approach to open mini-incision nephrectomy can result in a smaller incision while maintaining safety. Unlike laparoscopic nephrectomy, which is associated with major complications such as pancreatitis, bowel obstruction, pneumonia, adult respiratory distress syndrome, splenic lacerations, pneumothorax, liver lacerations, and diaphragmatic injuries, this technique is not associated with any of

these. We have increased the number of live donors from 5 to 10 persons per year to about 100 per year, which has allowed us to transplant a record number of patients with 97.85% graft survival, serum creatinine level of 126.04 $\mu\text{mol/L}$, and a patient survival rate of 99.38% at 1 year.

Discussion

This procedure can be performed safely and is applicable in all potential donors (regardless of their body mass index) or the size of the hands of the

surgeon. It provides excellent grafts and has allowed us to significantly expand our living-donor program. This prospective series has demonstrated that a modified approach to open mini-incision nephrectomy can result in a smaller incision while maintaining safety. Unlike laparoscopic nephrectomy, which is associated with major complications such as pancreatitis, bowel obstruction, pneumonia, adult respiratory distress syndrome, splenic lacerations, pneumothorax, liver lacerations, and diaphragmatic injuries, this technique is not associated with any of these.