

Severe Tacrolimus Toxicity in Rabbits

Goetz A Giessler,¹ Naomi M Gades,² Patricia F Friedrich,¹ Allen T Bishop¹

Objectives: Tacrolimus is an effective immunosuppressant, safely administered in clinical practice by monitoring blood levels. In experimental transplants, many dosage regimens have been reported, often without such determinations. Anorexia and organ toxicity commonly occur. We report the toxic effects of tacrolimus in rabbits receiving intramuscular injections (1 mg/kg/d) and the subsequent dosage modifications that resulted in improved animal survival without toxic effects.

Materials and Methods: To obtain nontoxic drug concentrations in the blood, 3 dosage regimens were required. Drug concentrations were targeted using therapeutic human values as a guide (range, 5-20 ng/mL). First, a group of 12 Dutch Belted rabbits received vascularized femoral allografts and were treated with intramuscular dosages of tacrolimus (1 mg/kg/d) for 14 days. Subsequently, dosage reductions in 10 more rabbits, to 0.2 mg/kg/d for 14 days, were necessary. Finally, another group of 20 rabbits was treated with 0.08 mg/kg for 3 days, and then every other day thereafter. Weight loss > 30%, cardiopulmonary failure, and/or creatinine levels > 221 μ mol/L were the criteria approved by our local Institutional Animal Care and Use Committee for euthanizing the animals. Treated animals were compared with 20 nonimmunosuppressed controls that underwent the same operation.

Results: At an intramuscular dosage of 1 mg/kg/d,

the mean tacrolimus blood level was 90.7 ng/mL. Ten of the 12 animals in the original group died or required euthanasia. At necropsy, renal failure, cardiac abnormalities, and pulmonary edema were found. The tacrolimus dosage of 0.2 mg/kg/d produced a mean tacrolimus blood level of 17.6 ng/mL; however, 8 of the subsequent 10 rabbits died when given this dosage. Ultimately, the 0.08 mg/kg regimen in 20 rabbits permitted survival of 18 animals with a mean tacrolimus blood level of 6.8 ng/mL. None of 20 nonimmunosuppressed controls died after surgery.

Conclusions: For successful immunosuppression, Dutch-Belted rabbits require intramuscular tacrolimus dosages lower than those required in other rabbit breeds. This has not been reported previously. The 0.08 mg/kg/d dosage combined with intermittent drug level monitoring permits survival without significant complications.

Key words: FK-506, Adverse effect, Adverse event, Immunosuppression, Bone allograft

Previous research from our laboratory on vascularized bone allo- and xenografts in a rat model has demonstrated the effectiveness of tacrolimus in maintaining both short- and long-term survival of the bone tissue [1-4]. In short-term (up to 4 weeks) studies, intermittent administration of tacrolimus has been shown to maintain bone perfusion and viability [1, 5]. Long-term survival for up to 18 weeks in this model is possible when this short-term immunosuppression regimen is combined with host-derived vascular neoangiogenesis from implanted arteriovenous bundles. In a subsequent study, to better evaluate healing and bone biomechanical properties, we used a Dutch-Belted rabbit model and orthotopically transplanted vascularized femur diaphyses. For immunosuppression, we initially used 1 mg/kg/d tacrolimus for 14 days based on dosage regimens previously reported for New Zealand-

¹Department of Orthopedic Surgery, Microvascular Research Laboratory, and the

²Department of Comparative Medicine, Mayo Clinic, Rochester, MN, USA

Acknowledgements: We appreciate the support and dedicated animal care from the veterinary technician staff in the Department of Comparative Medicine at the Mayo Clinic, Rochester, Minnesota, USA. We thank Ronald J. Marler, DVM, PhD, of the Mayo Clinic in Scottsdale, AZ, USA, for evaluating the pathological and histologic specimens.

This study was funded in part by a grant from the Musculoskeletal Transplant Foundation (MTF 2007/1).

Address reprint requests to: Allen T Bishop, MD, Chief Department of Hand Surgery Orthopedic Surgery, Mayo Clinic, 200 First Street SW, Rochester, MN, USA, 55905
Phone: 00 1 507 284 9593 Fax: 00 1 507 284 5075 E-mail: bishop.allen@mayo.edu

White Japanese rabbits and rabbits of breeds not further specified (range, 0.1-1.6 mg/kg) (Table 1) [6-11]. Unacceptably high mortality resulted, necessitating adjustments in the drug dosage. We believe our experience will benefit other researchers using tacrolimus in Dutch-Belted and other rabbit models.

Materials and Methods

Animals

Dutch Belted (recipient) and New-Zealand White (donor) rabbits (*Oryctolagus cuniculus*; Myrtles Rabbitry, Thompson Station, TN, USA) were housed in an animal facility accredited by the Association for Assessment and Accreditation for Laboratory Animal Care, International. Rabbits were acclimated for at least 2 days prior to experimental manipulation to recover from the stress induced by transportation and the change in environment. All animals received water ad libitum and approximately 170 g standard laboratory rabbit chow daily (LabDiet, rabbit diet 5321, PMI Nutrition International, Richmond, IN, USA). Loose hay, apples, bananas, yogurt, and carrots were provided as nutritional supplements and enrichment to encourage the rabbits to eat, especially postoperatively. All procedures were approved by the institutional animal care and use committee, and the rabbits were housed in accordance with the Guide for the Care and Use of Laboratory Animals [12].

Young adult Dutch-Belted rabbits weighing between 2 and 2.5 kg received vascularized femoral allografts harvested from New-Zealand White rabbit donors. This represents an established model with a high histocompatibility barrier [13, 14]. The Dutch-Belted rabbits were initially anesthetized with ketamine (40 mg/kg), xylazine (7 mg/kg), and acepromazine (1 mg/kg), and then, following oral tracheal intubation, spontaneous breathing anesthesia was maintained with isoflurane and 75% oxygen. Intravenous lactated Ringer's solution was administered as needed through a marginal ear vein. A shaved front paw was used to measure intraoperative pulse oximetry. The lower abdominal wall and both hind limbs were clipped and prepared for surgery. Sterile precautions were maintained throughout the procedure.

Transplant

The recipient rabbit's femur was exposed via a medial approach, and a 4-cm segment was resected. An axial fascial flap (which included the ipsilateral superficial inferior epigastric vessel pedicle) was raised from the abdominal wall through an additional 5-cm long paramedian incision. A 4-cm femoral allograft

including the femoral nutrient vessel was transplanted, stabilized to the host femur with two figure-8 wires proximally, two 90° opposed intraosseous wires distally, and an intramedullary Kirschner wire. Next, the fascial flap was pulled through the femoral canal with the prepared pullout suture through a small trough in the proximal femur. The nutrient pedicle of the graft was microsurgically anastomosed in an end-to-end fashion to the recipient's femoral vessels distal to the origin of the deep femoral artery and vein. Preservation of the deep femoral vessels maintains adequate perfusion of the lower extremity [15, 16].

Aftercare

Postoperatively, rabbits wore a collar for 14 days to prevent self-mutilation of the surgical site. They were given intramuscular buprenorphine (0.2 mg/kg) for analgesia for 2 days and 0.1 mL/kg heparin for 3 days. Additionally, subcutaneous trimethoprim and sulfadiazine (0.2 mL) was given for 3 weeks for infection prophylaxis. Tacrolimus was initially administered to 12 animals at a dosage of 1 mg/kg/d intramuscularly for 14 days. The drug (prepared from a freeze-dried powder) was reconstituted with 0.9% sodium chloride solution in 10-mL vials. Later dosages (see below) were adapted to 0.2 mg/kg/d for 14 days (10 animals), and ultimately to 0.08 mg/kg/d for 3 days and then every other day until the 14th day after surgery (20 animals). Blood specimens for drug level monitoring were taken from the ear artery of the rabbits. In 20 more rabbits, the same procedure was performed with no postoperative immunosuppressive medication (nonimmunosuppressed control group).

Results

Mean blood loss (8-10 mL) during surgery and mean operative time (3 hours) were the same in all rabbit groups. Of 12 rabbits treated with tacrolimus at a dosage of 1 mg/kg/d intramuscularly for 14 days, 4 rabbits died on postoperative days 1, 2, 14, and 17, and according to the clinical endpoints, 4 rabbits had to be euthanized on postoperative days 7, 9, 13, and 15. Two additional rabbits died owing to convulsions on postoperative days 5 and 16. Drug monitoring in this group demonstrated high blood drug levels (mean, 90.7 ng/mL; range, 47.1-146.5 ng/mL) (Figure 1). Safe and therapeutic human tacrolimus levels are reported as being between 5 and 20 ng/mL. No such information is available in animals. Necropsy revealed serous effusions in the peritoneal and thoracic cavities, hemorrhagic and edematous

lungs, and pale kidneys in all of the animals in this first experimental group; in 4 animals, the liver was found to have a mottled aspect (Figure 2).

In all specimens, the histologic findings were (a) moderate to severe myocardial degeneration with variable but considerable inflammation (Figure 3); (b) hemorrhagic and diffusely congested, edematous lungs; (c) diffuse, severe cortical necrosis of the kidneys (Figure 4); and (d) centrolobular, multifocal severe hepatocyte necrosis. The findings suggest that the cause of death in these animals was severe myocarditis leading to heart failure and pulmonary edema. Additionally, the rabbits developed anorexia in the first week after surgery. Renal failure was reflected in elevated blood urea nitrogen (up to 37 mmol/L; normal range, 3.2-9.3 mmol/L) and creatinine levels (up to 283 μ mol/L; normal range, 26.5-115 μ mol/L). All of the above are consistent with the toxic effects of tacrolimus [6, 10, 17, 18]. We did not see these problems in the 20 control animals.

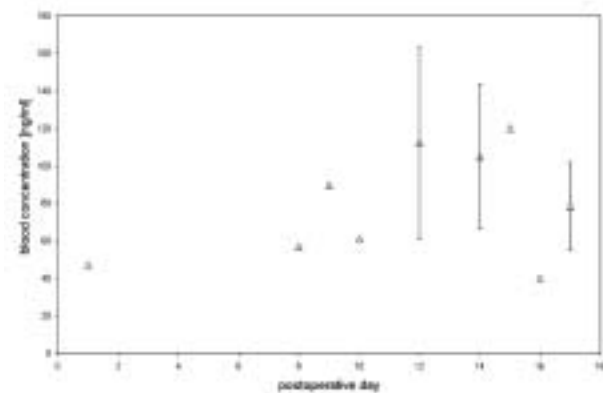


Figure 1. Peak trough levels after daily IM administration of tacrolimus (1 mg/kg). Blood specimens could not be obtained in every rabbit every day because of technical reasons like clotting of the ear artery. Data are given as single and mean concentrations \pm standard deviation.

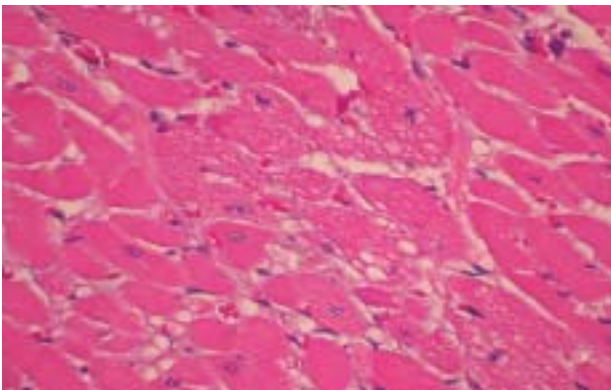


Figure 3. Rabbit myocardium showing multifocal myofiber degeneration and necrosis, interfiber edema, and moderate inflammation (magnification \times 40).

Knowing the blood levels at the highest dosage, we estimated that a reduction in the dosage to 0.2 mg/kg/d for 14 days would lower drug levels in the blood to concentrations comparable with those in the human therapeutic range (5-20 ng/mL). At this dosage, we continued to see problems in 8 of 10 rabbits, which resulted in 4 spontaneous postoperative deaths (on postoperative days 4, 6, 14, and 15) and 4 euthanasias on postoperative days 0, 10, 13, and 18. The blood levels decreased to a mean of 17.6 ng/mL (range, 11.9-24.6 ng/mL) between days 4 and 14 (Figure 5), and the histopathological changes became less severe, with the kidneys showing only slight tubular necrosis. Again, tacrolimus-induced heart failure with pulmonary edema was determined to be the cause of death. Careful review of the operative protocols identified no other treatment differences between the groups with 1 mg/kg and 0.2 mg/kg/d dosage.

Finally, in 20 rabbits, a tacrolimus dosage of 0.08

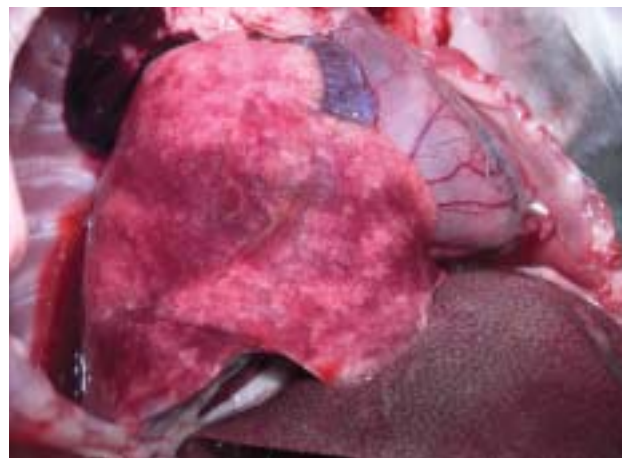


Figure 2. Typical finding during necropsy: serous effusions in the peritoneal and thoracic cavities, hemorrhagic and edematous lungs, and pale kidneys. The liver demonstrated centrolobular necrosis with a mottled appearance.

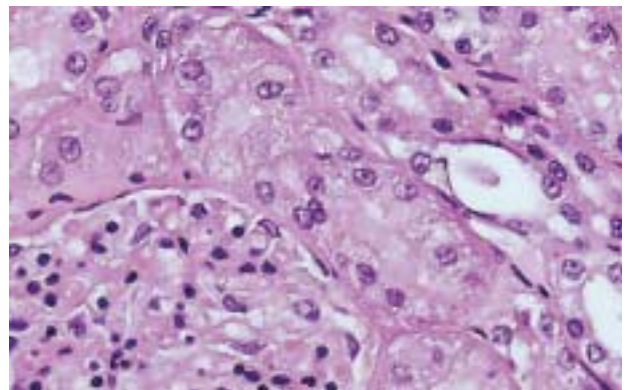


Figure 4. Rabbit kidney showing diffuse, severe cortical nephropathy, tubular epithelial degeneration/necrosis, tubular dilatation with intraluminal eosinophilic material, and eosinophilic granular material in Bowman's capsule (magnification \times 40).

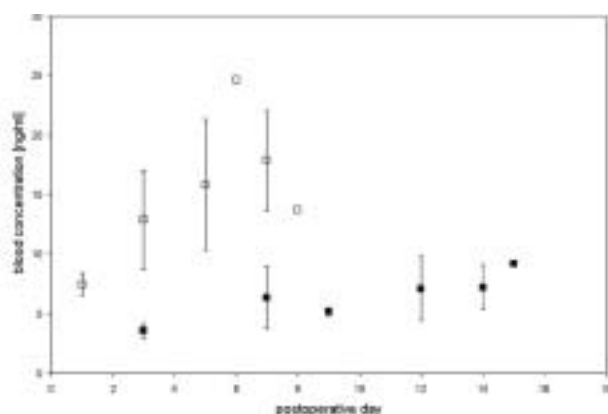


Figure 5. Tacrolimus peak trough levels after daily IM administration of 0.2 mL/kg/d (empty squares) and 0.08 mL/kg (3 days daily and then every other day; solid squares). (See also the legend for Figure 1 for single and mean data points.)

mg/kg/d was given intramuscularly in a loading phase for 3 consecutive days and then every other day until the 14th day after surgery. Only 1 rabbit had to be euthanized on day 14 owing to hypothermia and excessive weight loss. Another animal died of a seizure on the 18th postoperative day. The mean drug level after the loading phase was 6.8 ng/mL (range, 4.5-11 ng/mL) until the 14th postoperative day, when drug was discontinued according to the study protocol. In all tacrolimus-treated rabbits, postoperative anorexia was evident by reduced food intake and low fecal output. All of the survivors eventually recovered their initial weight, as did the controls, and survived for 16 weeks until termination of the study. All of the allotransplants healed and showed new periosteum formation originating from the graft, demonstrating viability and presumably adequate immunosuppression.

Discussion

The toxicity of tacrolimus has been demonstrated in several experimental animal species [10, 19-22]. It has been described in various rabbits breeds (except Dutch-Belted), with intravenous dosages as low as 0.2 mg/kg/d [6]; in dogs, at intravenous dosages of 0.3 mg/kg/d [22] and oral dosages of 1.0 mg/kg/d, with serum levels as low as 0.1 ng/mL [19, 21]; and in rats, at dosages of 1 mg/kg/wk intramuscularly and intravenously [18] and 4 mg/kg/d intramuscularly [17]. However, blood levels of tacrolimus after intramuscular injections in living rabbits (ie, not during isolated organ perfusions [7]) have not yet been reported.

Shirbacheh and associates provided a detailed study about the pharmacokinetics and tissue deposition rates of tacrolimus after intra-arterial

administration, but the study did not include blood drug levels [23]. In the current study, intramuscular injection of tacrolimus at dosages higher than 0.08 mg/kg/d for 3 days and then qod after that resulted in deleterious effects within a few days. The authors of another study that used comparable dosages, length, and route of administration reported similar survival rates and no deleterious effects [9]. Unfortunately, that study provided no data about tacrolimus with regard to animal deaths, drug levels, or toxic effects [9]. The renal failure, convulsions, and cardiac hypertrophy that ultimately proved fatal to many of our rabbits mirror the clinical findings in humans and rabbits with tacrolimus overdose [6, 10, 24]. The gastrointestinal signs in our animals resemble those found in dogs [21, 22]. The non-immunosuppressed rabbits in our study showed no signs of organ failure, and none of the preceding pathological gross findings were present at 16 weeks.

Table 1 illustrates a variety of tacrolimus dosage regimens that have been used in experimental surgery. Relatively little data on rabbits exist. None of the studies in Table 1 used Dutch-Belted rabbits. Owing to possible different drug sensitivities among various species, we selected our initial dosage from the range of available data [6, 9-11]. Also, only short-term immunosuppression was necessary according to our study protocol, and the cumulative dosages and exposure times were comparatively low. As we treated only Dutch-Belted rabbits with tacrolimus, we cannot prove a similar susceptibility in other rabbit breeds, but our results certainly support cautious use of this drug in rabbits in general.

The pharmacokinetics of tacrolimus in rabbits is similar to that in humans, with a high percentage of intraerythrocyte binding and variable oral uptake [7, 8, 25]. Our data indicate variable tacrolimus concentrations after intramuscular administration as well (Figure 1). This variability, however, is acceptable at the nontoxic dosage of 0.08 mg/kg/d (Figure 5). The intramuscular route in rabbits is reliable and certainly is more convenient than intravenous injections given over several days, as the ear veins are easily subject to thromboses after repeated injections.

Extensive surgical procedures in rabbits can be problematic owing to difficulties in maintaining proper intravenous or inhalatory anesthesia levels and managing fluid and electrolyte levels, owing to rabbits' low cardiac reserve, their low tolerance to opioids, and the difficulty in intraoperative monitoring. Their typical postoperative anorexia can complicate their recovery [11]. In our work using rabbit autografts, at 16 weeks after surgery, all of the rabbits weighed 102% of their initial weight; this also

Table 1. Overview of several studies with systemic administration of tacrolimus in different species. The data in rabbits are scarce, whereas there is a broad range of drug dosages in rats.

Species	Author	Procedure	Dosage	Route of administration	Time period	Remarks
Rabbit	Ikebe [9]	bone xenograft	1.6 mg/kg/d	IM	10 d	survival 16 wk
Rabbit	Nomoto [6]	no transplant	0.2 mg/kg/d	IV	28 d	left ventricular dilation, myocarditis after 28 d, not after 10 d
Rabbit	Piekoszewski [7, 8]	no transplant	0.5 mg/kg	IV	single dose	about 30 ng/mL after 24 h
Rabbit	Minamino [10]	no transplant	0.1-0.4 mg/kg/d	IV	4 wk	
Rabbit	Hisamatsu [11]	trachea allograft	2.5 mg	local gel	single dose	peak at 3 d (about 17 ng/mL), not detectable after 21 d
Rat	Ochiai [26]	heart	0.1 mg/kg/d 0.32 mg/kg/d 1 mg/kg/d	IM IM PO	10 d 4-10 d 10 d	
Rat	Pelzer [1]	bone allograft	1 mg/kg/d	IM	14 d	survival 18 wk
Rat	Akar [18]	no transplant	1 mg/kg/d	IM		10 ng/mL after 3 mo
Rat	Gohda [27]	hind limb	5 mg/kg	IM	single dose	survival 14 d
Rat	Nakatani [17]	no transplant	4 mg/kg/d	IM	14 d	after 14 d: trough 18-28 ng/mL
Rat	Akst [28]	larynx	1.2 mg/kg/d	IM	5 d	survival 100 d
Rat	Inoue [29]	none	1 mg/kg/d	PO	28 d	
Rat	Fukunaga [30]	bone xenograft	3 mg/kg/d	IM	14 d	survival 8 wk
Dog	Venkataramanan [31]	no transplant	0.49 mg/kg	IM	single dose	peak about 1 ng/mL
Dog	Wang [22]	kidney	0.3-0.6 mg/kg/d	PO	24 d	trough levels < 10 ng/mL despite massive adverse effects
Minipig	Oike [32]	liver	0.1-0.4 mg/kg bid 0.05 mg/kg bid	IM IM	12 d	adjusted daily to trough levels of 7-20 ng/mL

IM, intramuscular; IV, intravenous; PO, by mouth; d, day; wk, week

applied to the nonimmunosuppressed rabbits (controls) receiving an allograft with the same procedure. In both groups, operative time and blood loss were similar.

The results of our data indicate 2 things. First, compared with other laboratory animals, rabbits are exceptionally sensitive to tacrolimus and require a substantially lower dosage. Second, blood level determination is tedious but provides good information about the concentration in that species. Based on animal and graft survival rates, we consider tacrolimus levels of 5 to 10 ng/mL in whole blood to be safe and effective. Of course, the actual effectiveness at this dosage can only be confirmed by investigating the reduction of T-cell activation. We will do this in a future study. Although future studies should involve larger populations with detailed blood chemistry workups and close monitoring of blood levels of tacrolimus for periods longer than 3 weeks, our current findings are important for others

performing experimental transplant studies in a rabbit model.

References

1. Pelzer M, Larsen M, Chung YG, Ohno T, Platt JL, Friedrich PF, Bishop AT. Short-term immunosuppression and surgical neoangiogenesis with host vessels maintains long-term viability of vascularized bone allografts. *J Orthop Res* 2006; 25: 370-377
2. Suzuki O, Bishop AT, Sunagawa T, Katsube K, Friedrich PF. VEGF-promoted surgical angiogenesis in necrotic bone. *Microsurgery* 2004; 24: 85-91
3. Muramatsu K, Kurokawa Y, Kuriyama R, Taguchi T, Bishop AT. Gradual graft-cell repopulation with recipient cells following vascularized bone and limb allotransplantation. *Microsurgery* 2005; 25: 599-605
4. Muramatsu K, Bishop AT, Sunagawa T, Valenzuela RG. Fate of donor cells in vascularized bone grafts: identification of systemic chimerism by the polymerase chain reaction. *Plast Reconstr Surg* 2003; 111: 763-772; discussion 773-764
5. Bishop AT, Pelzer M. Vascularized bone allotransplantation: current state and implications for future reconstructive surgery. *Orthop Clin North Am* 2007; 38: 109-122, vii
6. Nomoto S, Fujiwara H, Ban T, Ohara K. Cardiotoxicity of long-term intravenous administration of FK506 in rabbits: dose relationship and recovery after discontinuance. *Transplant Proc* 1994; 26: 855-857

7. Piekoszewski W, Chow FS, Jusko WJ. Disposition of tacrolimus (FK 506) in rabbits. Role of red blood cell binding in hepatic clearance. *Drug Metab Dispos* 1993; 21: 690-698.
8. Piekoszewski W, Chow FS, Jusko WJ. Pharmacokinetic and pharmacodynamic effects of coadministration of methylprednisolone and tacrolimus in rabbits. *J Pharmacol Exp Ther* 1994; 269: 103-109
9. Ikebe S, Masumi S, Yano H, Fukunaga T, Shimizu K, Shin S. Immunosuppressive effect of tacrolimus (FK-506). Bone xenografts in rabbits. *Acta Orthop Scand* 1996; 67: 389-392
10. Minamino T, Kitakaze M, Ueda Y, Asanuma H, Papst PJ, Kuzuya T, et al. Chronic treatment with FK506 increases p70 S6 kinase activity associated with reduced nitric oxide synthase activity in rabbit hearts. *Cardiovasc Drugs Ther* 2000; 14: 329-336
11. Hisamatsu C, Maeda K, Tanaka H, Okita Y. Transplantation of the cryopreserved tracheal allograft in growing rabbits: effect of immunosuppressant. *Pediatr Surg Int* 2006; 22: 881-885
12. Guide for the care and use of laboratory animals. 6th ed. Washington, DC: National Academy Press, 1996
13. Kniha H, Randzio J, Gold ME, Fudem GM, Cruz HG, Park HH, Furnas DW. Growth of forelimb allografts in young rabbits immunosuppressed with cyclosporine. *Ann Plast Surg* 1989; 22: 135-141
14. Randzio J, Kniha H, Gold ME, Chang TT, Su LD, Park HH, et al. Growth of vascularized composite mandibular allografts in young rabbits. *Ann Plast Surg* 1991; 26: 140-148
15. Morrison WA, Dvir E, Doi K, Hurley JV, Hickey MJ, O'Brien BM. Prefabrication of thin transferable axial-pattern skin flaps: an experimental study in rabbits. *Br J Plast Surg* 1990; 43: 645-654
16. Hoang NT, Kloeppel M, Staudenmaier R, Werner J, Biemer E. Prefabrication of large fasciocutaneous flaps using an isolated arterialized vein as implanted vascular pedicle. *Br J Plast Surg* 2005; 58: 632-639
17. Nakatani T, Uchida J, Iwai T, Matsumura K, Naganuma T, Kuratsukuri K, Sugimura K. Renin mRNA expression and renal dysfunction in tacrolimus-induced acute nephrotoxicity. *Int J Mol Med* 2003; 11: 75-78
18. Akar Y, Yucel G, Durukan A, Yucel I, Arici G. Systemic toxicity of tacrolimus given by various routes and the response to dose reduction. *Clin Experiment Ophthalmol* 2005; 33: 53-59
19. Ochiai T, Gunji Y, Sakamoto K, Suzuki T, Isegawa N, Asano T, Isono K. Optimal serum trough levels of FK506 in renal allotransplantation of the beagle dog. *Transplantation* 1989; 48: 189-193
20. Ochiai T, Nagata M, Nakajima K, Suzuki T, Sakamoto K, Enomoto K, et al. Studies of the effects of FK506 on renal allografting in the beagle dog. *Transplantation* 1987; 44: 729-733
21. Morimoto T, Yamada F, Kobayashi T, Iwasaki K, Sunada M, Sakamoto J, et al. Blood levels of FK506 after intramuscular and intravenous administration in dogs. *Transplant Proc* 1989; 21: 1059-1063
22. Wang X, Sun H, Chen G, Liu W, Wise Y, Yung C, et al. Immunosuppression with a combination of pg490-88 and a subtherapeutic dose of FK506 in a canine renal allograft model. *Transplantation* 2005; 79: 1537-1544
23. Shirbacheh MV, Jones JW, Harralson TA, Edelstein J, Tecimer T, Breidenbach WC, et al. Pharmacokinetics of intra-arterial delivery of tacrolimus to vascularly isolated rabbit forelimb. *J Pharmacol Exp Ther* 1999; 289: 1196-1201
24. McMaster P, Mirza DF, Ismail T, Vennarecci G, Patapis P, Mayer AD. Therapeutic drug monitoring of tacrolimus in clinical transplantation. *Ther Drug Monit* 1995; 17: 602-605
25. Chow FS, Piekoszewski W, Jusko WJ. Effect of hematocrit and albumin concentration on hepatic clearance of tacrolimus (FK506) during rabbit liver perfusion. *Drug Metab Dispos* 1997; 25: 610-616
26. Ochiai T, Nakajima K, Nagata M, Suzuki T, Asano T, Uematsu T, et al. Effect of a new immunosuppressive agent, FK 506, on heterotopic cardiac allotransplantation in the rat. *Transplant Proc* 1987; 19: 1284-1286
27. Gohda T, Iwasaki N, Yoshioka C, Minami A. Effect of single-dose administration of FK-506 on allogeneic limb transplantation in rats: is there an optimal timing of its administration? *Plast Reconstr Surg* 2003; 111: 1653-1658
28. Akst LM, Siemionow M, Dan O, Lzycki D, Strome M. Induction of tolerance in a rat model of laryngeal transplantation. *Transplantation* 2003; 76: 1763-1770
29. Inoue T, Kawamura I, Matsuo M, Aketa M, Mabuchi M, Seki J, Goto T. Lesser reduction in bone mineral density by the immunosuppressant, FK506, compared with cyclosporine in rats. *Transplantation* 2000; 70: 774-779
30. Fukunaga T, Masumi S, Yano H, Ikebe S, Shimizu K. Osteogenesis in xenogeneic bone transplantation, using an immunosuppressant. Rabbit-rat experiments. *Acta Orthop Scand* 1995; 66: 557-560
31. Venkataramanan R, Warty VS, Zemaitis MA, Sanghvi AT, Burckart GJ, Seltman H, et al. Biopharmaceutical aspects of FK-506. *Transplant Proc* 1987; 19: 30-35
32. Oike F, Talpe S, Otsuka M, Dehoux JP, Lerut J, Otte JB, Gianello P. A 12-day course of FK506 allows long-term acceptance of semi-identical liver allograft in inbred miniature swine. *Transplantation* 2000; 69: 2304-2314