

Vertigo After Renal Transplantation: A Sign of Paucisymptomatic Cryptococcal Meningitis

Marion Mehrenberger,¹ Nassim Kamar,¹ Jean-Sébastien Borde,¹ Marie-Josée Estève-Fraysse,² Alain Viguiier,³ Paulette Recco,⁴ Dominique Durand,¹ Lionel Rostaing¹

We report what is to our knowledge the first case of severe isolated vertigo that developed after renal transplantation and was a manifestation of cryptococcal meningitis. Treatment with antifungal therapy resulted in the complete resolution of vertiginous symptoms. Immunosuppressed patients with an opportunistic infection of the central nervous system can present with extremely tenuous features of infection and atypical neurologic signs.

Key words: *Antigen agglutination test, Cryptococcal meningitis, Cryptococcosis, Renal transplantation, Vertigo, Vestibular syndrome*

After *Candida* and *Aspergillus*, *Cryptococcus neoformans* is the most common invasive fungus in organ transplant recipients [1]. It is the pathogen most frequently implicated in infections of the central nervous system (CNS) during the late posttransplantation period and is often the cause of subacute meningoencephalitis. Atypical manifestations and subtle systemic signs of *C neoformans* infection in immunocompromised patients can delay diagnosis, thereby increasing mortality. We report a patient who presented with subacute vertigo but without fever or meningeal signs and who was ultimately diagnosed as having cryptococcal meningitis that developed 32 months after renal transplantation. To our knowledge, this is the first description of cryptococcal meningitis that was manifested as a mixed vestibular syndrome after renal transplantation.

Case Report

A 62-year-old woman was admitted to our hospital with severe rotating vertigo that had developed over a few days. Three years earlier, she had received a cadaveric kidney transplant for a nephropathic disorder of unknown origin. After undergoing induction therapy that consisted of antithymocyte globulins, she was treated with dual immunosuppressive therapy consisting of mycophenolate mofetil and steroids. She then experienced 2 successive steroid-resistant acute rejections. The first of those episodes, which occurred during the third month after transplantation, was treated with 8 days of antithymocyte globulins and the introduction of tacrolimus therapy, and the second episode, which developed during the ninth month after transplantation, was treated with 10 days of anti-CD3 monoclonal antibodies (OKT3). After that time, the patient's renal function remained impaired; ie, a serum creatinine level of 225 $\mu\text{mol/L}$. De novo diabetes had also developed, and she had experienced several infections (thoracic zona in the early posttransplantation period, severe candidal esophagitis, and ulcerohemorrhagic colitis caused by *Escherichia coli* after OKT3 therapy). In addition, she presented with chronic lymphopenia (about 216/ mm^3 to 720/ mm^3). Twenty-four months after transplantation, the patient's immunosuppressive regimen was changed to azathioprine and steroids.

At the time of admission; ie, 32 months after renal transplantation, this patient reported having a severe gyratory sensation that prevented her from walking. Her vertigo was associated with moderate but diffuse headache and nausea but with no auditory signs. Physical examination revealed right-sided spontaneous nystagmus in the absence of ocular fixation. Severe ataxia obviated the patient's undergoing classic neurologic testing. She exhibited no meningeal signs, no fever, and no biological markers of inflammation (white blood cell count, 5700/ mm^3 with 82% polymorphonuclear cells; C-reactive protein level, < 7

Department of¹Nephrology, Dialysis, and Transplantation, CHU Rangueil, Toulouse Cedex 9, France; the²Department of Otorhinolaryngology, CHU Purpan, Toulouse Cedex, France; and the Departments of³Neurology and⁴Parasitology, CHU Rangueil, Toulouse Cedex 9, France
Address reprint requests to: Lionel Rostaing, MD, Department of Nephrology, Dialysis, and Transplantation, CHU Rangueil, 1 avenue Jean Poulhès, TSA 50032, 31059 Toulouse Cedex 9 - France

Phone: 00 33 5 61 32 25 84 Fax: 00 33 5 61 32 28 64 E-mail: rostaing.l@chu-toulouse.fr

Experimental and Clinical Transplantation (2006) 2: 525-527

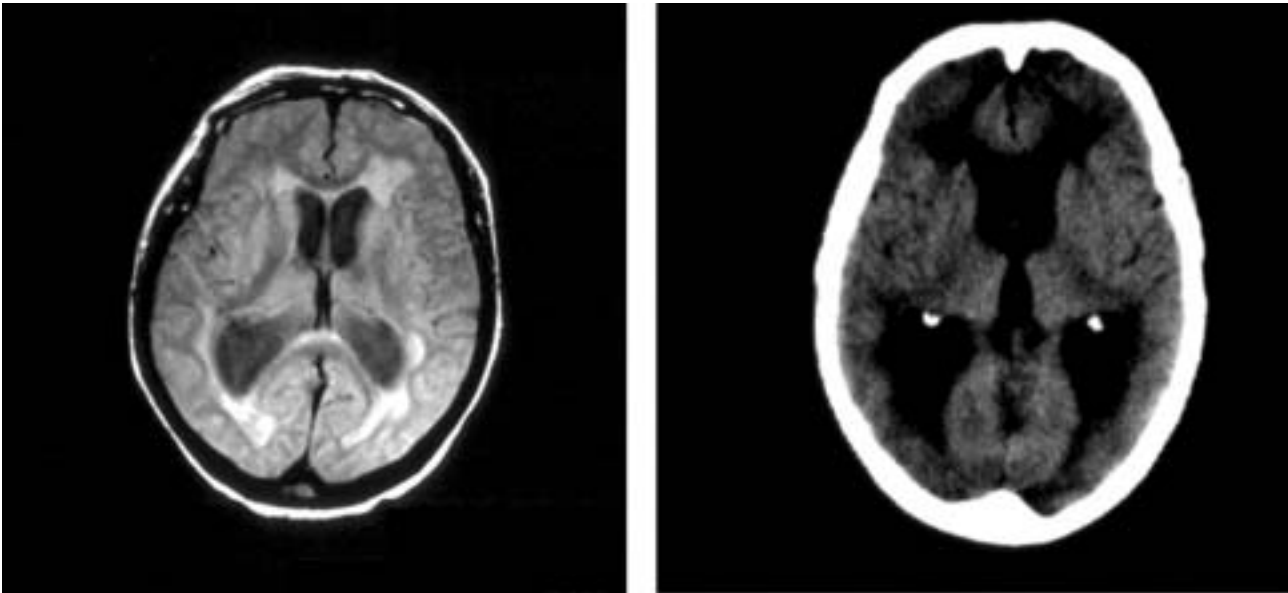


Figure 1. A computed tomographic scan (left) and magnetic resonance imaging (right) without contrast injection reveal severe isolated quadriventricular hydrocephalus 32 months after renal transplantation.

mg/L). An elevated blood pressure value of 180/95 mm Hg in a patient who usually exhibited a rather low blood pressure level suggested intracerebral hypertension.

The results of otorhinolaryngologic investigations indicated a mixed vestibular syndrome. Cerebral imaging with a computed tomography (CT) scan and magnetic resonance imaging (MRI) (Figure 1) showed active severe and communicating quadriventricular hydrocephalus. There was no sign of meningoencephalitis or vestibular neuritis. The results of lumbar puncture indicated normal opening pressure, a white blood cell count of $230/\text{mm}^3$ (76% lymphocytic cells), an elevated protein level of 3.35 g/L, a decreased glucose level of 1.9 mmol/L, and a plasma glucose level of 6.9 mmol/L. The results of a systematic cerebrospinal fluid (CSF) and blood cryptococcal antigen search were positive (titer 1:4) with negative cultures.

The patient was treated with a combination therapy of intravenous amphotericin B (1 mg/kg/d for 15 days; then 0.5 mg/kg/d) and oral flucytosine (30 mg/kg/d for 15 days; then 20 mg/kg/d for 15 additional days). Immunosuppressive treatment was discontinued except for a low dose of prednisone. After 1 month of treatment, the results of a second lumbar puncture (the values of which were within normal limits) and a blood sample analysis were negative for cryptococcal antigens, as were results of retesting after 6 weeks of treatment. Because of the discontinuation of immunosuppressive therapy and the onset of renal toxicity caused by treatment with amphotericin B, chronic rejection occurred, and hemodialysis was resumed. However, at the 2-year

follow-up examination, the patient was found to have completely recovered from her episode of cryptococcal meningitis.

Discussion

C neoformans is a ubiquitous, capsulated, opportunistic yeast that thrives in bird feces. Pulmonary primo-infection after inhalation often produces no symptoms. In immunocompromised hosts, hematogenous spread of this organism usually affects the CNS and causes subacute meningoencephalitis characterized by the typical triad of fever, headache, and changes in mental status. Other signs of infection with *C neoformans* include meningismus, nausea and/or vomiting, and neurologic abnormalities such as cranial nerve deficits, visual disorders, or seizures. Rarely, hydrocephalus resulting from basilar meningitis or a fungal granuloma (ie, cryptococcoma) hinders CSF circulation. Ten percent of patients with *C neoformans* are asymptomatic [1, 2, 3].

The presentation of mixed vestibular syndrome exhibited by our patient is uncommon, but her case highlights the characteristics of CNS infections in organ-transplant recipients, who often fail to demonstrate the typical manifestations and systemic signs of such infection [4, 5]. Because the results of cerebral imaging are often nonspecific or are within normal limits in patients with cryptococcosis, lumbar puncture (which clearly indicates lymphocytic CSF, hypoglycorrhachia, and elevated protein levels) remains essential for diagnosis. Direct examination with India ink has poor sensitivity. Negative blood or CSF

culture results, which occur in up to 50% of patients, should not rule out a diagnosis of *C neoformans* infection. The use of agglutination on latex particles for the detection of cryptococcal polysaccharide capsular antigen is highly sensitive, and those results are positive for *C neoformans* infection in 66% of blood samples and in 95% of CSF samples. False-positive results are rare, owing to the presence of the rheumatoid factor. In our patient, the results of the cryptococcal antigen search were positive in both blood and CSF, although the titer (1:4) was very low.

C neoformans infection develops in patients who lack cell immunity, especially those with the acquired immunodeficiency syndrome, a malignancy, or sarcoidosis; those who have undergone prolonged steroid therapy; and transplant recipients. In renal transplant recipients, *C neoformans* accounts for 4% of all fungal infections, occurs with an incidence ranging from 0.8% to 5.8%, and often develops several years after transplantation [3]. Our patient experienced opportunistic infections from pathogens including *Candida* and the varicella zoster virus and had typical risk factors for cryptococcal infection: She was greatly immunocompromised as a result of treatment with steroids and successive antirejection regimens; she was diagnosed as having lymphopenia and de novo diabetes mellitus; and she exhibited chronic graft dysfunction (an independent factor for cryptococcal infection, probably because of the net state of immunosuppression in a uremic context [1]).

Cryptococcal meningitis must be treated urgently because of its high rate of neurologic sequela and the 50% mortality rate in organ transplant recipients with that infection [6]. Standard therapy consists of intravenous amphotericin B 0.7 to 1 mg/kg/d and oral flucytosine 75 to 200 mg/kg/d; however, the dosage must be adjusted in accordance with the serum level of each drug for 6 weeks [7]. Because of its effectiveness in preventing the recurrence and dissemination of cryptococcal meningitis in patients with the human immunodeficiency virus, oral therapy with fluconazole 200 mg/d is generally added to the regimen of those patients for 6 to 12 months [8]. Intrathecal therapy with amphotericin B is rarely used because of the high rate of treatment-related complications (eg, arachnoiditis). Hydrocephalus is sometimes treated

with ventriculoperitoneal shunting, which confers a high risk of obstruction if performed too early [9]. A reduction in or discontinuation of the dosage of prednisone and other immunosuppressive agents should be attempted.

Conclusions

Cryptococcal meningitis is a life-threatening complication in immunocompromised patients. Heightened awareness of the medical status of renal transplant recipients is essential because the clinical features of disease can be extremely tenuous in such patients, as our case illustrates. Classic evaluations for neurologic symptoms, such as cerebral imaging, may be poorly sensitive. The final diagnosis often depends on the results of antigen agglutination tests of the CSF, which should be performed in renal transplant recipients with an unexplained neurologic disorder, especially when subacute symptoms are noted or resistance to initial therapy occurs.

References

1. Vilchez RA, Fung J, Kusne S. Cryptococcosis in organ transplant recipients: an overview. *Am J Transplant* 2002; 2: 575-580
2. Husain S, Wagener MM, Singh S. *Cryptococcus neoformans* infection in organ transplant recipients: variables influencing clinical characteristics and outcome. *Emerg Infect Dis* 2001; 7: 375-381: 1898
4. Cohen J. Infectious complications after renal transplantation. In: Morris PJ, ed. *Kidney Transplantation Principles and Practice* 14th ed. Philadelphia, WB Saunders; 2001, p 468
5. Singh N, Husain S. Infections of the central nervous system in transplant recipients. *Transplant Infect Dis* 2000; 2: 101-111
6. Wu G, Vilchez RA, Eidelman B, Fung J, Kormos R, Kusne S. Cryptococcal meningitis: an analysis among 5,521 consecutive organ transplant recipients. *Transpl Infect Dis* 2002; 4: 183-188
7. Dismukes WE, Cloud G, Gallis HA, Kerkering TM, Medoff G, Craven PC, et al. Treatment of cryptococcal meningitis with combination amphotericin B and flucytosine for four as compared with six weeks. *N Engl J Med* 1987; 317: 334-341
8. Bozzette SA, Larsen RA, Chiu J, Leal MA, Jacobsen J, Rothman P, et al. A placebo-controlled trial of maintenance therapy with fluconazole as treatment of cryptococcal meningitis in the acquired immunodeficiency syndrome. California Collaborative Treatment Group. *N Engl J Med* 1991; 324: 580-584
9. Chugh KS, Sakhuja V, Jain S, Singh V, Tarafdar A, Joshi K, et al. Fungal infections in renal allograft recipients. *Transplant Proc* 1992; 24: 1940-1942