

How to assess severe tricuspid regurgitation by echocardiography?

L. Elif Sade ^{1,2}, Denisa Muraru ^{3,4}, Nina Ajmone Marsan ⁵,
Eustachio Agricola ⁶, Ivan Stankovic ⁷, and Erwan Donal ^{8*}

¹University of Pittsburgh Medical Center, Heart and Vascular Institute, Pittsburgh, PA, USA; ²Department of Cardiology, University of Baskent, Ankara, Turkey; ³Department of Medicine and Surgery, University of Milano-Bicocca, Milan, Italy; ⁴Department of Cardiological, Neural and Metabolic Sciences, Istituto Auxologico Italiano, IRCCS, San Luca Hospital, Milan, Italy; ⁵Department of Cardiology, Leiden University Medical Center, Albinusdreef 2, 2300 RC, Leiden, The Netherlands; ⁶Cardiovascular Imaging Unit, San Raffaele Hospital, IRCCS, Vita-Salute San Raffaele University, Milan, Italy; ⁷Faculty of Medicine, Clinical Hospital Centre Zemun, University of Belgrade, Belgrade, Serbia; and ⁸Cardiologie, CHU de RENNES, LTSI UMR1099, INSERM, Université de Rennes-1, Rennes 35033, France

Received 28 December 2021; editorial decision 13 January 2022; accepted 14 January 2022; online publish-ahead-of-print 8 February 2022

Tricuspid regurgitation (TR) is the most commonly functional resulting from right ventricular (RV) (ventricular) remodelling by pressure/volume overload or right atrial (RA) remodelling (atrial) where annular dilatation is the main driver with underlying atrial fibrillation. Cardiac implantable electronic device-related (leaflet impingement, perforation, avulsion etc.) TR represents the second important group. Organic TR of different aetiologies is less frequent.

Particular aspects of TR

- TR occurs with lower driving pressure and velocity than mitral regurgitation (MR), unless there is severe pulmonary hypertension (PH). As a result, a smaller TR jet area than MR is generated for the same effective regurgitant orifice area (EROA) due to lower velocity flow, as explained by the conservation of momentum (orifice area.v²).¹ Therefore, colour jet area as used for MR underestimates the severity of TR. However, lower velocities within the right heart should not be resolved by too low Nyquist limits to avoid random noise. Also, EROA of TR is frequently elliptical or rectangular. Consequently, different grading cut-offs have been proposed for TR (Table 1).¹
- Both TR EROA and volume are subject to respiratory changes and increase by 20% on average, during inspiration. In severe TR, because of the increase of TR during inspiration, right atrial (RA)

pressure also increases, approximating RV systolic pressure. An inspiratory decrease of TR peak velocity ≥ 0.6 m/s indicates severe TR, which in turn affects EROA calculations.²

- Increasing RV afterload induces functional TR; however, TR severity is not linearly related to PH because other modulators such as tricuspid annulus (TA) dilatation, leaflet tethering, and RA and RV remodelling also affect TR severity. Ventriculo-pulmonary arterial coupling defines RV contractile function indexed to afterload and impacts Doppler measurements. Low-velocity TR jet through a large orifice, produced by a severely impaired RV contraction may be easily underestimated by a non-turbulent low-velocity flow.
- An integrated approach including tricuspid valve (TV) morphology and deformation, TR severity, RV afterload, RV and RA remodelling, annulus size, left-sided valve disease, as well as left ventricular function is pivotal to assess TR severity.

Data acquisition

There is no specific acoustic window for visualizing TV or TR jet by transthoracic echocardiography (TTE). Several views including parasternal RV inflow, parasternal short-axis, apical four-chamber, and sub-costal long- and short-axis views should be examined in order to optimize the alignment with TR flow direction and visualization of tricuspid leaflets. Only the subxiphoid short-axis view by TTE and transgastric view around 45° by transoesophageal echocardiography allow

Table 1 Updated cut-offs for TR severity

Parameters	Mild	Moderate	Severe	Massive	Torrential
Biplane vena contracta width (mm)	<3	3–6.9	7–13	14–20	≥ 21
EROA by PISA (mm ²)	<20	20–39	40–59	60–79	≥ 80
Quantitative Doppler EROA (mm ²)			75–94	95–114	≥ 115

* Corresponding author. Tel: +33299282525, Fax: +33299282510. E-mail: erwan.donal@chu-rennes.fr

Published on behalf of the European Society of Cardiology. All rights reserved. © The Author(s) 2022. For permissions, please email: journals.permissions@oup.com.

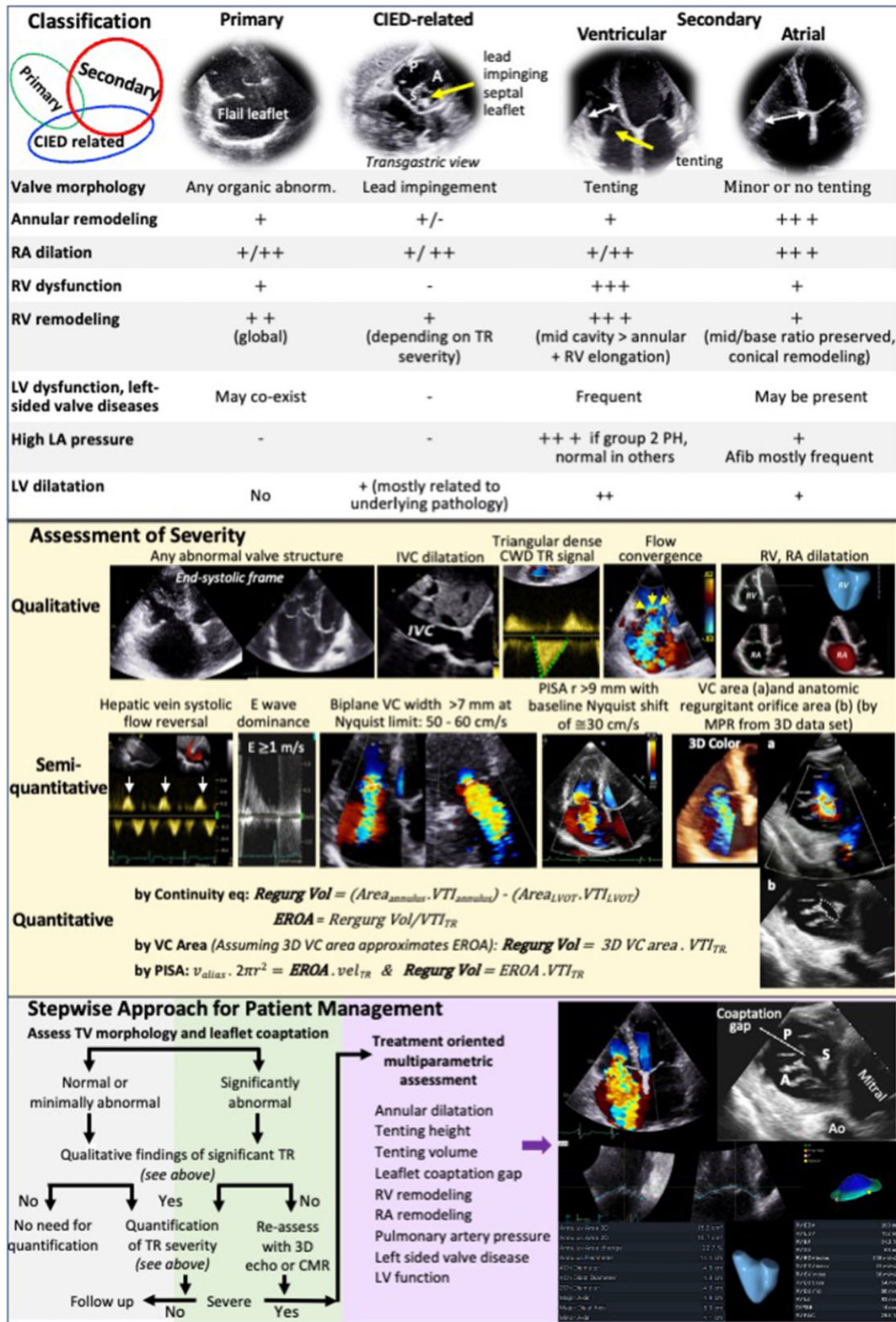


Figure 1 Practical approach for assessing severe TR by echocardiography. A, anterior; Ao, aorta; P, posterior; Pm, pacemaker; S, septal; all other abbreviations as in the text.

simultaneous visualization of all three leaflets by 2D. Real-time 3D echocardiography complements 2D examination. An optimal 3D TTE acquisition of the TV can be achieved from the RV-focused apical or a foreshortened four-chamber view. Yet, any acoustic window that enables good image quality with optimal perpendicular ultrasound beam to the valve plane can be attempted to acquire the 3D dataset by using a zoomed mode that encompasses the entire TV.

Assessment of severity

Tricuspid valve morphology

Leaflet tethering, tenting, and coaptation loss are typical for functional TR. In case of organic TR, any severe intrinsic abnormality of the valve structure is sign of severe TR.

Spectral Doppler

Continuous-wave Doppler (CWD) signal intensity is proportional to TR severity. Most TR tracings are parabolic in shape. Dense, early peaking, triangular CWD signal is typical for severe TR. Hepatic vein systolic flow reversal and E -wave velocity ≥ 1 m/s by pulsed-wave Doppler are supportive, but not diagnostic, for severe TR due to other modulators including the size and compliance of the RA and RV function. Late peaking high-velocity TR jets are usually seen with PH because of septal-free wall RV dyssynchrony and are usually less than severe.

Colour Doppler

Jet area: Although a ratio of jet-to-RA area ($\geq 34\%$) roughly suggests severe TR at a Nyquist limit of 50–70 cm/s, colour jet area is the least reliable index of TR severity.

Proximal flow convergence zone is defined as a series of hemispheric isovelocity shells of increasing velocity and decreasing surface area towards the regurgitant orifice. To better visualize the hemisphere-like contour of the convergence zone, the Nyquist limit is shifted in the same direction of regurgitation by using a zoomed view with optimal insonation angle without variance. Convergence zone radius > 9 mm obtained at a Nyquist limit of ≈ 30 cm/s indicates severe TR.

Vena contracta (VC) width should be averaged from RV inflow and apical four-chamber views. Simultaneous orthogonal planes obtained from biplane imaging using the matrix probe should be preferred if available. VC is independent of flow rate, eccentricity, and driving pressure for a fixed orifice. VC cross-section area is often ellipsoidal, crescent along the septal leaflet or rectangular and can be planimetered from 3D multiplanar reconstruction. The frame that corresponds to peak velocity should be chosen for planimetry. 3D VC area, theoretically identical to EROA, correlates strongly with quantitative Doppler EROA. Yet, the VC area is a static measurement dependent on colour gain and no consensus exists on VC area cut-off for severe TR. However, for periprocedural assessment of candidates undergoing percutaneous TV repair, a consensus on five TR grades has been reached out including biplane VC diameter and area. VC

area is theoretically feasible for multiple jets, but high spatial and temporal resolutions are needed. Dynamic jets can be over- or underestimated. VC overestimates non-holosystolic TR. Although planimetry of the anatomic regurgitant orifice area is feasible by 3D echocardiography, this is ideally measured by computerized tomography.

Volumetric quantification

Proximal isovelocity surface area (PISA) defines the outer shell of the convergence zone with a velocity that equals to aliasing velocity. Regurgitant volume is obtained by multiplying the aliasing velocity with the area of the assumed outer hemisphere with a radius from the aliasing point to the orifice. Typically, EROA by PISA underestimates the true EROA (particularly in functional TR) in comparison to continuity equation results. Different cut-offs for severe TR apply depending on the quantification tool (PISA-EROA compared with 3D-vena contracta area or Doppler-EROA) mainly because of noncircular orifices (Table 1).¹ Of note, although EROA ≥ 40 mm² and regurgitant volume ≥ 45 mL/beat are considered severe, recently lower thresholds have been reported to predict high-risk for adverse outcome.³ In contrast to the continuity equation, PISA method cannot be used for multiple jets, non-hemispheric convergence zones and non-holosystolic flows.

Tricuspid annulus

Isolated TA dilation may induce severe TR. TA dilation is the most important mechanism underlying atrial functional TR. TA is slightly spherical, saddle-shaped and dynamic during the cardiac cycle. Although aging does not significantly change TA size, TA dimensions should be expressed as gender and body size specific. TA has the largest size at late diastole. TA dilation pulls apart the anterior and posterior leaflets from the central coaptation line. 2D orthogonal TA dimensions are typically measured from the RV-focused apical four-chamber and RV inflow views although slightly under-estimated. Orthogonal long-axis planes obtained from 3D dataset allow measurement of septolateral and anteroposterior dimensions at the level of TA simultaneously. Normal TA longest and shortest dimensions in end diastole were reported as 36 ± 4 mm and 30 ± 4 mm, and maximal TA area at late diastole as 11 ± 3 cm² (6 ± 1 cm²/m²), maximum perimeter as 12 ± 1 cm (7 ± 1 cm/m²), and annular height as average 7 mm.³ 3D semi-automated software for TA assessment increases the accuracy of annular measurements given the limitations of 2D for a non-planar geometry and an out-of-axis enlargement.

Leaflet coaptation

The minimum length of body-to-body coaptation of the leaflets should be ≥ 5 mm to prevent regurgitation. Normal coaptation of the tricuspid leaflets takes place either at the TA level or more apically just below it. Functional TR occurs if the coaptation surface decreases due to TA dilation or tethering. Tenting distance is the distance between leaflet coaptation point and annular plane and tenting area is between closed leaflets and annular plane. TV leaflet tethering is considered significant when tethering distance is > 8 mm

and tenting area is $>1.6 \text{ cm}^2$ with the assumption that tethering of the leaflets is symmetric and that the apical four-chamber view allows visualization of the highest coaptation point which is not necessarily correct in patients with functional TR.^{4,5} Tenting volume can be quantified ideally by 3D echocardiography to overcome these assumptions (Figure 1).

Conflict of interest: DM+ ED+ ES: collaboration with General electric Healthcare; EA + ED: collaboration with Abbott vascular; EA: speaker and proctoring fees, research and educational grant from Philips, Edwards Lifesciences, Abbott, GE, and Siemens; NA: Speaker fees from GE Healthcare and Abbott Vascular and member of Medical Advisory Board of Philips Ultrasound; IS: none.

References

1. Hahn RT, Thomas JD, Khaliq OK, Cavalcante JL, Praz F, Zoghbi WA et al. Imaging assessment of tricuspid regurgitation severity. *JACC Cardiovasc Imaging* 2019;**12**:469–90.
2. Mutlak D, Carasso S, Lessick J, Aronson D, Reisner SA, Agmon Y et al. Excessive respiratory variation in tricuspid regurgitation systolic velocities in patients with severe tricuspid regurgitation. *Eur Heart J Cardiovasc Imaging* 2013;**14**:957–62.
3. Muraru D, Previtero M, Ochoa-Jimenez RC, Guta AC, Figliozzi S, Gregori D et al. Prognostic validation of partition values for quantitative parameters to grade functional tricuspid regurgitation severity by conventional echocardiography. *Eur Heart J Cardiovasc Imaging* 2021;**22**:155–65.
4. Badano LP, Hahn R, Rodríguez-Zanella H, Araiza Garaygordobil D, Ochoa-Jimenez RC, Muraru D et al. Morphological assessment of the tricuspid apparatus and grading regurgitation severity in patients with functional tricuspid regurgitation: thinking outside the box. *JACC Cardiovasc Imaging* 2019;**12**:652–64.
5. Addetia K, Muraru D, Veronesi F, Jenei C, Cavalli G, Besser SA et al. 3-Dimensional echocardiographic analysis of the tricuspid annulus provides new insights into tricuspid valve geometry and dynamics. *JACC Cardiovasc Imaging* 2019;**12**: 401–12.