

# DermaI Regenerators in Burns and Sequelae

Ricardo Roa, Gabriel Diaz

## ABSTRACT

**The advent of dermal substitutes has marked a significant development for the management of burn wounds and sequelae, improving scar quality and overall quality of life of patients with burns. Its use replaces other, more morbid surgical options and represents a very useful tool in reconstructive surgery. Their benefits and limitations, along with examples of our use, will be reviewed in this article.**

**KEY WORDS:** *Dermal substitute, Scars*

## INTRODUCTION

From a physiological standpoint, we know that, in the process of cicatrization of burns, there are many intervening factors. Within these factors, it has been established that the epidermis is the basis for scar formation, but the main factor involved in scar quality, and the one that influences the outcome and sequelae the most, is the regeneration of the underlying dermis.

Currently, the gold standard for surgical skin coverage is the dermoepidermal graft. Skin grafting is a surgical procedure that is relatively simple to perform and widely available, but it has a series of problems and limitations, particularly those from the donor site (adding a new injury, the potential for morbidity and complications, and the limited availability of healthy skin, especially in older adults and burn victims) and those related to the cicatrization process, such as the formation of scars, retraction, pigmentation, and the fact that the dermis is only partially replaced.<sup>1</sup>

From the Plastic Surgery Department and Burn Unit, Hospital del Trabajador, Santiago, Chile

**ACKNOWLEDGEMENTS:** The authors have not received any funding or grants in support of the presented research or for the preparation of this work and have no declarations of potential conflicts of interest.

**CORRESPONDING AUTHOR:** Ricardo Roa, Plastic Surgery Department and Burn Unit, Hospital del Trabajador, Santiago, Chile

**E-mail:** ricardoroag@gmail.com

Burn Care and Prevention 2021/4: 118-126

In the search for an ideal skin substitute, a series of desirable characteristics have been proposed in the literature: wound protection from infection and fluid leakage, stable and biodegradable film for neodermis synthesis, low antigenicity, hosting dermal cells producing dermal tissue instead of scar, easy handling, adaptation to the wound bed, fixation, durable and resistant to traction, and an effective cost.<sup>2</sup> Dermal substitutes have emerged as a promising alternative in this field, and their benefits and limitations, as well as our personal experiences with their use, will be reviewed in this article.

## DermaI Substitutes

Currently, dermal substitutes can be classified into 3 categories depending on the skin layer that they replace: epidermal, dermal, or both epidermal and dermal.<sup>3</sup> Within epidermal skin substitutes, the main substances utilized are keratinocytes (Epicel, Laserskin, Vivoderm, Cellspray, Epidex, Bioseed, ReCell, TranSCell, among others). In the category in which both the epidermis and dermis are combined, these are mainly composed of a matrix + cells such as keratinocytes and fibroblasts (Apligraf, Orcel, among others). Dermal substitutes can be further classified according to the presence of cells in acellular or cellular matrices. Within the acellular matrix group, we can further classify according to the main substance composing the matrix, whether it corresponds to mammalian collagen (bovine = Integra, Matriderm, Pelnac, Terudermis, Primatrix, Renoskin, among others; or porcine = Permacol, Oasis, EZ-Derm, among others), human collagen/elastin (Alloderm, GlyaDerm, SureDerm, GraftJacket, among others), or hyaluronic acid (Hyalomatrix). Within the cellular group, the main substances correspond to a matrix + cells such as fibroblasts (Dermagraft, Hyalograft 3D, among others).

## Human Acellular Dermal Substitutes (Alloderm, Glyaderm, Surederm)

These dermal substitutes consist of a cryopreserved lyophilized allodermis protein matrix. It does not include

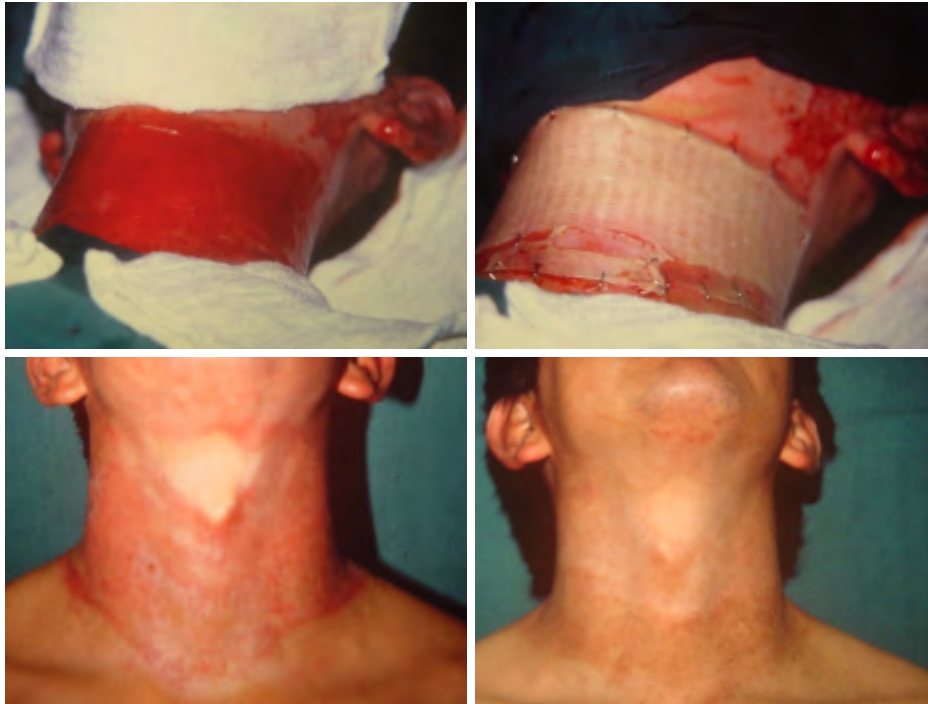
an epidermal equivalent; thus, it can be utilized in conjunction with dermoepidermal grafts. Its use has been approved for the treatment of burns and sequelae and for cosmetic surgery.

#### **Alloderm**

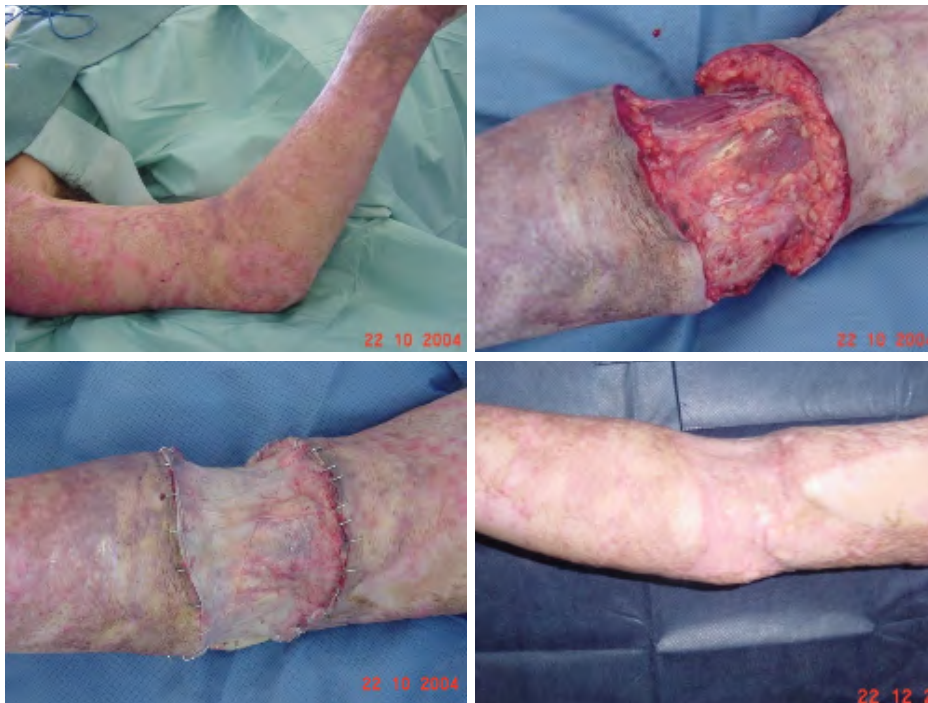Alloderm has many advantages, including that it provides good quality scars, has excellent joint functionality, has

potential for preventive use, can be applied during a single surgical time, can treat adhesions and depressions, and has overall better cost-effectiveness. Disadvantages include difficulty with adhesion to the wound bed, graft loss, the fact that it requires a vital wound bed, its presentation in small sizes, and the frequent postsurgical care required. Examples of its use are shown in Figure 1 and Figure 2.

**FIGURE 1.** Use of Alloderm Acellular Matrix in Management of Acute Burn



**FIGURE 2.** Use of Alloderm Acellular Matrix in Management of Sequelae



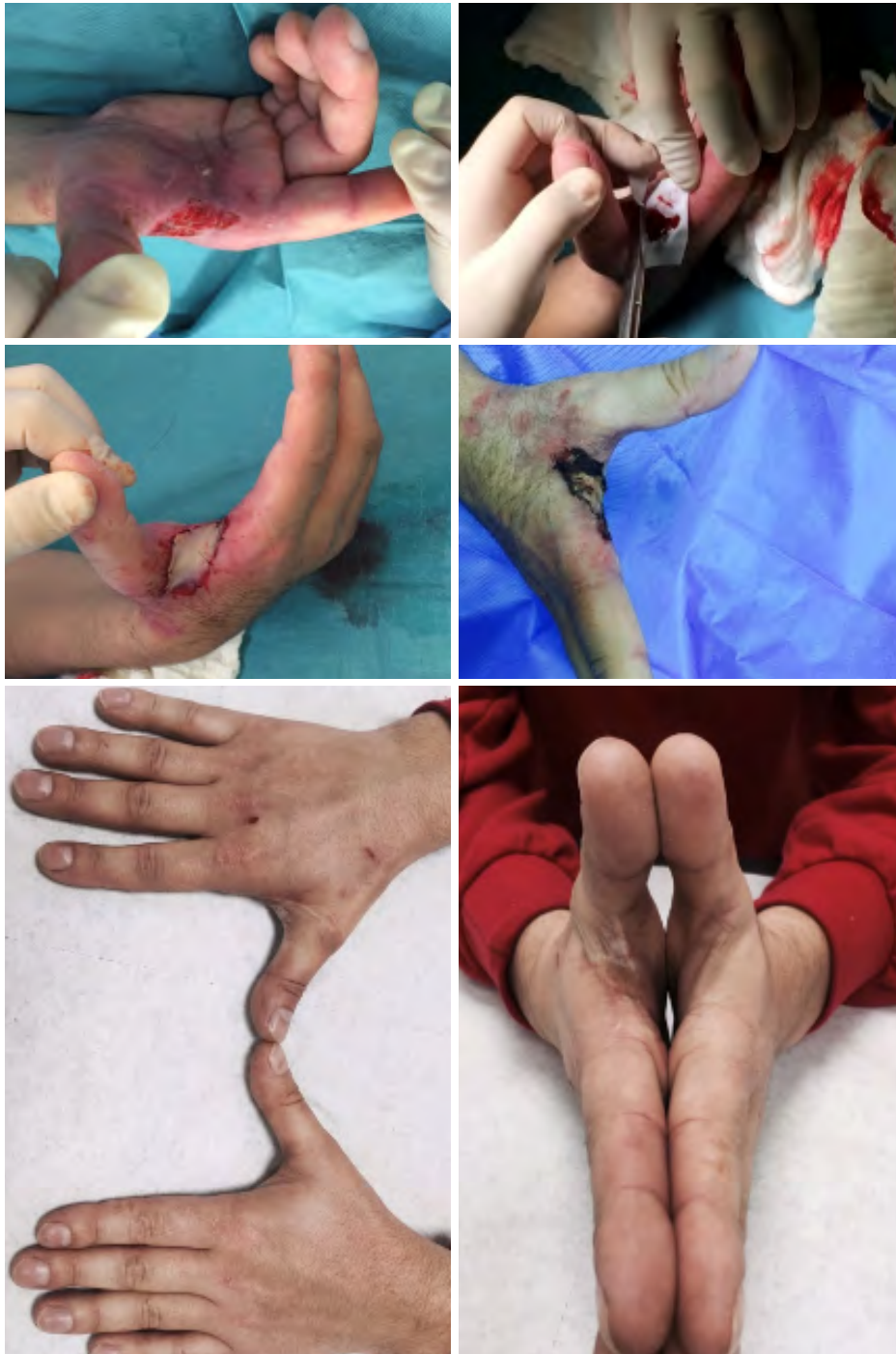## Acellular Bovine Collagen

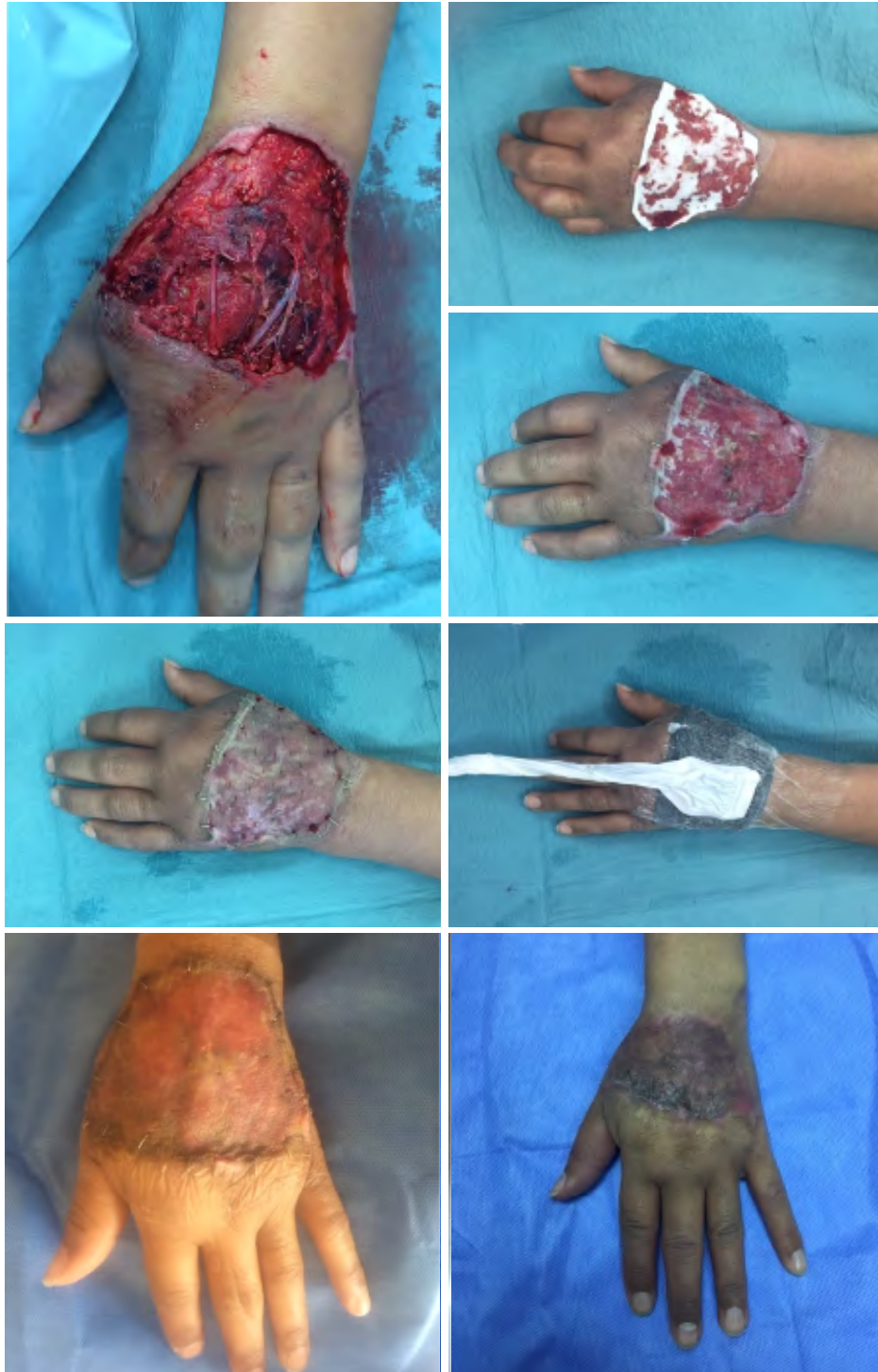### Matriderm

Matriderm consists of a matrix composed of bovine collagen and elastin. This matrix allows for a better dermal

regeneration as it allows fibroblastic invasion. It can be combined with autologous skin grafting for improved functionality over grafting alone. An example of its use is shown in Figure 3 and Figure 4.

**FIGURE 3.** Use of Matriderm Acellular Matrix in Management of Acute Burn



**FIGURE 4.** Immediate Coverage With Matriderm and Skin Graft With Use of Negative Pressure Wound Therapy

The patient was a 32-year-old female patient who had a severe work injury with burn and crush wounds on the left hand.

### Integra

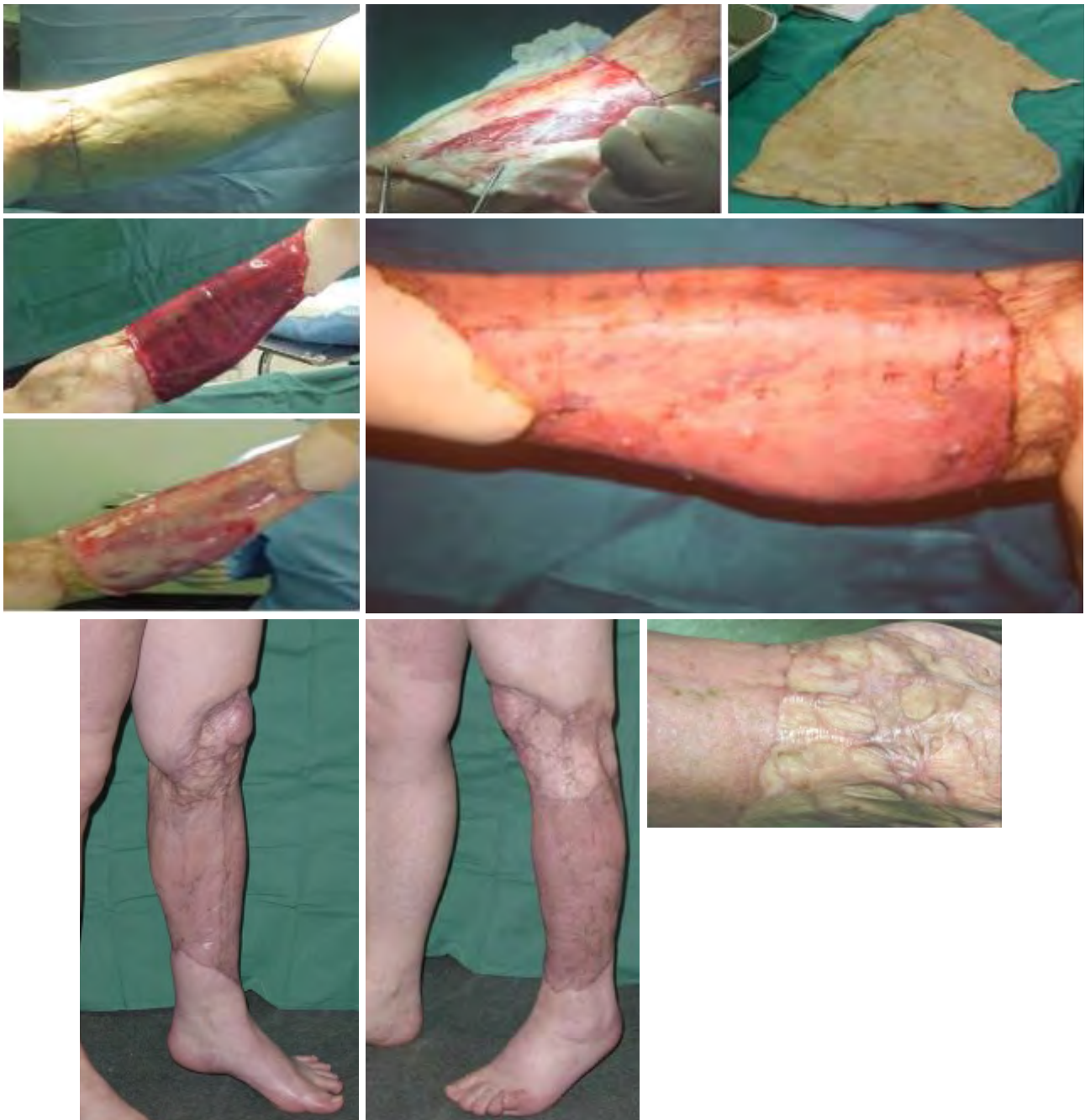Integra was first introduced in 1981 by Yannas and Burke<sup>4</sup> and was approved by the Food and Drug Administration for burn use in 1997. It consists of a silicone surface layer overlying a bovine collagen (Achilles tendon) plus a

glycosaminoglycan shark cartilage acellular matrix. This substance allows for vascularization and dermal regeneration in about 21 days and the use of a thinner skin graft for coverage. The complete degradation occurs at 5 weeks after the application of the product.<sup>3</sup>

The wound bed must be devoid of any devitalized tissue and free from infections and high bacterial colonization. Careful attention must be paid to a rigorous and focused hemostasis. A template of Integra acellular matrix is sutured to the edges of the wound to ensure adhesion and immobilization is secured using negative pressure wound therapy. Autologous skin grafting is accomplished once dermal regeneration is adequate, in a second surgical procedure.

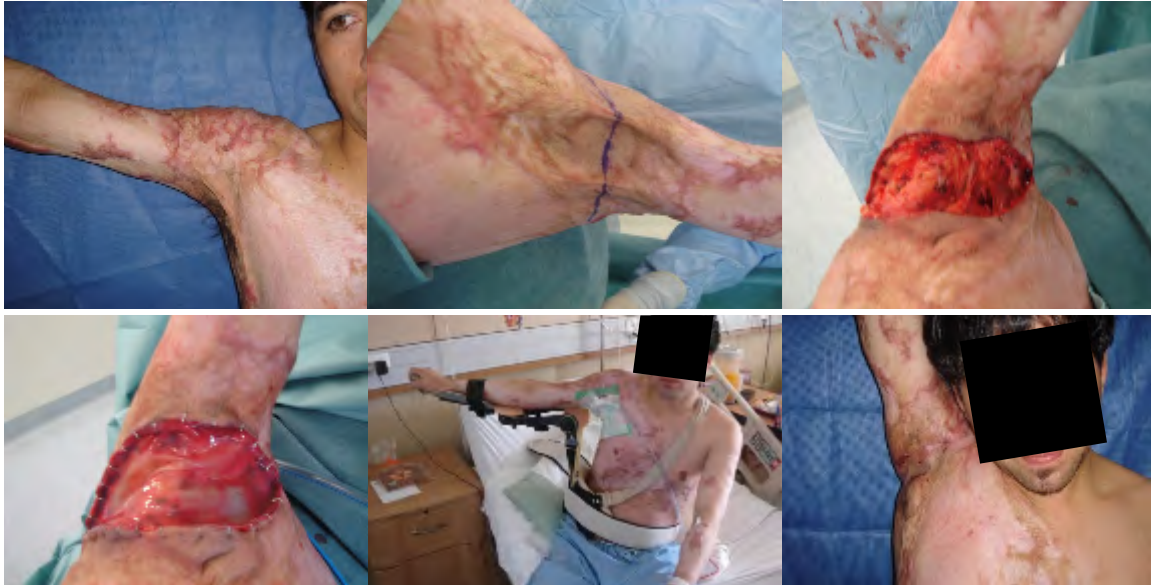Advantages identified with the use of Integra acellular matrix include minimal scarring at the donor site (thinner grafts), excellent functionality of joints, better cosmetic appearance than autologous grafts alone, absence of bulkiness of the contributed tissue, no creation of new lines of tension, and usefulness for coverage of extensive injuries. Examples of use of Integra are shown in Figure 5, Figure 6, Figure 7, Figure 8, Figure 9, and Figure 10.

**FIGURE 5.** Management of Burn Sequelae With Integra Acellular Matrix + Autologous Skin Graft



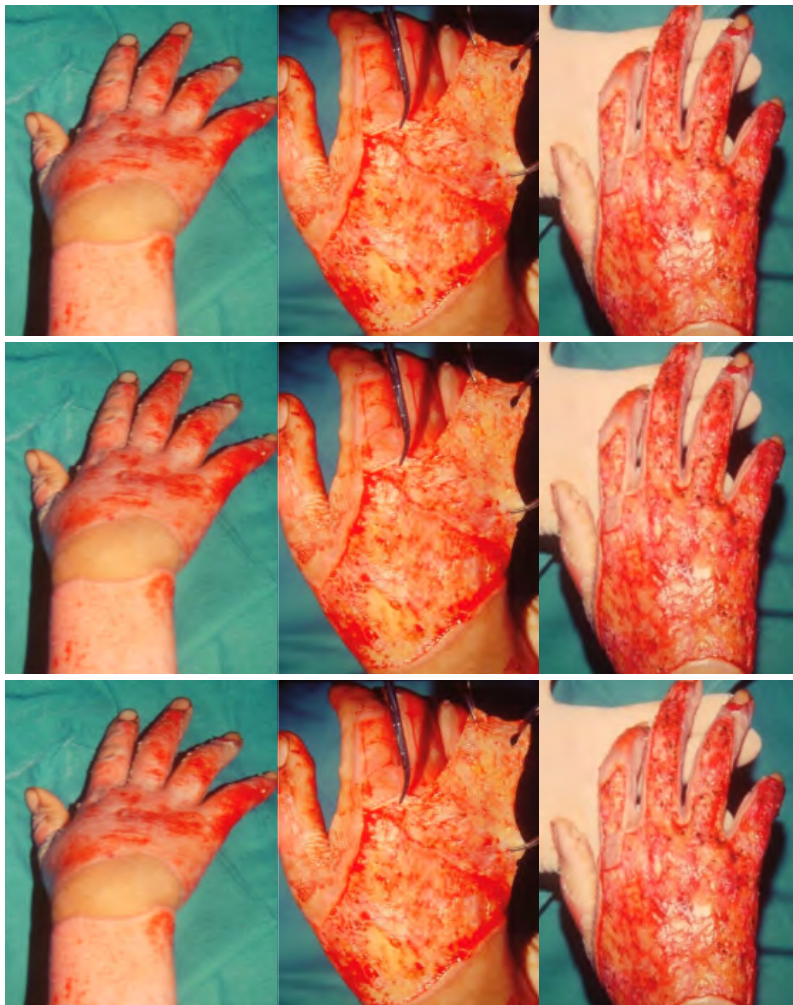Bottom images compare scar with **(left)** and without **(right)** the use of Integra.

**FIGURE 6.** Management of Contracture Due to Axillary Burn With Integra Acellular Matrix

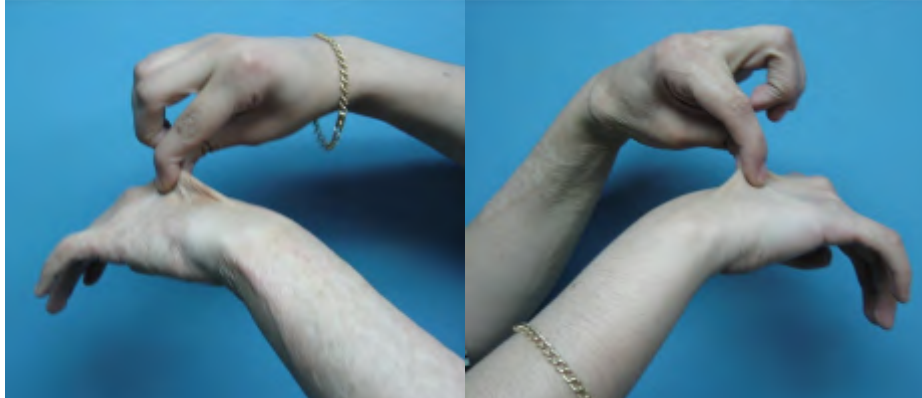
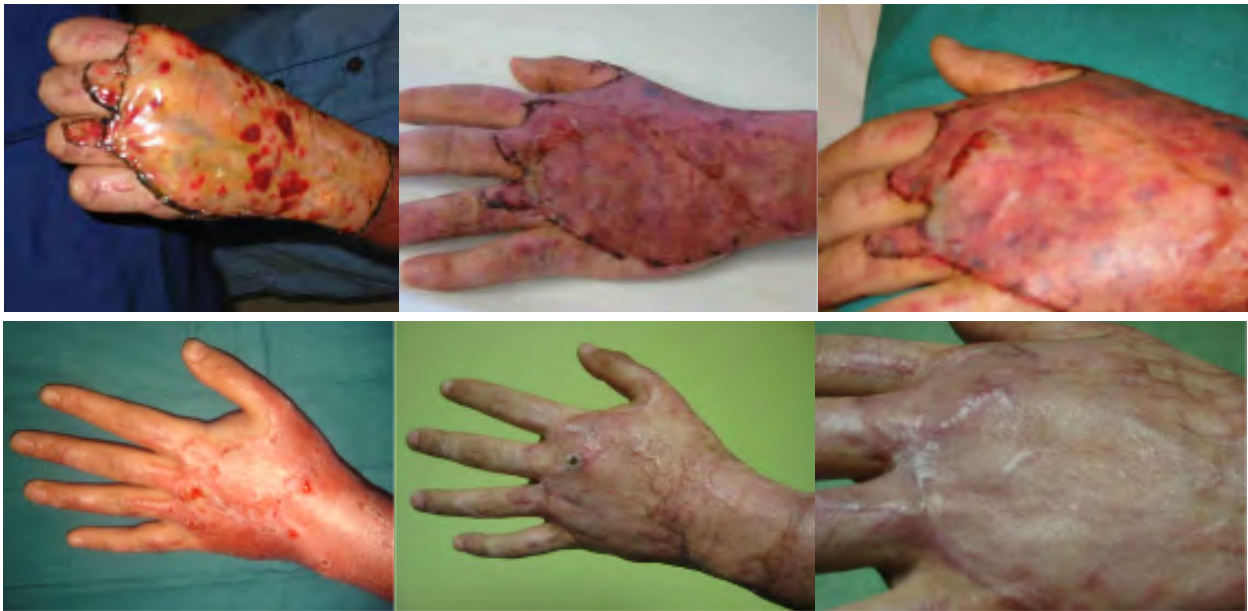
**(Top left)** Preoperative photo. **(Bottom right)** 3 months after surgery.

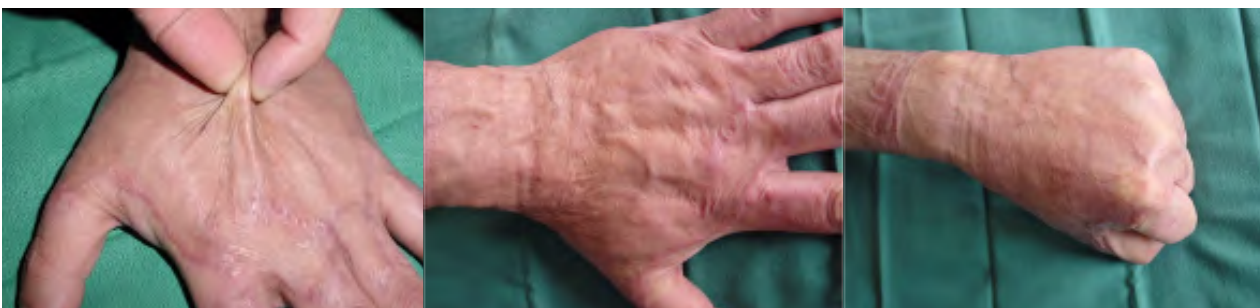**FIGURE 7.** Management of Acute Burn of Right Hand With Integra + Skin Graft



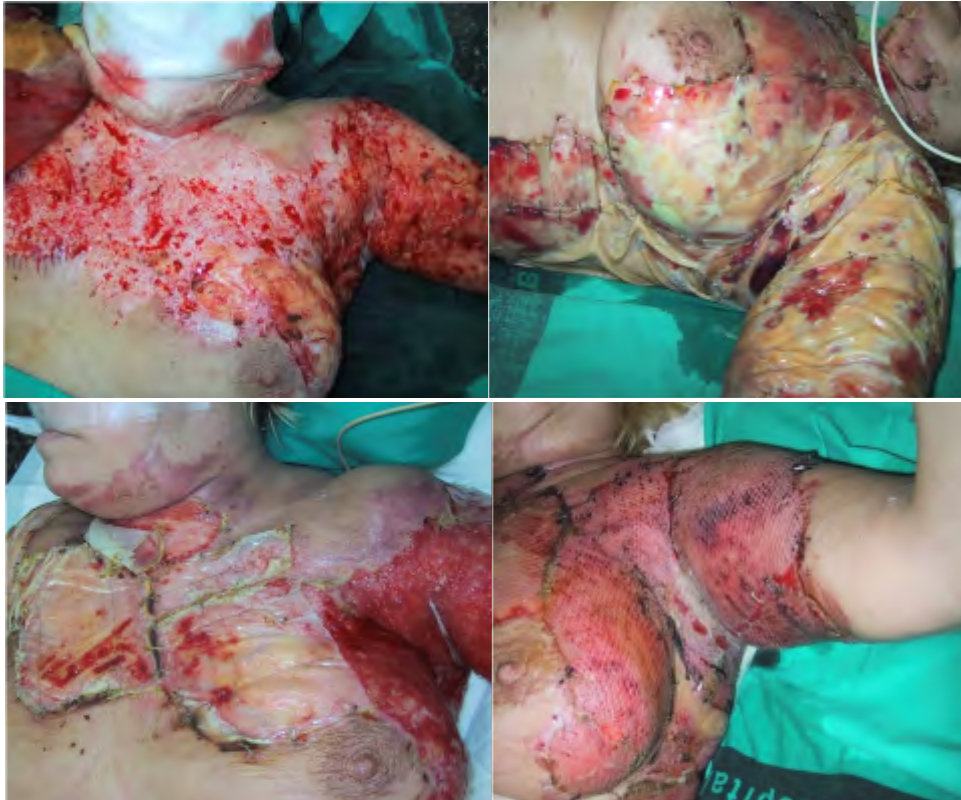**(Bottom center)** 2 months after surgery. **(Bottom right)** 3 months after surgery.

**FIGURE 8.** Patient Demonstrating Skin Pliability**(Left)** Integra acellular matrix + skin graft. **(Right)** Native skin.**FIGURE 9.** Management of Burn Injury to Left Hand Using Integra + Skin Graft

Shown left to right are intraoperative images with Integra in situ, dermoepidermal graft on postoperative day 4, postoperative day 12, postoperative day 29, postoperative month 3, and postoperative month 4.

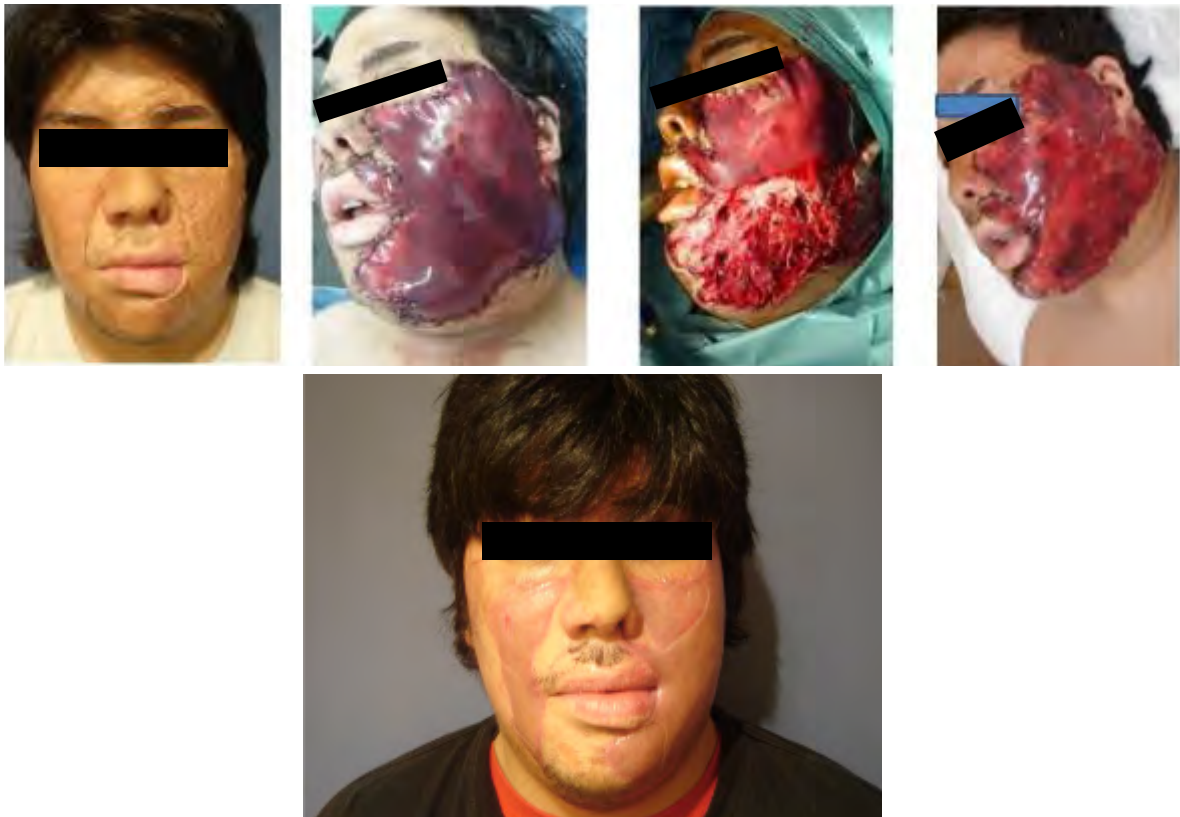
**FIGURE 10.** Postoperative Results of Management of Burn Injury to Hand With Integra Showing Next-to-Normal Skin Pliability

**FIGURE 11.** Burn Patient Treated With Integra With Development of Infection Leading to Loss of Matrices



Integra had to be partially removed from the wound bed, and the patient received skin graft at a later time.

**FIGURE 12.** Burn Sequelae of Face Managed With Integra Showing Complication With Immediate Postoperative Hematoma



**(Top right)** Partial implant replacement. **(Bottom)** Final postoperative result.

Disadvantages include the possibility of loss due to infection, its absence of hemostatic capacity, the requirement of a vital wound bed, its high cost and the necessity of frequent postoperative wound care, and the fact that it requires at least 2 surgical procedures, with an extended time between both surgeries.

Complications identified with the use of Integra are hematoma, infections, lack of dermal regeneration, and early release of the protective silicone layer.

Regarding infection, this is the most feared complication, as it can lead to a loss of the matrix. Matrices are practically breeding grounds for bacteria; hence, it is important to provide a clean, vital wound bed. Infections are most typically seen in acute cases when no prior microbiological studies have been conducted. In this regard, it is recommended that the bacteriological conditions are evaluated before surgery and that there is rigorous use of antiseptics perioperatively along with use of surgical antibiotic prophylaxis. Figure 11 shows an example of matrix loss after infection.

Regarding hematomas, one of the limitations of Integra is its lack of hemostatic capacities. In most cases, hematomas appear early after surgery and can have a wide range of extension, associated with increasing risk of matrix loss (partial or total). These are more frequently observed in mobile areas. Figure 12 shows an example of a hematoma, which appeared after treatment of face burn sequelae with Integra.

### New Trends

As with any surgical procedure, there is still significant room for improvement. The integration period of the acellular matrix can be shortened with the use of negative

pressure wound therapy; we suggest that its use should be mandatory whenever possible. Negative pressure wound therapy can result in improvement of implant adherence, a decrease in the incidence of seromas and hematomas, a shortening in the integration period, improvement in graft take, and, in the case of Integra single layer, a single surgical time.

Other areas of interest are the development of thicker dermis products and modifications of existing products to allow for immediate skin grafting over the matrix.

## CONCLUSIONS

The advent of dermal substitutes has been a significant development for the management of burn wounds and sequelae, improving scar quality and overall quality of life of patients with burns. Its use replaces other, more morbid surgical options and represents a very useful tool in reconstructive surgery. To ensure favorable outcomes, its use must be judicious. General factors to consider are the size, depth, and location of the lesions, the availability of neighboring tissues, the availability of clinical supplies, the experience of the work team in charge, and the capabilities to provide postoperative care.

## REFERENCES

1. Schulz JT 3rd, Tompkins RG, Burke JF. Artificial skin. *Annu Rev Med.* 2000;51:231-244. doi:10.1146/annurev.med.51.1.231
2. Sheridan RL, Tompkins RG. Skin substitutes in burns. *Burns.* 1999;25(2):97-103. doi:10.1016/s0305-4179(98)00176-4
3. Brusselsaers N, Pirayesh A, Hoeksema H, et al. Skin replacement in burn wounds. *J Trauma.* 2010;68(2):490-501. doi:10.1097/TA.0b013e3181c9c074
4. Burke JF, Yannas IV, Quinby WC Jr, Bondoc CC, Jung WK. Successful use of a physiologically acceptable artificial skin in the treatment of extensive burn injury. *Ann Surg.* 1981;194(4):413-428. doi:10.1097/00000658-198110000-00005