

Isolated Ocular Surface Squamous Neoplasia in a Renal Transplant Recipient

Nimet Aktas,¹ Alparslan Ersoy,¹ Bulent Yazici,² Nurten Kilic,³ Berna Aytac⁴

Abstract

Ocular surface squamous neoplasia is a rare complication after a kidney transplant, related with increased risk and poor prognosis. Generally, ocular surface squamous neoplasia in kidney transplant patients is associated with skin lesions. We report a case of ocular surface squamous neoplasia without skin lesions in a kidney transplant recipient. Systematic periodic ophthalmic evaluation of recipients may help ensure the early diagnosis of subtle ocular surface squamous neoplasia.

Key words: Malignancy, Ocular surface squamous neoplasia, Renal transplant, Skin cancer, Complication

Introduction

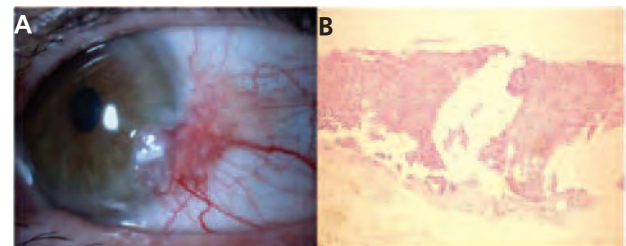
Several studies have reported the incidence of malignancy in the kidney transplant (KT) population is increased compared with the general population. One of most common malignancies encountered in solid-organ transplants is nonmelanoma skin cancer. The development of ocular surface squamous neoplasia (OSSN) in patients having a KT has been reported.¹⁻³ Here, we describe a case of OSSN without skin lesions after a KT and review the literature.

Case Report

A 34-year-old man, who had been undergoing hemodialysis for 1 year, had a living-donor KT in

July 2003 owing to unknown end-stage renal disease. Immunosuppressive treatment was composed of tacrolimus, prednisolone, and mycophenolate mofetil. His posttransplant course was uneventful. After 6 years, he presented with complaints of swelling and redness in his left eye of 2 months' duration. On ocular examination, we found a conjunctival mass in the temporal limbal conjunctiva extending over the cornea, measuring 7 × 6 mm in diameter (Figure 1A). An excisional biopsy, including the lesion and the surrounding 3-mm margin, was performed and was diagnosed squamous cell carcinoma (Figure 1B). On dermatologic examination, there were no skin lesions on the patient. Postoperatively, he was treated for 2 months with topical mitomycin-C eye drops. At the time of this writing, no recurrence has developed during a 3-year follow-up.

Figure 1. Slit-Lamp and Histological Appearances of OSSN



(A) Conjunctival squamous neoplasia with gelatinous and leukoplakic features in the interpalpebral fissure adjacent to the limbus;
(B) Atypical squamous cells invading subepithelial stroma of conjunctiva appearances of the left eye.

Discussion

The cause of posttransplant cancer is multifactorial including direct cancer promoting effect of immunosuppressive drugs. The development of OSSN after KT is rare.¹⁻³ The major causative factor for OSSN is exposure to solar ultraviolet radiation.¹ The increased risk of OSSN in our case was likely related to the

From the ¹Nephrology Department, the ²Ophthalmology Department, the ³Internal Medicine and the ⁴Pathology Department, Department, Uludag University Medical School, Bursa

Acknowledgements: There is no statement of financial or other relationships that might lead to a conflict of interest.

Corresponding author: Dr. Alparslan Ersoy, Department of Nephrology, Uludag University Medical School, 16059 Nilufer, Bursa, Turkey

Phone: +90 224 295 1413 Fax: +90 224 295 1444

E-mail: alpersoy@uludag.edu.tr

Experimental and Clinical Transplantation (2012) 5: 506-507

immunosuppressive drugs he was taking and to ultraviolet radiation. Others risk factors include human papilloma virus, human immunodeficiency virus, having an outdoor occupation, fair skin-iris, chemical exposure, some medications (including cyclosporine), chronic inflammatory diseases of eye, vitamin A deficiency, mechanical trauma (eg, ocular prosthesis), contact lens wearing, and a history of actinic skin lesions.^{1, 4, 5} Vajdic and associates,¹ diagnosed squamous cell carcinoma of eye in 5 patients with 1 or more skin carcinomas determined either before or after eye involvement in 10 180 KT recipients. OSSN usually accompanies skin cancer owing to a similar cause. Based on a total of 86 898 person-years' follow-up, they reported a 20-fold increase in the incidence of squamous cell carcinoma of the eye after KT when azathioprine and/or cyclosporine were used.¹ However, the present case is the first isolated OSSN without skin carcinoma in KT recipients after long-term tacrolimus treatment.^{1-3,6} In this male patient, there is no skin cancer after three years follow-up. OSSN, which is considered to be a low-grade malignancy, usually tends to recur within 2 years. Its metastases are rare, causing a delay in diagnosis and treatment

of disorders.^{4,5} A recent study reported that refractory OSSN may be treated with subconjunctival antivascular endothelial growth factor chemotherapy.⁷

In conclusion, early diagnosis and treatment will decrease ocular and systemic complications.

References

1. Vajdic CM, van Leeuwen MT, McDonald SP, et al. Increased incidence of squamous cell carcinoma of eye after kidney transplantation. *J Natl Cancer Inst.* 2007;99(17):1340-1342.
2. Macarez R, Bossis S, Robinet A, Le Callonnec A, Charlin JF, Colin J. Conjunctival epithelial neoplasias in organ transplant patients receiving cyclosporine therapy. *Cornea.* 1999;18(4):495-497.
3. Shome D, Honavar SG, Manderwad GP, Vemuganti GK. Ocular surface squamous neoplasia in a renal transplant recipient on immunosuppressive therapy. *Eye (Lond).* 2006;20(12):1413-1414.
4. Pe'er J. Ocular surface squamous neoplasia. *Ophthalmol Clin North Am.* 2005;18(1):1-13.
5. Hamam R, Bhat P, Foster CS. Conjunctival/corneal intraepithelial neoplasia. *Int Ophthalmol Clin.* 2009;49(1):63-70.
6. Shields CL, Ramasubramanian A, Mellen PL, Shields JA. Conjunctival squamous cell carcinoma arising in immunosuppressed patients (organ transplant, human immunodeficiency virus infection). *Ophthalmology.* 2011;118(11):2133-2137.
7. Finger PT, Chin KJ. Refractory squamous cell carcinoma of the conjunctiva treated with subconjunctival ranibizumab (Lucentis): a two-year study. *Ophthalm Plast Reconstr Surg.* 2012;28(2):85-89.