

# Treatment of Refractory Cerebral Aspergillosis in a Liver Transplant Recipient With Voriconazole: Case Report and Review of the Literature

Thomas Cherian, Alexandros Giakoustidis, Satoshi Yokoyama, Michael Heneghan, John O'Grady, Mohamed Rela, Julia Wendon, D. Nigel Heaton, Anita Verma

## Abstract

**Objectives:** Extension of invasive aspergillosis to the central nervous system is associated with high mortality, in part because of poor central nervous system penetration of antifungal drugs. Voriconazole yields fungicidal drug concentrations within the central nervous system, but use of this drug is limited in liver transplant recipients because of hepatotoxicity and drug interactions.

**Materials and Methods:** We reviewed medical records and antifungal treatment for all liver transplant recipients from 2007 to 2009 who had cerebral aspergillosis (Proven [2]; Probable [1]; Possible [1]) at week 3, 4, 6, and 12 after transplant.

**Case report:** A 33-year-old white man underwent orthotopic liver transplant for acute liver failure that was caused by acetaminophen overdose. Risk factors for fungal infection included major blood loss (8 L), prolonged surgery (9 h), and emergency revision transplant that was done because of nonfunctioning of the primary transplant at 48 hours. He developed postoperative *aspergillus* pneumonia and invasive aspergillosis of the kidneys, brain, and eye. Treatment with voriconazole and amphotericin B was successful, with moderate residual renal impairment.

**Conclusions:** Voriconazole was effective and safe in the treatment of cerebral aspergillosis in this liver transplant recipient.

**Key words:** Infection, Fungal, Central, Nervous, System

## Introduction

Despite a 42% incidence of fungal infection in liver transplant recipients, invasive aspergillosis remains uncommon (1% to 8%).<sup>1-3</sup> The most frequent clinical form is pulmonary aspergillosis but 10% to 25% of all cases of invasive aspergillosis have central nervous system involvement, presumably from hematogenous spread.<sup>1</sup> Despite a 60% overall case-fatality frequency in invasive aspergillosis, central nervous system involvement is associated with a mortality of almost 100%.<sup>4</sup> Poor central nervous system penetration of antifungal drugs traditionally used in invasive aspergillosis, such as amphotericin B, may be responsible for the high mortality.<sup>1, 5-7</sup>

Voriconazole is a triazole that is superior to other antifungal drugs in treating cerebral aspergillosis because it penetrates the blood-brain barrier and yields fungicidal drug concentrations within the central nervous system that exceed inhibitory concentrations required for *Aspergillus* species.<sup>8-11</sup> However, there is reluctance within liver transplant units to use voriconazole in liver transplant recipients because of reported drug interactions with calcineurin inhibitors, immune reconstitution syndromes, and hepatotoxicity in 34% patients that frequently necessitates discontinuation of therapy.<sup>12-15</sup> Evidence for the safety and efficacy of voriconazole in the treatment of refractory cerebral aspergillosis in liver transplant recipients is sparse.<sup>16, 17</sup> This report details the experience of a high volume liver transplant unit

From the Institute of Liver Studies, King's College Hospital, London, UK

**Acknowledgements:** None of the authors have a vested commercial affiliation that could be construed as a conflict of interest with regard to the data or manuscript, and there were no external grants or funds. P. Thomas Cherian and Satoshi Yokoyama performed data collection; P. Thomas Cherian and Alexandros Giakoustidis contributed to manuscript preparation; Michael Heneghan, John O'Grady, and Mohamed Rela helped in conducting the study; Julia Wendon, D. Nigel Heaton, and Anita Verma performed the manuscript review; and Anita Verma supervised the project.

**Corresponding author:** P. Thomas Cherian, Institute of Liver Studies, Kings College Hospital, Denmark Hill, London UK SE5 9RS

**Phone:** +44 203 299 4801 **Fax:** +44 203 299 3575 **E-mail:** [liversurg@live.co.uk](mailto:liversurg@live.co.uk)

*Experimental and Clinical Transplantation* (2012) 5: 482-486

in the use of voriconazole in liver transplant recipients with cerebral aspergillosis > 3 years.

## Materials and Methods

In total, 458 adults underwent liver transplant at the study center from 2007 to 2009, including 71 adults who had acute liver failure. In these 458 liver transplant recipients, there were 4 patients diagnosed with cerebral aspergillosis. Standardized definitions of invasive fungal infections for clinical research European Organization for Research and Treatment of Cancer/National Institute of Allergy and Infectious Diseases Mycoses Study Group (consensus committee) were used to categorize these 4 patients into 3 levels of probability.<sup>18</sup> In 2 patients, invasive fungal infection was confirmed with cytopathology of targeted transcranial needle aspirates that showed classic fungal hyphae, cellular debris, and tissue damage. Four patients each had 1 major clinical criterion used for categorization of possible or probable invasive fungal infection and 1 host factor, and 3 patients each had 1 microbiological criterion; therefore, there was 1 patient with “probable” and 1 with “possible” invasive fungal infection. In this report, only the patient with proven invasive aspergillosis who was treated with voriconazole is presented.

A literature review of all reports on the use of voriconazole in liver transplant recipients with cerebral aspergillosis was done with PubMed/Medline using key words and titles (“invasive aspergillosis,” “aspergillosis,” and “cerebral aspergillosis”), followed by a manual review

of all relevant full text manuscripts (Table 1); search limits included English language, human studies, and publications after 1990.

## Case Report

A 33-year-old white man underwent orthotopic liver transplant for acute liver failure that was caused by acetaminophen overdose. Risk factors for fungal infection included major blood loss (8 L), prolonged surgery (9 h), and emergency revision transplant that was done because of nonfunctioning of the primary transplant at 48 hours. He was started on prophylactic amphotericin B (3 mg/kg/d). On postoperative day 17, a positive culture of *Aspergillus fumigatus* from a bronchoalveolar lavage aspirate confirmed the clinical suspicion of *aspergillus* pneumonia, and voriconazole was started (500 mg IV twice daily, 1 week later reduced to 300 mg twice daily). However, invasive aspergillosis progressed, involving the kidneys and brain, confirmed with computed tomography (Figure 1). On postoperative day 25, he developed *aspergillus* endophthalmitis, chorioretinitis, and orbital edema (Figure 1). On postoperative day 30, he had severe hemoptysis caused by a right pulmonary artery pseudoaneurysm and he was treated with emergency embolization.

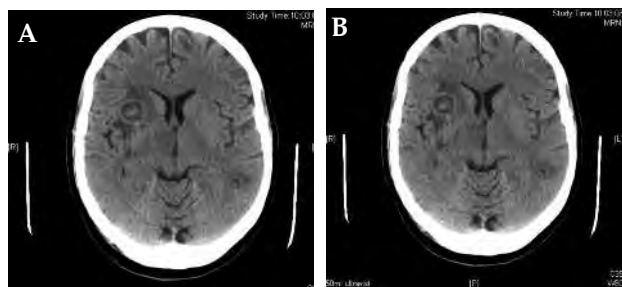
On postoperative day 44, he was discharged from the liver intensive care unit. Both voriconazole and amphotericin B were continued until postoperative day 119, when he was converted to single drug therapy with oral voriconazole (200 mg/d) and discharged from the hospital. Voriconazole was continued for an additional 6 months, and he

**Table 1.** Previous Studies About the Use of Voriconazole in Liver Transplant Recipients With Cerebral Aspergillosis

Study	Number of Patients	Site of Infection	Infection Category	Treatment	Final Outcome	Adverse Events
Leung, et al (2010)	1	Cerebral	Proven <i>Aspergillus fumigatus</i>	Voriconazole, amphotericin B, and caspofungin	Successful	Not specified
Tsitsopoulos, et al (2010)	1	Cerebral	Proven <i>Aspergillus fumigatus</i>	Voriconazole and surgery	Successful	None
Hashemi, et al (2009)	1	Enophthalmic	Proven <i>Aspergillus fumigatus</i>	Voriconazole and enucleation for resistant infection	Successful	Recurrence, resolved with surgery
Kohler, et al (2009)	1	Cerebral, sphenoidal, and pulmonary	Proven <i>Aspergillus fumigatus</i>	Caspofungin and voriconazole (first-line therapy), and amphotericin B and flucytosine	Successful	Not specified

developed a transient episode of acute confusion requiring no treatment during this time. At the most-recent examination 2 years after transplant, he was well with moderate renal impairment, possibly caused by calcineurin inhibitors based on experience that transplant centers have.

**Figure 1.** Computed Tomography Scans



Computed tomography scans in a 33-year-old man after revision orthotopic liver transplant. (A) Characteristic ring enhancing lesions of cerebral aspergillosis with surrounding inflammatory edema. (B) *Aspergillus* chorioretinitis with orbital edema and contrast enhancement.

## Discussion

Immunocompromised patients including liver transplant recipients are at risk for fungal infections despite evidence that inhibitors of calcineurin (tacrolimus) and mammalian target of rapamycin (mTOR) (sirolimus) increase the activity of antifungal agents in vitro.<sup>1</sup> This risk is highest in the immediate postoperative period, and 72% infections occur within the first 30 days (median time to infection, 13-17 d).<sup>19</sup> Aspergillosis most commonly affects the respiratory tract, but in these immunocompromised patients, invasive forms can involve the brain, heart, eyes, and skin.<sup>2,3</sup> Renal dysfunction and revision transplant are major risk factors for invasive aspergillosis.<sup>1</sup> Other risk factors for invasive fungal infection in liver transplant recipients include surgical technical complexity, primary allograft dysfunction, acute cellular rejection, net state of immunosuppression, renal replacement therapy, postoperative bile leak, substantial blood transfusion, *cytomegalovirus* infection, and transplant for acute liver failure.<sup>19-21</sup>

### Voriconazole in invasive aspergillosis

Despite renal toxicity and poor central nervous system penetration, intravenous polyene antifungal drugs such as amphotericin have been used for the treatment of invasive fungal infections, including invasive aspergillosis.<sup>7,8</sup> Echinocandins such as caspofungin have fungistatic activity against *Aspergillus* species,

but the use of these drugs in central nervous system infections is not clear because of poor cerebrospinal fluid penetration. Caspofungin has been approved for empiric therapy in presumed invasive fungal infections in febrile and neutropenic adults.<sup>1,5,22</sup> Of the first generation azole antifungal drugs, fluconazole has good oral absorption and central nervous system penetration but is not effective against *Aspergillus* species.<sup>3,7</sup>

In comparison, many reports since 1997 have noted the efficacy of voriconazole in invasive aspergillosis.<sup>17,23</sup> Two convincing studies were published in 2002 (including a randomized trial that compared amphotericin with voriconazole), which collectively showed improved survival rates and a lower frequency of adverse events with voriconazole compared with amphotericin B, establishing voriconazole as the treatment of choice for invasive aspergillosis.<sup>11,24</sup> Voriconazole is a second-generation triazole, which targets ergosterol biosynthesis, altering cell membrane integrity. The targeted enzyme in the respiratory cycle of the fungi is dependent on cytochrome P450.<sup>2,3,7</sup> Voriconazole is metabolized by the liver, excreted through the kidneys, and has good oral bioavailability, which enables long-term outpatient treatment.<sup>25</sup> An excellent tissue penetration profile enables its use as first-line therapy in treatment of invasive aspergillosis of the lung and bone in addition to cerebral aspergillosis.<sup>26-29</sup>

### Voriconazole for invasive aspergillosis in liver transplant recipients

Three issues arise when using voriconazole in liver transplant recipients. There is a potential interaction between voriconazole and immunosuppressive drugs (cyclosporine, tacrolimus, or sirolimus). In human liver microsomes, voriconazole (4 g/mL) inhibits cytochrome P450 isoenzymes by 50%, demonstrating its potential to increase plasma drug levels at equal dosage, but the pharmacokinetics are nonlinear.<sup>1,10</sup> Moreover, large variation between individuals may occur, despite a fixed dosing regimen of voriconazole, in liver transplant recipients, especially in the presence of liver dysfunction.<sup>30</sup>

The carrier of intravenous voriconazole, which is excreted by the kidneys, may accumulate in patients with impaired creatinine clearance (< 50 mL/min). However, oral administration of voriconazole in patients with moderate to severe renal dysfunction appears safe.<sup>1</sup>

Hepatotoxicity is a potential adverse event with voriconazole. In 1 study, the frequency of hepatotoxicity was 34% in patients on voriconazole, but it was mild and reversible, and there were no cases of liver failure.<sup>12</sup> However, serious adverse events including liver failure and death have been reported.<sup>31, 32</sup> This unpredictable adverse event profile, that includes life-threatening toxicity, has caused reluctance in many liver transplant units to use voriconazole in liver transplant recipients, despite its efficacy.<sup>10, 33</sup>

### Voriconazole for invasive aspergillosis in liver transplant recipients with central nervous system involvement

Central nervous system aspergillosis is a unique circumstance in patients with invasive aspergillosis and is associated with a significantly higher mortality rate. Penetration of drugs across the blood-brain barrier is limited by molecular size, physicochemical properties, and drug interaction with transporter systems such as permeability glycoproteins (P-glycoproteins). Most antifungal agents are large molecules (> 700 Da), which makes sufficient central nervous system penetration difficult, confirmed by low levels of most antifungal agents in cerebrospinal fluid and brain tissue in available studies.<sup>7</sup> In contrast, voriconazole displays central nervous system concentrations that exceed the inhibitory concentrations of *Aspergillus* species, causing improved response and survival rates.<sup>7, 26</sup> Voriconazole achieves cerebrospinal fluid levels that exceed trough plasma levels.<sup>34</sup> Previous studies about the use of voriconazole for cerebral aspergillosis in liver transplant recipients are limited mainly to case reports, despite the potential for clinical efficacy. In the review of the literature, we identified 8 publications (including 5 case reports), all reporting successful outcomes without major adverse effects except for reversible liver dysfunction in 2 reports, not requiring discontinuation of therapy.<sup>21, 35-38</sup>

Three larger studies are available about the use of voriconazole in solid-organ transplant recipients with cerebral aspergillosis, primarily hematopoietic stem cell recipients or patients with hematologic malignancies who require immunosuppression. Information about outcomes and adverse events in liver transplant recipients was difficult to isolate from these studies.<sup>8, 26, 39</sup>

In patients with renal impairment, strict therapeutic drug monitoring is essential to minimize

renal injury.<sup>15</sup> We have decreased voriconazole dosage in half in the presence of major renal impairment, but we have made no changes to the immunosuppressive regimen despite the shared drug metabolism pathways of voriconazole and immunosuppressive drugs. It may be beneficial to maintain specific treatment doses of voriconazole and modulate immunosuppression.

In conclusion, this report shows that invasive aspergillosis is not uncommon despite therapeutic doses of amphotericin and caspofungin in liver transplant recipients. Voriconazole was safe and effective in the treatment of cerebral aspergillosis in this liver transplant recipient, with no evidence of major hepatotoxicity. The limited literature to date reveals no contraindications and similar outcomes. However, continued surveillance for adverse events and careful drug assays are mandatory in this selected patient cohort. Early neurosurgical biopsies or bronchial aspiration may be advisable in patients who present diagnostic difficulties, to prevent treatment delay.

### References

1. Singh N, Paterson DL. Aspergillus infections in transplant recipients. *Clin Microbiol Rev.* 2005;18(1):44-69.
2. Cruciani M, Mengoli C, Malena M, Bosco O, Serpelloni G, Grossi P. Antifungal prophylaxis in liver transplant patients: a systematic review and meta-analysis. *Liver Transpl.* 2006;12(5):850-858.
3. Singh N, Wagener MM, Marino IR, Gayowski T. Trends in invasive fungal infections in liver transplant recipients: correlation with evolution in transplantation practices. *Transplantation.* 2002;73(1):63-67.
4. Lin SJ, Schranz J, Teutsch SM. Aspergillosis case-fatality rate: systematic review of the literature. *Clin Infect Dis.* 2001;32(3):358-366.
5. Fortún J, Martín-Dávila P, Montejo M, et al. Prophylaxis with caspofungin for invasive fungal infections in high-risk liver transplant recipients. *Transplantation.* 2009;87(3):424-435.
6. Patterson TF, Kirkpatrick WR, White M, et al. Invasive aspergillosis. Disease spectrum, treatment practices, and outcomes. I3 Aspergillus Study Group. *Medicine (Baltimore).* 2000;79(4):250-260.
7. Schwartz S, Thiel E. Cerebral aspergillosis: tissue penetration is the key. *Med Mycol.* 2009;47(suppl 1):S387-S393.
8. Schwartz S, Ruhnke M, Ribaud P, et al. Improved outcome in central nervous system aspergillosis, using voriconazole treatment. *Blood.* 2005;106(8):2641-2645.
9. Machetti M, Zotti M, Veroni L, et al. Antigen detection in the diagnosis and management of a patient with probable cerebral aspergillosis treated with voriconazole. *Transplant Infect Dis.* 2000;2(3):140-144.
10. Pemán J, Salavert M, Cantón E, et al. Voriconazole in the management of nosocomial invasive fungal infections. *Ther Clin Risk Manag.* 2006;2(2):129-158.
11. Denning DW, Ribaud P, Milpied N, et al. Efficacy and safety of voriconazole in the treatment of acute invasive aspergillosis. *Clin Infect Dis.* 2002;34(5):563-571.
12. Amigues I, Cohen N, Chung D, et al. Hepatic safety of voriconazole after allogeneic hematopoietic stem cell transplantation. *Biol Blood Marrow Transplant.* 2010;16(1):46-52.

13. Crespo G, Cervera C, Michelena J, Marco F, Moreno A, Navasa M. Immune reconstitution syndrome after voriconazole treatment for cryptococcal meningitis in a liver transplant recipient. *Liver Transpl*. 2008;14(11):1671-1674.
14. Tan K, Brayshaw N, Tomaszewski K, Troke P, Wood N. Investigation of the potential relationships between plasma voriconazole concentrations and visual adverse events or liver function test abnormalities. *J Clin Pharmacol*. 2006;46(2):235-243.
15. Tintillier M, Kirch L, Goffin E, Cuvelier C, Pochet JM. Interaction between voriconazole and tacrolimus in a kidney-transplanted patient. *Nephrol Dial Transplant*. 2005;20(3):664-665.
16. Takeda K, Morioka D, Matsuo K, et al. A case of successful resection after long-term medical treatment of invasive pulmonary aspergillosis following living donor liver transplantation. *Transplant Proc*. 2007;39(10):3505-3508.
17. Mattei D, Mordini N, Lo Nigro C, et al. Voriconazole in the management of invasive aspergillosis in two patients with acute myeloid leukemia undergoing stem cell transplantation. *Bone Marrow Transplant*. 2002;30(12):967-970.
18. Asciglu S, Rex JH, de Pauw B, et al. Defining opportunistic invasive fungal infections in immunocompromised patients with cancer and hematopoietic stem cell transplants: an international consensus. *Clin Infect Dis*. 2002;34(1):7-14.
19. Husain S, Tollemar J, Dominguez EA, et al. Changes in the spectrum and risk factors for invasive candidiasis in liver transplant recipients: prospective, multicenter, case-controlled study. *Transplantation*. 2003;75(12):2023-2029.
20. Fortún J, Martín-Dávila P, Moreno S, et al. Risk factors for invasive aspergillosis in liver transplant recipients. *Liver Transpl*. 2002;8(11):1065-1070.
21. Leung V, Stefanovic A, Sheppard D. Severe cerebral aspergillosis after liver transplant. *Transpl Infect Dis*. 2010;12(1):51-53.
22. Winkler M, Pratschke J, Schulz U, et al. Caspofungin for post solid organ transplant invasive fungal disease: results of a retrospective observational study. *Transpl Infect Dis*. 2010;12(3):230-237.
23. Schwartz S, Milatovic D, Thiel E. Successful treatment of cerebral aspergillosis with a novel triazole (voriconazole) in a patient with acute leukaemia. *Br J Haematol*. 1997;97(3):663-665.
24. Herbrecht R, Denning DW, Patterson TF, et al. Voriconazole versus amphotericin B for primary therapy of invasive aspergillosis. *N Engl J Med*. 2002;347(6):408-415.
25. Johnson LB, Kauffman CA. Voriconazole: a new triazole antifungal agent. *Clin Infect Dis*. 2003;36(5):630-637.
26. Schwartz S, Reisman A, Troke PF. The efficacy of voriconazole in the treatment of 192 fungal central nervous system infections: a retrospective analysis. *Infection*. 2011;39(3):201-210.
27. Thompson GR 3rd, Lewis JS 2nd. Pharmacology and clinical use of voriconazole. *Expert Opin Drug Metab Toxicol*. 2010;6(1):83-94.
28. Mouas H, Lutsar I, Dupont B, et al. Voriconazole for invasive bone aspergillosis: a worldwide experience of 20 cases. *Clin Infect Dis*. 2005;40(8):1141-1147.
29. Jain LR, Denning DW. The efficacy and tolerability of voriconazole in the treatment of chronic cavitary pulmonary aspergillosis. *J Infect*. 2006;52(5):e133-e137.
30. Johnson HJ, Han K, Capitano B, et al. Voriconazole pharmacokinetics in liver transplant recipients. *Antimicrob Agents Chemother*. 2010;54(2):852-859.
31. Scherpbier HJ, Hilhorst MI, Kuijpers TW. Liver failure in a child receiving highly active antiretroviral therapy and voriconazole. *Clin Infect Dis*. 2003;37(6):828-830.
32. Kim SH, Yim DS, Choi SM, et al. Voriconazole-related severe adverse events: clinical application of therapeutic drug monitoring in Korean patients. *Int J Infect Dis*. 2011;15(11):e753-e758.
33. Can MF, Yagci G, Gorenek L, Tozkoparan E, Ozerhan I, Cetiner S. Invasive pulmonary aspergillosis after liver transplantation: rapid and complete response to combined and sequential antifungal therapy. *Surg Infect (Larchmt)*. 2008;9(1):99-104.
34. Scully EP, Baden LR, Katz JT. Fungal brain infections. *Curr Opin Neurol*. 2008;21(3):347-352.
35. Vianna R, Misra V, Fridell JA, Goldman M, Mangus RS, Tector J. Survival after disseminated invasive aspergillosis in a multivisceral transplant recipient. *Transplant Proc*. 2007;39(1):305-307.
36. Tsitsopoulos PP, Tsoulfas G, Tsonidis C, et al. Successful, combined long-term treatment of cerebral aspergillosis in a liver transplant patient. *Virulence*. 2010;1(5):465-467.
37. Hashemi SB, Shishegar M, Nikeghbalian S, et al. Endogenous Aspergillus endophthalmitis occurring after liver transplantation: a case report. *Transplant Proc*. 2009;41(7):2933-2935.
38. Kohler S, Gerlach U, Guckelberger O, et al. Successful treatment of invasive sphenoidal, pulmonary and intracerebral aspergillosis after multivisceral transplantation. *Transpl Int*. 2009;22(5):589-591.
39. Baden LR, Katz JT, Fishman JA, et al. Salvage therapy with voriconazole for invasive fungal infections in patients failing or intolerant to standard antifungal therapy. *Transplantation*. 2003;76(11):1632-1637.