

# Emergency Endovascular Repair in a Patient With Abdominal Aortic Aneurysm With Pelvic Transplant Kidneys: Case Report

Gianluca Smedile,<sup>1</sup> Maria Irene Bellini,<sup>2</sup> Giuseppe Iaria,<sup>2</sup> Tommaso Castrucci,<sup>1</sup> Linda De Luca,<sup>2</sup> Paolo Leporelli,<sup>1</sup> Christopher Booth,<sup>3</sup> Giuseppe Orlando,<sup>3,4</sup> Giuseppe Tisone<sup>2</sup>

## Abstract

**Abdominal aortic aneurysms after a kidney transplant are becoming treated more frequently owing to the extension of renal transplant in severely arteriosclerotic older patients. Renal transplant recipients with autosomal dominant polycystic kidney disease are prone to develop abdominal aortic aneurysms. We present the case of a ruptured abdominal aortic aneurysm that occurred in a renal transplant patient with autosomal dominant polycystic kidney disease. The patient was treated with emergency endovascular repair because open surgery could not be performed successfully owing to the presence of massive polycystic native kidneys and a liver that was occupying the entire peritoneal cavity. His postoperative course was uneventful without complications. The important lessons to be learned from our case are 2-fold: (1) Autosomal dominant polycystic kidney disease renal transplant recipients should be screened annually for abdominal aortic aneurysms to prevent ruptures and (2), emergency endovascular repair may be a preferred treatment in renal transplant recipients owing to its low surgical risk and success.**

**Key words:** *Abdominal aortic aneurysms, Autosomal dominant polycystic kidney disease, Emergency endovascular repair, Pelvic transplant kidneys, Renal transplant*

*From the Department of<sup>1</sup>Vascular Surgery, Sant'Eugenio Hospital; the<sup>2</sup>General and Transplant Surgery Unit, University of Rome Tor Vergata, Rome, Italy; the<sup>3</sup>Wake Forest Institute for Regenerative Medicine; and the Department of<sup>4</sup>General Surgery, Wake Forest University School of Medicine, Winston Salem, NC, USA*

*Corresponding author: Maria Irene Bellini, MD, Piazzale dell'Umanesimo n.10, 00144 Rome, Italy*

*Phone: +39 340 721 1074 Fax: +39 06 5922681 E-mail: irene\_bellini@alice.it*

*Experimental and Clinical Transplantation (2012) 6: 601-604*

## Introduction

Autosomal dominant polycystic kidney disease (ADPKD) is a common, slowly progressive hereditary disorder that usually leads to end-stage renal disease.<sup>1,2</sup> The crucial pathogenic mechanism behind ADPKD is the excessive proliferation of renal epithelial cells that replace most of the functional tissue. This replacement eventually results in enlargement of the kidneys and ultimately, in renal failure. In ADPKD, the kidney tubules also secrete higher levels of matrix metalloproteinase, whose function is to cleave the constituents of the extracellular matrix. Autosomal dominant polycystic kidney disease patients therefore are prone to develop vascular cerebral aneurysms and abdominal aortic aneurysms (AAA). The aneurysms develop after the breakdown of the extracellular matrix owing to excessive proteolytic activity by matrix metalloproteinase, which leads to potential arterial wall ruptures.<sup>3-5</sup>

In abdominal and heart transplant patients, AAA expand more rapidly than in nontransplant individuals for reasons that are unclear.<sup>6</sup> Consequently, transplant patients show higher rates of AAA ruptures, which carry a high risk of death for 2 reasons: (1) the impairment of the immune surveillance deriving from life-long immunosuppression (which significantly increases preoperative morbidity and mortality) and (2); the risk for surgery-related ischemic injury to the renal graft owing to a solitary arterial supply and lack of collateral circulation.<sup>7</sup> When rupture does occur, emergency surgery should aim not only at providing effective aortic replacement but also, at minimizing ischemic damage to avoid deterioration of renal function and graft loss. To reduce the ischemic time of the renal graft in course of open surgery (namely,

the traditional approach), several methods have been described. For example, the use of temporary shunts, extracorporeal circulation, and local or general hypothermia are performed methods; however, the effectiveness of these procedures remains questionable. In fact, a recent survey of the literature shows that AAA repair in renal transplant recipients can be safely undertaken without protection of the transplanted kidney.<sup>8</sup>

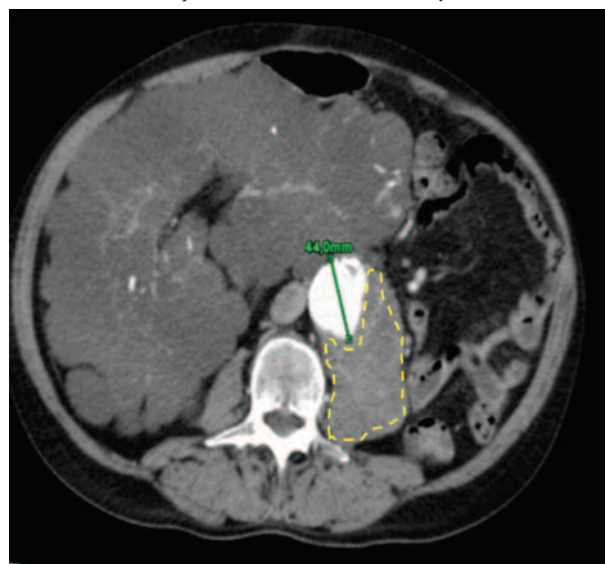
Possible surgical approaches done in this setting are open and endovascular (EVAR). In renal transplant recipients with AAA, open surgery remains the treatment of choice; however, EVAR may represent the optimal treatment in patients who do not present any contraindications to the endoscopic approach.<sup>8</sup> Here, we report the case of successful endoscopic treatment of a ruptured AAA that occurred in a kidney transplant recipient who had received a transplant for ADPKD-related end-stage renal disease.

### Materials and Methods

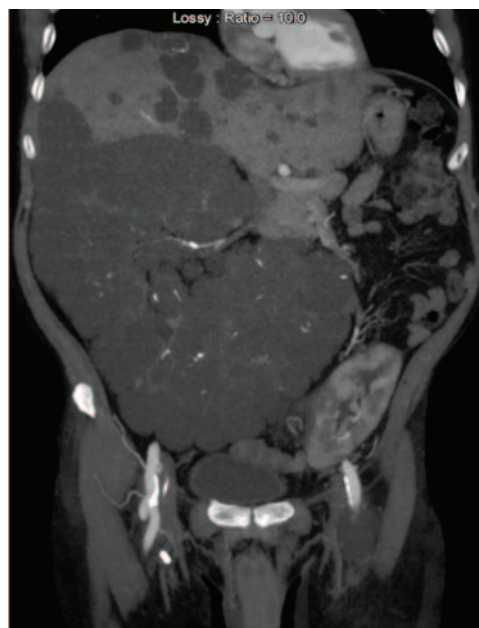
A 59-year-old man was referred to our unit for abdominal pain, hypothermia of his left lower limb, and acute renal failure (creatinine 353.6  $\mu\text{mol/L}$ , urea 38.55  $\text{mmol/L}$ ). The patient had received a deceased donor renal graft 3 years earlier, which was followed by immediate normalization of his renal function test results. During the 3-year follow-up, the patient was healthy, with no complications while regularly seen at the outpatient clinic.

Color-Doppler ultrasound of the kidney graft did not show any pathological findings; however, the presence of a previously unknown 4.5-cm long AAA was detected, which was confirmed by a subsequent computed tomography (CT) scan (Figure 1). The CT scan also showed a retroperitoneal hematoma involving the psoas muscle on the same side of the graft, while communicating with the AAA. Moreover, there was a large polycystic liver associated with native polycystic kidneys that occupied the entire peritoneal cavity (Figure 2). During hospitalization, the patient's blood pressure and heart rate remained stable within normal values, while his serum creatinine increased to 39 072.8  $\mu\text{mol/L}$ . The lower left limb became ischemic while no abnormality was observed in the contralateral limb. Importantly, there was no previous intermittent claudication or other signs of

**Figure 1.** CT Scan Showing the 4.4-cm Infrarenal Abdominal Aortic Aneurysm Associated with Retroperitoneal Hematoma (Shown By Yellow Line)



**Figure 2.** A Coronal Plane CT Scan Showing an Enlarged Right, Native Kidney That Precluded an Open Laparotomic Approach



lower limb ischemia reported by the patient. Emergency treatment was required because of the indication of signs of a ruptured AAA, rapidly deteriorating renal graft function, and limb ischemia that were represented by a hematoma in the posterior region of the aorta.

Based on imaging, open surgery was considered to be of high risk owing to (1) the challenge of preserving the transplanted kidney; (2) the presence of massive cystic organs and (3); adhesions and altered anatomy.<sup>9,10</sup> Overall, a retroperitoneal approach to the abdominal aorta was not possible

owing to the presence of a para-aortic hematoma and preserving the transplanted kidney. Therefore, we opted for an endovascular approach that presented a better platform for treatment.

Treatment of the AAA was approached with a bilateral femoral incision using local anaesthesia.<sup>11</sup> Antibacterial prophylaxis was achieved via 1 injection of intravenous antibiotics. The main aortic graft (AneuRx, Medtronic, Inc., Minneapolis, MN, USA) was placed between the origin of the superior mesenteric artery, cranially, and the site of the anastomosis, between the artery of the renal graft and the common iliac artery of the recipient, caudally (Figure 3). We then removed the introducer sheath to obtain antegrade perfusion of the transplanted kidney and positioned the opposite branch on the right side. Angiographic control showed appropriate blood flow without leaks, through the endo-prosthesis, while maintaining proper perfusion of the renal graft.

His postoperative course was uneventful, and he was discharged 4 days after surgery. A control CT scan confirmed correct positioning of the endo-

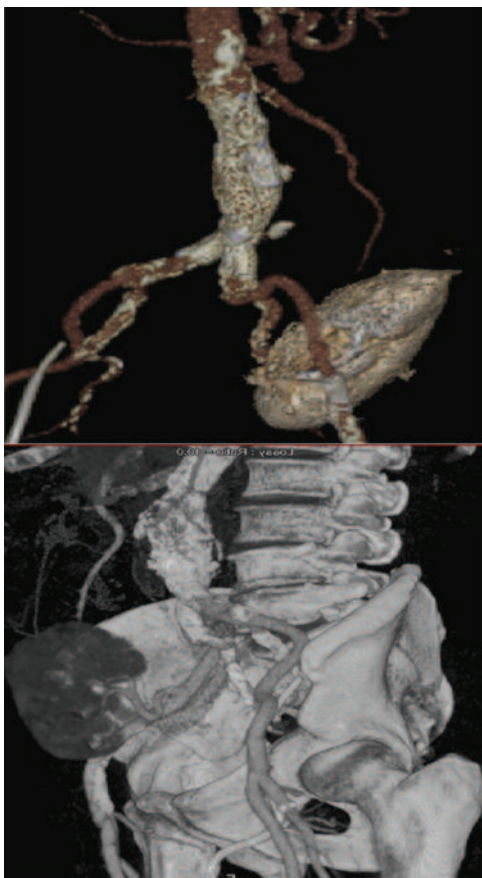prosthesis, complete hematoma exclusion, and complete perfusion of the transplanted kidney. Renal support was necessary only during the first week after the procedure, after which renal function progressively improved. Six months after treatment, the patient was in a good general health with serum creatinine level of 176.8  $\mu\text{mol/L}$ .

## Discussion

Invasive open surgery is the typical treatment for an AAA; however, in kidney transplant recipients, it is still debated whether or not EVAR should be preferred to the open approach. Emergency endovascular repair has the theoretical advantage of minimizing interruption of the blood flow within the artery of the renal allograft, whose ischemic time is limited to the time that the aortic graft is ballooned into place.<sup>7</sup> Moreover, further potential advantages of EVAR include selecting the side for the main body deployment of the aortic graft,<sup>12</sup> and a significant reduction in surgical stress on the patient when compared to open surgery.<sup>8</sup> On the other hand, EVAR requires injection of contrast media, which may stimulate contrast-induced nephropathy, especially if the renal functional reserve is limited (as can occur in renal transplant recipients). Thrombosis or embolization of the renal allograft artery from debris detached from the AAA sac<sup>12,13</sup> also may complicate EVAR procedures. In our case, open surgery was not a practical or optimal option because median and retroperitoneal approaches were not feasible for the above-mentioned reasons; thus, EVAR became mandatory.

Renal transplant patients affected by ADPKD deserve annual AAA screenings to prevent rupture and emergency surgery. Abdominal aortic aneurysms with a diameter greater than 5.5 cm represent the cutoff value, above which, AAA repair becomes mandatory. All attempts to repair smaller AAA through an endoscopic approach in fit patients, do not seem to have any effect on the overall outcome. This idea also has been proposed by others regarding renal transplant patients tout court.<sup>14</sup> The role of matrix metalloproteinases in the progression of AAA has, in fact, been demonstrated in animal models and clinical studies.<sup>3</sup> It also is well known that an association between ADPKD and AAA exists; however, no precise data regarding its actual incidence have been determined, with only rare cases

**Figure 3.** 3-Dimensional CT Scan Showing the Prosthesis Positioned to Preserve Kidney Vascolarization



reported in the literature.<sup>5,15-18</sup> For example, Lacombe reported a series of 18 kidney transplant recipients with AAA who were treated with aortic open surgery with only 1 of them was affected by ADPKD.<sup>19</sup>

## Conclusions

This case study provides the necessary evidence to understand the importance of alternative emergency surgical procedures for treating AAA in patients displaying the risk of open surgery. We also show the importance of annual screenings for AAA in patients with ADPKD who have undergone renal transplant surgery to prevent the need for emergency surgery owing to a rupture. The EVAR procedure provides an equally successful treatment option for AAA in susceptible patients without the risk that is involved with the other treatment options in these situations.

## References

1. Walz G, Budde K, Manna M, et al. Everolimus in patients with autosomal dominant polycystic kidney disease. *N Engl J Med*. 2010;363(9):830-840. Erratum in: *N Engl J Med*. 2010;363(12):1190. *N Engl J Med*. 2010;363(20):1977.
2. Shillingford JM, Murcia NS, Larson CH, et al. The mTOR pathway is regulated by polycystin-1, and its inhibition reverses renal cystogenesis in polycystic kidney disease. *Proc Natl Acad Sci U S A*. 2006;103(14):5466-5471.
3. Michel JB, Martin-Ventura JL, Egido J, et al. Novel aspects of the pathogenesis of aneurysms of the abdominal aorta in humans. *Cardiovasc Res*. 2011;90(1):18-27.
4. Weintraub NL. Understanding abdominal aortic aneurysm. *N Engl J Med*. 2009;361(11):1114-1116.
5. Torra R, Nicolau C, Badenas C, et al. Abdominal aortic aneurysms and autosomal dominant polycystic kidney disease. *J Am Soc Nephrol*. 1996;7(11):2483-2486.
6. Englesbe MJ, Wu AH, Clowes AW, Zierler RE. The prevalence and natural history of aortic aneurysms in heart and abdominal organ transplant patients. *J Vasc Surg*. 2003;37(1):27-31.
7. Kim HK, Ryuk JP, Choi HH, Kwon SH, Huh S. Abdominal aortic aneurysm repair in patient with a renal allograft: a case report. *J Korean Med Sci*. 2009;24(1):166-169.
8. Sadat U, Huguet EL, Varty K. Abdominal aortic aneurysm surgery in renal, cardiac and hepatic transplant recipients. *Eur J Vasc Endovasc Surg*. 2010;40(4):443-449.
9. Reber PU, Vogt B, Steinke TM, Patel AG, Knimeyer HW. Surgery for aortoiliac aneurysms in kidney transplant recipients. *J Cardiovasc Surg (Torino)*. 2000;41(6):919-925.
10. Martin-Conejero A, Serrano-Hernando FJ, Reina-Gutierrez T, Rial-Horcajo R, Ponce-Cano AI, Blanco-Cañibano E. Surgery for aortoiliac aneurysm after kidney transplant. *Transplant Proc*. 2003;35(8):2953-2957.
11. George P, Tan HP, Beebe H, Ratner LE. Successful renal transplantation after endovascular bifurcated stent graft repair of an abdominal aortic aneurysm. *Transplantation*. 2001;72(3):533-534.
12. Gallagher KA, Ravin RA, Schweitzer E, Stern T, Bartlett ST. Outcomes and timing of aortic surgery in renal transplant patients. *Ann Vasc Surg*. 2011;25(4):448-453.
13. Agle SC, Barchman MJ, Haisch CE, Stoner MC. Aortoiliac intervention with distal protection to salvage a heterotopic renal transplant. *Ren Fail*. 2009;31(7):593-596.
14. Favi E, Citterio F, Tondolo V, et al. Abdominal aortic aneurysm in renal transplant recipients. *Transplant Proc*. 2005;37(6):2488-2490.
15. Hughes JD, Milfeld DJ, Shield CF 3rd. Renal transplant perfusion during aortoiliac aneurysmectomy. *J Vasc Surg*. 1985;2(4):600-602.
16. Meijer E, de Jong PE, Peters DJ, Gansevoort RT. Better understanding of ADPKD results in potential new treatment options: ready for the cure? *J Nephrol*. 2008;21(2):133-138.
17. Matia I, Adamec M, Varga M, Janousek L, Lipar K, Viklicky O. Aortoiliac reconstruction with allograft and kidney transplantation as a one-stage procedure: long term results. *Eur J Vasc Endovasc Surg*. 2008;35(3):353-357.
18. Goeau-Brissonniere O, Renier JF, Bacourt F. Abdominal aortic aneurysm associated with aortic hypoplasia and polycystic kidneys. *J Vasc Surg*. 1990;12(4):504-505.
19. Lacombe M. Surgical treatment of aortoiliac aneurysms in renal transplant patients. *J Vasc Surg*. 2008;48(2):291-295.