

Endovascular Treatment of Intracranial Aneurysms with Flow Diverter Stents

İntrakraniyal Anevrizmaların Akım Düzenleyici Stentler ile Endovasküler Tedavisi

Behlül İğüs¹®, Hakan Selçuk²®, Batuhan Kara²®, Ali Fırat¹®, Aysun Erbahçeci Salık²®

¹ Baskent University Istanbul Hospital, Department of Radiology, Istanbul, Turkey

² Bakirkoy Dr. Sadi Konuk Training and Research Hospital, Department of Radiology, Istanbul, Turkey

Received: 12 February 2020 / Accepted: 20 February 2020 / Publication date: 26 March 2020

Cite as: İğüs B, Selçuk H, Kara B, Fırat A, Erbahçeci Salık A. Endovascular treatment of intracranial aneurysms with flow diverter stents. Med J Bakirkoy 2020;16(1):9-14.

ABSTRACT

Objective: We aimed to present the treatment and follow-up results of 41 patients who were treated for intracranial aneurysm with flow diverter stents.

Method: Forty-one patients (Age range 27-68 years) were treated with the flow-diverting devices during January 2010 and January 2014. Aneurysms ranged in size from small to large (1-30 mm) and include wide-necked aneurysms, multiple, saccular, blister, dissecan, fusiform and recurrent intracranial aneurysms. Control skull X-Ray Graphy was typically performed at 1, 3 and 6 months after treatment. A follow-up digital subtraction angiogram (DSA) was performed first day, 6 and 12 months after treatment.

Conclusions: Complete angiographic occlusion was achieved in 36 patients (88%) at follow-up digital subtraction angiogram. Two transient morbidities and one permanent morbidity occurred due to stent thrombosis. There was no mortality observed. Flow diverter stents are an effective tool in the treatment of large wide neck, high growth rates, and technical problematic aneurysms to treat with conventional endovascular methods.

Keywords: intracranial aneurysm, endovascular treatment, flow-diverter stenting

Öz

Amaç: Akım düzenleyici stentler yardımıyla intrakraniyal anevrizma tedavisi yapılan 41 hastanın tedavi ve erken dönem takip sonuçlarını sunmayı amaçladık.

Yöntem: Ocak 2010 ile Ocak 2014 arasında yaş aralığı 27-68 arasında değişen 41 intrakraniyal anevrizmalı hasta akım düzenleyici stent ile tedavileri yapıldı. Anevrizma boyutları küçük ve büyük (Aralık, 1-30 mm) olmak üzere geniş boyunlu, sakküler, fuziform, blister, dissekan ve rekürrens gösteren anevrizmaları içermektedir. Tüm hastalar işlemden sonraki 1, 3 ve 6. ayında direkt kafa grafileri ve tedavinin 1. günü, 6 ve 12. ayında kontrol dijital subtraksiyon anjiyografi (DSA) incelemeleri yapılarak takip edildi.

Sonuçlar: Tedavi sonrası kontrol DSA' da 36 (%88) hastada anevrizma kesesinde tam oklüzyon izlendi. Komplikasyon olarak stent trombozuna bağlı iki hastada geçici morbitide ve bir hastada kalıcı morbitide izlendi. Mortalite izlenmedi. Akım düzenleyici stentler geniş boyunlu, yüksek büyüme oranları bulunan ve teknik problemler nedeniyle endovasküler tedavisi kısıtlı olan anevrizmaların tedavisinde etkili bir araçtır.

Anahtar kelimeler: intrakraniyal anevrizma, endovasküler tedavi, akım düzenleyici stent

Corresponding Author:

✉ dr.bigus@gmail.com

B. İğüs 0000-0003-4874-8141

H. Selçuk 0000-0001-5606-4423

B. Kara 0000-0002-4179-4324

A. Fırat 0000-0003-3296-7227

A. Erbahçeci Salık 0000-0001-5344-560X



INTRODUCTION

Intracranial aneurysms which are the most frequently seen non-traumatic causes of subarachnoid hemorrhage (SAH) observed in 3.7% of retrospectively and 6% of prospectively designed angiography studies ⁽¹⁾. Although surgical clipping is widely used in the treatment of intracranial aneurysms, endovascular approaches provide a proper and effective alternative treatment method to surgical treatment by protecting the patient from the risks of major surgery by occluding or thrombosing the lumen of aneurysm with various techniques. Coil embolization is the most frequently used method in the endovascular treatment of intracranial aneurysms but harbours some limitations.

These limitations are mainly observed in wide-necked aneurysms, and migration of the coils to the parent artery and recanalization in the aneurysm sac after the treatment are seen ⁽²⁾. Although balloon modeling, stenting and coiling methods are effective in dealing with these difficulties, treatment with the help of flow-diverter (FD) stents is the new alternative in such selected cases ⁽³⁾. The aim of this study was to evaluate the early results of the reliability and efficacy of the intracranial aneurysms using FD stents.

MATERIAL and METHOD

Between January 2010 and January 2014, 41 patients with intracranial aneurysms who applied to the Interventional Neuroradiology Department with treated using a FD stents (Balt Extrusion, Montmorency, France). Our study was approved by the Ethics Committee of our Hospital on 03.31.2014 with the project number no. 2014-60 as a dissertation study. Our study population consisted of 31 (67%) female and 13 (23%) male patient with a mean age of 47.8 ± 1.2 years (range: 27-68 years). Ten (24%) patients applied to us two weeks before our treatment with a history of SAH and 3 patients (7%) with mass effect-related symptoms.

Among twenty asymptomatic patients (48%), aneurysm was detected incidentally using computed tomography or magnetic resonance imaging techniques requested with the indication of nonspecific

complaints (mostly headache). The remaining 8 (19%) patients presented with enlargement of their aneurysms after treatment by surgical or endovascular methods.

Indications for treatment with FD stents are as follows; arterial fusiform or saccular aneurysms, giant aneurysm or aneurysms with mass effect, wide-necked aneurysms, blister-type aneurysms, small (<2 mm) aneurysms that cannot be treated with surgery or conventional endovascular treatment techniques and enlarged aneurysms developed after endovascular or surgical treatment were included in the treatment.

The mean aneurysm size was $14,3 \pm 1,4$ mm (range, 1-30 mm). The aneurysms were located at the parophthalmic segment in 30 patients, at the posterior communicating artery in 8 patients and at the anterior choroidal artery in 2 patients.

RESULTS

Technically, FD stent was successfully placed in 41 patients. In the DSA (Digital subtraction angiography) examination of the patient whose clinical picture worsened 2 hours after the procedure, the stent lumen occluded with thrombus was observed. The complete patency of the stent lumen was achieved by passing a microcatheter through the occluded lumen, and application of antiplatelet glycoprotein IIb / IIIa blocker, Tirofiban (Aggrastat) was performed. Neurological deficit was not observed in the patient after the treatment.

On the first day control DSA review, patient had thrombotic occlusion of the right ICA (Internal Carotid Artery) and stent lumen was observed and the filling of the right hemisphere was compensated with anterior and posterior communicating arteries from left ICA and posterior circulation. Upon normal neurological examination of the patient, the patient was included in the routine follow-up protocol.

The patient, who was treated with FD stent due to parophthalmic aneurysm of the left ICA, did not wake up from postprocedural anesthesia (Figure 1A-B). Thus, control DSA was performed which revealed thrombotic occlusion of the stent lumen (Figure 1C).

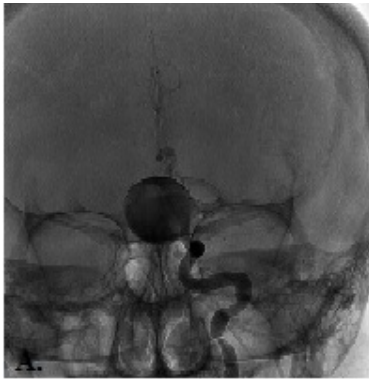


Figure 1A. On DSA, left ica paroftalmik giant aneurysm was showed.

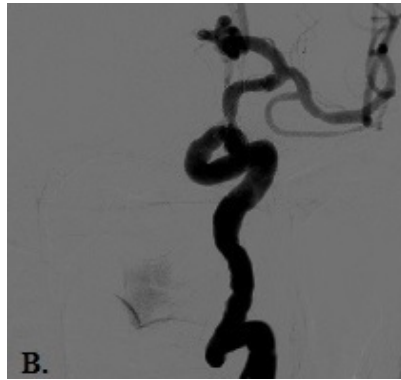

Figure B. After Deployment of Flow-diverter stent, thrombosed aneurysm was showed.

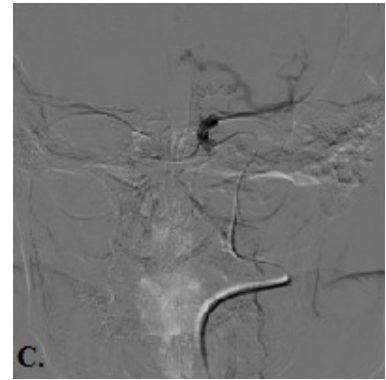


Figure 1C. On first day control DSA, Thrombotic occlusion of a FD stent was showed.

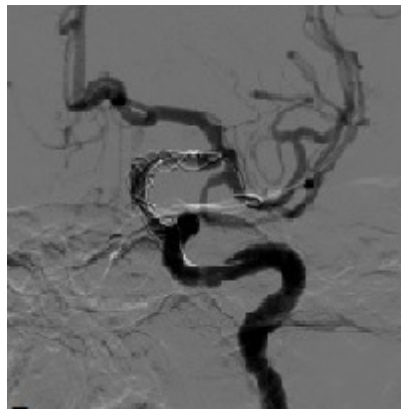


Figure 1D. Intraarterial thrombolysis was applied and a second stent was inserted through the lumen of the stent to achieve stent patency.

Then intraarterial thrombolysis was applied and a second stent was inserted through the lumen of the stent to achieve stent patency (Figure 1D). Neurological deficit was not detected in during post-treatment control of the patient.

In the patient, who has a history of surgical treatment due to a bleeding basilar tip aneurysm, 50% collapse at the proximal end of the stent was observed in the control DSA performed one day after parophthalmic aneurysm of the left ICA was treated with an FD stent. This situation was handled with passing through the collapsed segment of the stent with a micro guidewire, the PTA procedure was performed and the apposition of the stent to the vascular wall was ensured.

Control DSA examination performed on the patient due to speech disorder and hemiparesis developed one day after the treatment, the MCA (Middle Cerebral

Artery) M1 segment was found to be thrombosed starting from the distal of the stent. Occlusion of the lumen of both the stent and the artery were completely relieved as a result of mechanical thrombectomy and intraarterial Aggrastat application after negotiating of microcatheter at the thrombosed segment of the stent and MCA. Neurological deficit occurred in the patient secondary to extensive MCA infarction as detected during the control MRI examination.

The patient treated with FD stent due to left posterior communicating artery (PCoA) aneurysm on the follow up patients was re-treated using a second FD stent because of persistent filling of the aneurysm neck as observed in the control DSAs performed in the 6th and 12th months. After the second FD stent was performed, there were no filling detected in the aneurysm during follow-up examinations.

In our study, in 5 patients (12%) who were treated with FD stents, the filling of the neck of the aneurysm continued as observed in the 1st year control in DSA examinations.

DISCUSSION

Flow-diverter stents; can be used as a new option in the treatment of dissecan, fusiform, blister, wide-neck and recurrent aneurysms. The purpose of this treatment is interrupt the blood flow in the aneurysm sac and to activate the thrombosis with its flow-regulating effects. In our patient group, 88% (36/41) total occlusion in the aneurysm sac was determined in the 1st year control DSA. Also, FD stents present some specific problems in treatment. First of all, when using such materials, we encounter stent placement difficulties. In their multicenter prospective study, Byrne et al. reported procedural difficulties in 29% (n=20) their patients. These procedural difficulties are mainly; inadequate stenting in 12, inappropriate stent placement in 4, stent migration in 4, and partial, and complete thrombosis of the parent artery in 7 patients⁽⁴⁾.

In our study, we encountered stent placement problems in a total of 4 (9.7%) patients. On the first day of control DSA, 50% collapse (2.4%) in the proximal end of the stent in 1 and stent thrombosis in 4 (9.7%) patients were observed. The vascular structure of patients complicates stent placement especially in tortuous vessels. Most of the stent placement difficulties occurred in our first case series. Accumulating experience, and information about features of the stent, and the most accurate selection of stent size is important in overcoming stent placement difficulties. When choosing the stent size, if there is a difference between the diameters of the proximal and distal parts of a artery, a stent diameter should be selected. proximal site of the artery.

When placing the stent complete apposition of the proximal end of the stent to the artery is important. In cases where the complete apposition of the FD stent to the artery can not be achieved collapse and thrombosis of the stent can be occurred due to changes induced by FD stent-related flow⁽⁵⁾. In addition, these stents have low radial forces, so a slight collapse or insufficient opening of the distal tip can be

observed when loading the stent. In cases where the distal tip of the stent does not open adequately, then distal tip patency can be provided with the help of a balloon angioplasty. As in studies with other flow-diverter stents, the probability of occlusion of the aneurysm after treatment increases over time, but the development is unpredictable^(6,7).

In small series such as our study, it is difficult to determine the timing of aneurysm occlusion. Dual antiplatelet drug treatment for at least 4 months, sometimes even longer due to partial stenosis or thromboembolic events in the stent lumen increases this uncertainty.

Recurrence in aneurysm is an important problem, especially in patients undergoing coil embolization. In the literature, recurrence rates between 13% and 34% have been reported in large series after endovascular treatment^(8,9). In our study, residual neck filling was observed in aneurysms of 5 (12%) patients.

Blister-type aneurysms are difficult to treat with both surgical methods and classical endovascular methods due to their weak walls, small sizes and large necks, and atypical locations. These aneurysms have a high risk of rupture during surgery⁽¹⁰⁾. Thus, they have high morbidity and mortality rates. In our study, three of our patients with a history of subarachnoid hemorrhage caused by rupture of the blister aneurysm were treated with FD stents. These patients were treated 2 weeks after bleeding to rule out possible SAH-related complications. Any complications were not observed in the post-procedural follow-up of the patients, and occlusion of the aneurysm sacs were observed in the 1st year control DSA examinations.

Kulesar et al. treated a patient with a FD stent who had SAH due to rupture of aneurysm 20 days previously⁽¹¹⁾. Another study conducted by Byrne et al. treated four of 10 ruptured aneurysms with FD stents within the first 30 days of SAH⁽⁴⁾. In addition, studies on the use of FD stents in ruptured aneurysms have been reported⁽¹²⁾. In our cases, 10 ruptured aneurysms were treated with FD stents 2 weeks after SAH. The main concern with the use of FD stents in ruptured aneurysms is the complications

associated with the use of dual antiplatelet drug therapy and the uncertainty of aneurysm occlusion time after treatment.

After the treatment of the ruptured aneurysms mentioned in the above studies with FD stent, no rebleeding occurred in any case, but other options should be carefully considered before using flow-diverter stents in ruptured aneurysms.

Intracranial hemorrhage can be observed after successful treatment with flow-diverter stents. Byrne et al. had reported a ruptured case 7 months after the treatment⁽⁴⁾. Furthermore, Lubicz et al. reported a ruptured case secondary to the migration of the stent into the aneurysm sac 13 days after the treatment⁽¹³⁾.

Although the mechanism of bleeding after treatment with FDstents is not fully known, the formation of new and organized luminal thrombosis is an important risk factor that causes deterioration in the aneurysm wall structure and has been associated with aneurysm rupture. Kulcsár et al. reported that main features of ruptured aneurysms after treatment with FD stents⁽¹⁴⁾. Accordingly, large and giant aneurysms, symptomatic aneurysms recently showing growth and wall instability, saccular aneurysms with a dome / neck ratio greater than 1.6 have been reported to have significantly higher risk of rupture. Cebal et al. reported that flow –diverter stents can be increase the intracranial pressure which may cause rupture especially in large and giant aneurysms⁽¹⁵⁾.

In our patient group, there were no bleeding complications observed since we performed coil embolization combining with FD stent in patients with parenchyma- embedded aneurysms

CONCLUSION

Our aim in this retrospective study is to focus on the technical difficulties encountered when using FD stents, and we wanted to share our experience about the complications of treatment. Although this treatment has its own technical difficulties, and complications in the early and mid-term follow-up. FD stents have been discovered to be promising,

especially for morphologically difficult aneurysms. With long-term follow-up monitoring, conducting further studies on the hemodynamic effects and healing reactions of this treatment will increase our knowledge.

In the literature, bleeding rates after treatment have been observed in large diameter and when the aneurysm is embedded in the parenchyma. In our study, the use of FD stents with coil embolization in large diameter and parenchyma-embedded aneurysms is an important finding in our study. Another important detail is the first-day DSA should be performed. In cases where the stent patency is insufficient as revealed in the DSA performed on the 1st day after the treatment, the placement of the stent into the artery has been successfully achieved with the balloon angioplasty method and provides early intervention to thromboembolic events that may occur.

In conclusion, FD stent is an effective treatment tool for the most challenging wide-necked, giant, blister, dissecting and fusiform aneurysms, despite all FD insertion difficulties. This method will improve our major therapeutic approaches in the treatment of complex aneurysms in the future.

Ethics Committee Approval: Bakırköy Dr. Approval was obtained from the Sadi Konuk Training and Research Hospital Clinical Research Ethics Committee (2014/60).

Conflict of Interest: The author declares that he has no conflict of interest.

Funding: No financial support was received.

Informed Consent: Informed consent was not obtained since the study is retrospective.

REFERENCES

1. Rinkel GJ, Djibuti M, Algra A, van Gijn J. Prevalence and risk of rupture of intracranial aneurysms: a systematic review. *Stroke*. 1998;29(1):251-6. <https://doi.org/10.1161/01.STR.29.1.251>
2. Agnoletto GJ, Meyers PM, Coon A, Kan PTM, Wakhloo AK, Hanel RA. A contemporary review of endovascular treatment of wide-neck large and giant aneurysms. *World Neurosurg*. 2019;130:523-9.e2. <https://doi.org/10.1016/j.wneu.2019.06.201>
3. Spiotta AM, Miranpuri A, Hawk H, Chaudry MI, Turk AS, Turner RD. Balloon remodeling for aneurysm coil embolization with the coaxial lumen Scepter C balloon catheter: initial experience at a high volume center. *J Neurointerv Surg*. 2013;5(6):582-5. <https://doi.org/10.1136/neurintsurg-2012-010552>

4. Byrne JV, Beltechi R, Yarnold JA, Birks J, Kamran M. Early experience in the treatment of intracranial aneurysms by endovascular flow diversion: Multicentre Prospective Study. *PLoS One* 2010;2:5(9).
<https://doi.org/10.1371/journal.pone.0012492>
5. Aurboonyawat T, Blanc R, Schmidt P, et al. An in vitro study of Silk stent morphology. *Neuroradiology*. 2011;53(9):659-67.
<https://doi.org/10.1007/s00234-010-0784-4>
6. Szikora I, Berentei Z, Kulcsar Z, Marosfoi M, Vajda ZS, Lee W, Berez A, Nelson PK. Treatment of intracranial aneurysms by functional reconstruction of the parent artery: the Budapest experience with the pipeline embolization device. *AJNR Am J Neuroradiol*. 2010;31(6):1139-47.
<https://doi.org/10.3174/ajnr.A2023>
7. Lylyk P, Miranda C, Ceratlo R, et al. Curative endovascular reconstruction of cerebral aneurysms with the pipeline embolization device: the Buenos Aires experience. *Neurosurgery*. 2009;64(4):632-42.
<https://doi.org/10.1227/01.NEU.0000339109.98070.65>
8. Molyneux AJ, Kerr RS, Yu LM, Clarke M, Sneade M, Yarnold JA, et al. International subarachnoid aneurysm trial (ISAT) of neurosurgical clipping versus endovascular coiling in 2143 patients with ruptured intracranial aneurysms: a randomised comparison of effects on survival, dependency, seizures, rebleeding, subgroups, and aneurysm occlusion. *Lancet*. 2005;366(9488):809-17.
[https://doi.org/10.1016/S0140-6736\(05\)67214-5](https://doi.org/10.1016/S0140-6736(05)67214-5)
9. Cognard C, Weill A, Spelle L, Piotin M, Castaing L, Rey A, et al. Long-term angiographic follow-up of 169 intracranial berry aneurysms occluded with detachable coils. *Radiology* 1999;212:348-56.
<https://doi.org/10.1148/radiology.212.2.r99jl47348>
10. Meling TR, Sorteberg A, Bakke SJ, et al. Blood blister like aneurysms of the internal carotid artery trunk causing subarachnoid hemorrhage; treatment and outcome. *Neurosurgery*. 2008;108:662-71.
<https://doi.org/10.3171/JNS/2008/108/4/0662>
11. Kulcsár Z, Ernemann U, Wetzel SG, et al. High-profile flow diverter (silk) implantation in the basilar artery: efficacy in the treatment of aneurysms and the role of the perforators. *Stroke*. 2010;41(8):1690-6.
<https://doi.org/10.1161/STROKEAHA.110.580308>
12. Kulcsár Z, Wetzel SG, Augsburg L, Gruber A, Wanke I, Rufenacht DA. Effect of flow diversion treatment on very small ruptured aneurysms. *Neurosurgery* 2010;67:789-793
<https://doi.org/10.1227/01.NEU.0000372920.39101.55>
13. Lubicz B, Collignon L, Raphaeli G, Pruvo JP, Bruneau M, De Witte O, et al. Flow-diverter stent for the endovascular treatment of intracranial aneurysms. A Prospective Study in 29 patients with 34 aneurysms. *Stroke* 2010;41:2247-53.
<https://doi.org/10.1161/STROKEAHA.110.589911>
14. Kulcsár Z, Houdart E, Bonafé A, et al. Intra-aneurysmal thrombosis as a possible cause of delayed aneurysm rupture after flow-diversion treatment. *AJNR Am J Neuroradiol*. 2011;32(1):20-5.
<https://doi.org/10.3174/ajnr.A2370>
15. Cebral JR, Mut F, Raschi M, et al. Aneurysm rupture following treatment with flow-diverting stents: computational hemodynamics analysis of treatment. *AJNR Am J Neuroradiol*. 2011 Jan;32(1):27-33.
<https://doi.org/10.3174/ajnr.A2398>

Copyright of Medical Journal of Bakirkoy is the property of Galenos Yayinevi Tic. LTD. STI and its content may not be copied or emailed to multiple sites or posted to a listserv without the copyright holder's express written permission. However, users may print, download, or email articles for individual use.