

Simultaneous *Cytomegalovirus* and *Mycobacterium Tuberculosis* Infection Presenting as Hemorrhagic Colitis 3 Years After a Kidney Transplant

Guilherme Santoro-Lopes,¹ Alberto dos Santos de Lemos,¹ Márcia Halpern,¹
Renato Torres Gonçalves,² Marcos André Alves Rosa Santos,² Paulo Marcos Nunes Valiante³

Abstract

***Cytomegalovirus* is an important cause of colonic disease in solid organ transplant recipients. Although several reports have shown that simultaneous infection with other pathogens may aggravate the course of *cytomegalovirus* colitis, to our knowledge, no case of colitis caused by simultaneous *cytomegalovirus* and *Mycobacterium tuberculosis* has been previously reported.**

We describe a case of hemorrhagic colitis associated with simultaneous *cytomegalovirus*/*Mycobacterium tuberculosis* infection in a 26-year-old woman, 38 months after a kidney transplant. Initial results of histopathologic analyses of gastrointestinal biopsies showed that tuberculosis was the only cause of colitis, as no morphologic alteration suggestive of *cytomegalovirus* infection was observed on hematoxylin-eosin staining. However, further analysis with immunoperoxidase staining confirmed the clinical suspicion of *cytomegalovirus* infection. This report shows that *cytomegalovirus*/tuberculosis coinfection may be a cause of late-onset colitis among solid organ transplant recipients. It also illustrates that coinfection with other pathogens may pose an additional challenge for diagnosing gastrointestinal *cytomegalovirus* disease.

Key words: *Opportunistic Infection, Immunossuppression, Diagnosis, Pathology, Immunostaining*

From the ¹Infectious Diseases Clinic, Hospital Universitário Clementino Fraga Filho, the ²Renal Transplant Unit, Nephrology Clinic, Federal University of Rio de Janeiro, and the ³Pathology Section, Hospital Universitário Clementino Fraga Filho, Federal University of Rio de Janeiro, Rio de Janeiro, Brazil

Address reprint requests to: Dr. Guilherme Santoro-Lopes, Rua Justiniano da Rocha 201/302, Vila Isabel, CEP 20551-010, Rio de Janeiro, RJ, Brazil
Phone: +55 21 2562 2725 Fax: +55 21 2254 2694 E-mail: santorolopes@hucff.ufrj.br

Experimental and Clinical Transplantation (2011) 5: 340-343

Introduction

Cytomegalovirus (CMV) is a common cause of gastrointestinal tract disease in solid organ transplant recipients. It may affect any site from the mouth to the anus. Colonic disease caused by CMV may present as a variety of clinical entities that include diarrhea, lower gastrointestinal bleeding, ischemic colitis, and perforation.^{1,2} Colonic disease caused by coinfection with other pathogens, such as *Histoplasma* spp.³ *Campylobacter jejuni*,⁴ *Clostridium difficile*,^{5,6} and *Entamoeba histolytica*⁷ occasionally have been reported, mostly among immunocompromised patients. Less frequently than CMV, tuberculosis also may cause lower gastrointestinal tract disease in transplant recipients.^{8,9} Although it has been shown recently that simultaneous CMV/tuberculosis may cause pulmonary disease after solid organ transplant,¹⁰ we are unaware of any previous report of colitis associated with this coinfection. We describe a case of late-onset hemorrhagic colitis associated with simultaneous CMV/tuberculosis infection in a kidney transplant recipient.

Case Report

A 26-year-old woman who had received a kidney transplant was admitted to our hospital complaining of intense bloody diarrhea that had started on the previous day. She also reported epigastralgia and postprandial vomiting that were present for 5 days before admission. She denied fever or any other symptoms. She was alert and well oriented. Her arterial blood pressure was 170 × 100 mm Hg. Her mucous was slightly pale and moderately dehydrated. The results of the remainder of her physical examination were unremarkable. Her immunosuppressive regimen consisted of

tacrolimus (4 mg/d), sirolimus (2 mg/d), and prednisone (5 mg/d).

She had received a kidney graft from a deceased donor 38 months earlier. The cause of her renal disease was undetermined. Both donor and recipient were seropositive for *CMV*. At the time of transplant, she had a negative result on her tuberculin skin test and normal results on chest radiographs. She denied a previous diagnosis of tuberculosis or exposure to known causes of the disease.

Two weeks after transplant, she had an episode of severe acute rejection that was unresponsive to methylprednisolone pulse therapy. Treatment with antithymocyte globulin was followed by a significant improvement of renal function. Thereafter, her clinical course was uneventful, with a serum creatinine ranging from 141 to 176 $\mu\text{mol/L}$.

At the time of this new admission, results of her initial laboratory tests showed hemoglobin 113 g/L, white blood cell count $6.7 \times 10^9/\text{L}$, platelet count $157 \times 10^9/\text{L}$, and serum creatinine 318 $\mu\text{mol/L}$. The test results of serum glucose, electrolytes, aminotransferases, alkaline phosphatase, amylase, and lipase were within the normal ranges. The results of a blood *CMV* pp65 antigenemia assay were negative.

She was initially treated with intravenous crystalloid infusion and 80 mg/d of omeprazole. On the second day after admission, an esophagogastroduodenoscopy revealed several small ulcers in the duodenal mucosa. Biopsies of the ulcers were taken.

On the next 3 days, the patient reported partial improvement of her epigastralgia. She stopped vomiting, but still eliminated diarrheal stools without visible blood. On the sixth day of hospitalization, she had several episodes of hematochezia. Her hemoglobin concentration dropped to 73 g/L. A colonoscopy, performed on the following day, showed an ulcer with 1.5 cm diameter with a fibrinous base in the transverse colon, and 2 ulcers with 0.4 cm diameter covered with clots in the ascending and descending colon. Biopsies were performed. Empirical therapy with intravenous ganciclovir was started. The results of a histopathologic examination of the duodenum biopsies with hematoxylin-eosin staining became available 5 days later and were compatible with chronic enteritis without any alteration suggestive of *CMV* infection. Despite this negative result, ganciclovir therapy was maintained.

On the 21st day of hospitalization, after 2 weeks of antiviral therapy, the patient had complete remission of the gastrointestinal manifestations. A new colonoscopy showed partial resolution of the colitis, with the persistence of just 1 colonic ulceration. However, she started to present with intermittent fever, with temperatures ranging between 38°C and 39°C, and mild cough without expectoration. No other symptoms were present. Cultures for bacterial and fungal pathogens of 2 blood samples and a urine specimen showed negative results. Results of chest radiographies were normal. By this time, the result of the colonic biopsies, which had been delayed (because of circumstantial technical problems at the pathology laboratory) became available and revealed a granulomatous colitis, with no observed cytopathic effect suggestive of viral infection on hematoxylin-eosin staining (Figure 1). Few acid-fast bacilli were detected on Ziehl-Neelsen staining. Owing to the high clinical suspicion of *CMV* infection, duodenal and colonic biopsy specimens were further examined by immunoperoxidase staining with anti-*CMV* monoclonal antibody (Dako A/S, Glostrup, Denmark), which showed the presence of *CMV* antigen in stromal cells of all examined specimens (Figure 2).

A computerized tomography scan of the thorax performed on the 22nd day after admission revealed multiple small nodular opacities in both lungs and confluent centrilobular nodules in the left lower lobe. The smear of an induced sputum sample was positive for acid-fast bacilli (1+). Antituberculous treatment with rifampin, isoniazid, and pyrazinamide was started on the same day. Eight

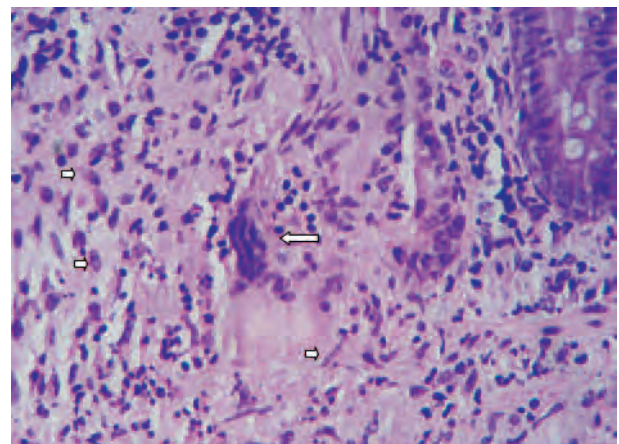


Figure 1. Granulomatous colitis characterized by epithelioid (small arrows) and multinucleated giant cells (large arrow) (Hematoxylin-eosin, $\times 400$).

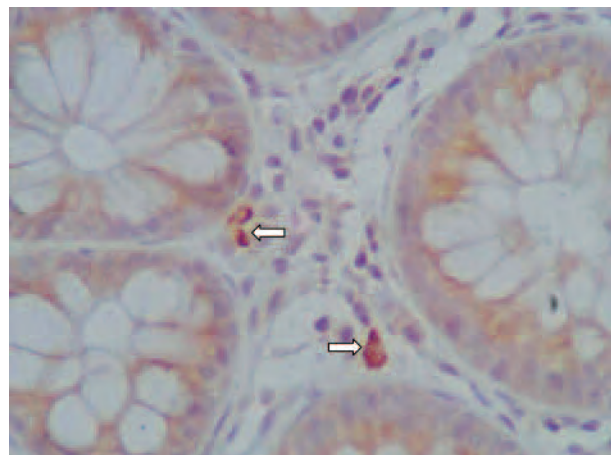


Figure 2. Immunohistochemical staining showing CMV infection (arrows) in stromal cells ($\times 1000$).

weeks later, the culture of this sputum specimen confirmed the diagnosis *Mycobacterium tuberculosis* infection.

On the 35th day of hospitalization (after 28 days of ganciclovir therapy and 12 days of antituberculous therapy), a new colonoscopy showed complete resolution of the colitis. The patient was discharged to the day clinic where she was maintained under suppressive IV ganciclovir therapy in association with the antituberculous therapy.

Two weeks later, after 25 days of antituberculous therapy, she complained of upper right abdominal pain. Laboratory tests showed total bilirubin $43 \mu\text{mol/L}$, direct bilirubin $38 \mu\text{mol/L}$, aspartate aminotransferase $1.90 \mu\text{kat/L}$, alanine aminotransferase $7.55 \mu\text{kat/L}$, and gamma glutamyltransferase $5.77 \mu\text{kat/L}$. Antituberculous therapy and ganciclovir were interrupted. Two weeks after treatment interruption, she had normal liver enzyme assays, but she was again admitted with massive hematochezia. A new colonoscopy showed 4 colonic ulcerations that were biopsied. Induction therapy with intravenous ganciclovir was restarted. On subsequent days, the patient became asymptomatic. Gradual reintroduction of antituberculous therapy with rifampicin, isoniazid, and pyrazinamide was well tolerated. An examination of the biopsy samples of the relapsed colonic ulcers with hematoxylin-eosin staining revealed the presence of cytopathic alterations compatible with CMV infection. The patient was discharged on the 20th day after this new admission. She continued the induction therapy with ganciclovir on an outpatient basis for an additional 22 days,

when a new colonoscopy showed complete resolution of the colonic ulcerations. She stopped antituberculous therapy 9 months later. Ever since, her clinical course has been uneventful.

Discussion

Despite progresses in managing CMV infection, it is an important cause of morbidity and mortality among solid organ transplant recipients. Usually, CMV disease occurs within the first 3 months after transplant. However, late CMV disease is being increasingly recognized, mainly in high-risk patients, such as CMV-seronegative recipients from seropositive donors, who received antiviral prophylaxis.¹¹ Our patient was already seropositive for CMV at the time of transplant.

Factors that might have triggered late CMV reactivation in this case cannot be clearly defined from our data. She had a history of acute rejection treated with antithymocyte globulin, 2 major risk factors for CMV reactivation. However, it is unlikely that such events, which occurred approximately 3 years earlier, had any causal link with the reactivation of CMV infection. On the other hand, increased tumor necrosis factor alpha release in response to tuberculosis may have contributed to the occurrence of CMV disease in this case.¹² Tumor necrosis factor alpha binding to receptors in latent infected cells triggers the intracellular signaling process that ultimately results in activation of CMV replication.² Although it is not possible to ascertain which infection occurred first in this case, it is plausible that tuberculosis might have been evolving subclinically for several weeks before CMV reactivation.

This report also highlights the challenges associated with the diagnosis of intestinal CMV disease, especially when a simultaneous infection is affecting the same site. Evidence of viremia, such as detection of pp-65 antigenemia or viral nucleic acids, is frequently absent in patients with gastrointestinal CMV disease.^{1, 2} Thus, diagnosis of CMV colitis is more frequently established by finding typical viral cytopathic effects in stromal or endothelial cells of gastrointestinal mucosa biopsy samples stained with haematoxylin-eosin.¹ The role of immunohistochemistry as a routine tool for diagnosing CMV in gastrointestinal biopsies in immunosuppressed patients is debated.^{13, 14} In the present case, the

diagnosis of CMV infection in duodenal and colonic biopsy specimens only became evident with immunostaining. The absence of characteristic viral cytopathic effects in the initial histopathologic analysis combined with finding alterations compatible with tuberculous colitis might have obscured the diagnosis of CMV colitis in this case.

Simultaneous tuberculosis and CMV infection may present as late-onset colitis in solid organ transplant recipients. As CMV disease may be superimposed on other gastrointestinal infectious complications, a high clinical suspicion is justified even when colonic infection with another pathogen is detected. The absence of characteristic cytopathic effects in biopsy samples stained with hematoxylin-eosin may not rule the diagnosis of CMV infection. Therefore, immunostaining for CMV should be considered to complement the diagnostic investigation in highly suspicious cases.

References

1. Korkmaz M, Kuneveci G, Selcuk H, et al. The role of early colonoscopy in CMV colitis of transplant recipients. *Transplant Proc.* 2005;37(7):3059-3060.
2. Rubin RH. The pathogenesis and clinical management of cytomegalovirus infection in the organ transplant recipient: the end of the 'silo hypothesis'. *Curr Opin Infect Dis.* 2007;20(4):399-407.
3. Fan X, Scott L, Qiu S, Raju GS, Shabot M. Colonic coinfection of histoplasma and cytomegalovirus mimicking carcinoma in a patient with HIV/AIDS. *Gastrointest Endosc.* 2008;67(6):977-978; discussion 978.
4. Toussaint N, Goodman D, Langham R, Gock H, Hill P. Haemorrhagic *Campylobacter jejuni* and CMV colitis in a renal transplant recipient. *Nephrol Dial Transplant.* 2005;20(4):823-836.
5. Dahman M, Krell R, Brayman K, et al. Simultaneous *Clostridium difficile*-associated colitis and late-onset intestinal cytomegalovirus disease in a renal transplant recipient. *Ann Transplant.* 2010;15(4):72-76.
6. Veroux M, Puzzo L, Corona D, et al. Cytomegalovirus and *Clostridium difficile* ischemic colitis in a renal transplant recipient: a lethal complication of anti-rejection therapy? *Urol Int.* 2007;79(2):177-179; discussion 180.
7. Fatkenheuer G, Arnold G, Steffen HM, et al. Invasive amoebiasis in two patients with AIDS and cytomegalovirus colitis. *J Clin Microbiol.* 1997;35(8):2168-2169.
8. Baysal C, Gur G, Gursoy M, et al. Colonoscopy findings in renal transplant patients with abdominal symptoms. *Transplant Proc.* 1998;30(3):754-755.
9. Charpentier B, Salmon R, Arvis G, Fries D. Tuberculous acute colitis in kidney-transplant patient. *Lancet.* 1979;2(8137):308.
10. Cheng JW, Chen YC, Tian YC, Fang JT, Yang CW. Coinfection of cytomegalovirus and miliary tuberculosis in a post-renal transplant recipient. *J Nephrol.* 2007;20(1):114-118.
11. Meylan PR, Manuel O. Late-onset cytomegalovirus disease in patients with solid organ transplant. *Curr Opin Infect Dis.* 2007;20(4):412-418.
12. Poveda F, Camacho J, Arnalich F, Codoceo R, del Arco A, Martínez-Hernández P. Circulating cytokine concentrations in tuberculosis and other chronic bacterial infections. *Infection.* 1999;27(4-5):272-274.
13. Mönkemüller KE, Bussian AH, Lazenby AJ, Wilcox CM. Special histologic stains are rarely beneficial for the evaluation of HIV-related gastrointestinal infections. *Am J Clin Pathol.* 2000;114(3):387-394.
14. Maher MM, Nassar MI. Acute cytomegalovirus infection is a risk factor in refractory and complicated inflammatory bowel disease. *Dig Dis Sci.* 2009;54(11):2456-2462.