

# Classification of Ureteral Stenosis and Associated Strategy for Treatment After Kidney Transplant

Bulang He,<sup>1,2</sup> Alexandra Bremner,<sup>3</sup> Ying Han<sup>4</sup>

## Abstract

**Objectives:** Ureteral stenosis is a common complication after a kidney transplant. Treatment for ureteral stenosis ranges from interventional procedures to open surgery. The aim of this study is to present classification for ureteral stenosis and recommend the targeted strategy for effective treatment.

**Materials and Methods:** Twelve cases of ureteral stenosis were diagnosed among 193 kidney transplants, of which 91 were from a live donor and 102 from a deceased donor. The mean age was  $46.22 \pm 13.23$  years. The diagnosis of ureteral stenosis includes serum creatinine elevation, hydronephrosis, and presence of stricture on a pyelogram. The criterion for classification is based on the severity of stricture.

**Results:** One of ureteral stenoses was classified as grade 1, six were grade 2, and five were grade 3. Of 12 cases, 10 were live-donor kidney transplant, 4 had lymphocele, and 2 had a hematoma after transplant. The corresponding strategy for each grade of ureteral stenosis is as follows: grade 1, ureteral stent reinsertion; grade 2, cutting balloon dilatation or endoscopic incision of stenosis; grade 3, open surgery urinary tract reconstruction. All cases were successfully treated using these strategies.

**Conclusions:** This classification of ureteral stenosis provides guidance for effective management and avoids unnecessary procedures. In this series, ureteral stenosis was significantly associated with a live donor and surgical complications.

**Key words:** Kidney transplant, Ureteral stenosis, Live donor, Deceased donor, Complication

## Introduction

Kidney transplant is the definitive treatment for end-stage renal disease. Long-term outcomes have been improved significantly with current immunosuppressive regimens. Ureteral stenosis (US) is one of the most common urologic complications and has been reported in 2.6% to 15% of transplanted patients.<sup>1-9</sup> This wide range probably reflects differences in definitions of urologic complications after kidney transplant. Treatment for US ranges from a minimum interventional procedure to open surgical reconstruction of the urinary tract. However, there is a lack of criteria for classifying US and targeted options for treatment in the literature. This study aims to present classification criteria for US and to determine associated strategies for prompt and effective treatment that avoid unnecessary procedures.

## Materials and Methods

Review and analysis of patient clinical records were undertaken with the approval of the hospital quality improvement committee and human research ethics committee. All protocols were approved by the ethics committee of the institution before the study began, and the protocols conformed with the ethical guidelines of the 1975 Helsinki Declaration.

From January 2005 to July 2010, one hundred ninety-three kidney transplants (132 men, 61 women;

From the Department of <sup>1</sup>WA Liver and Kidney Transplant Service, Sir Charles Gairdner Hospital, Hospital Avenue, Nedlands Western Australia, 6009; the <sup>2</sup>School of Surgery, The University of Western Australia, Perth 6009; the <sup>3</sup>School of Population Health, The University of Western Australia, Perth 6009; and the <sup>4</sup>Osborne Park Hospital, Perth 6014, Australia

**Acknowledgements:** Alexandra Bremner performed the statistical analyses. Ying Han performed the data collection. The authors thank the interventional radiologists who performed the percutaneous nephrostomy and cutting balloon dilatation of ureteral stenosis at Sir Charles Gairdner Hospital. The authors have no conflicts of interest to disclose. No funding was received for this study.

**Corresponding author:** Clinical Associate Prof. Bulang He, MB BS, MS, FRACS, WA Liver and Kidney Transplant Service, Sir Charles Gairdner Hospital, Hospital Avenue, Nedlands Western Australia, 6009, Australia

Phone: +61 8 9346 4055 Fax: +61 8 9346 7442 E-mail: bulang.he@health.wa.gov.au

*Experimental and Clinical Transplantation* (2013) 2: 122-127

mean age,  $46.22 \pm 13.23$  y; range, 18-71 y) were performed at Sir Charles Gairdner Hospital, Perth, Western Australia. Of 193 recipients, 91 were live-donor (LD) kidney transplants, and donor nephrectomies were performed using the transperitoneal laparoscopic approach.<sup>10</sup> There were 102 deceased-donor (DD) kidney transplants. Transplant surgery was the standard technique with the renal vein anastomosed end-to-side of the external iliac vein, and the renal artery anastomosed end-to-side of the external iliac artery or end-to-end of the internal iliac artery. In all cases, the method for ureteroneocystostomy was the Lich-Gregoir technique with ureteral stent placement. A Foley catheter was inserted into the bladder for 5 days. The ureteral stent was removed by flexible cystoscopy 4 to 6 weeks after transplant. A suction drain was placed routinely and removed within 48 hours, or when the drain volume was less than 50 mL. The immunosuppressive regimen was a triple therapy with or without basiliximab induction.

Diagnosis of US was based on kidney function deteriorating, hydronephrosis on ultrasound, and identifying a ureteral stricture on a pyelogram. The degree of US was classified as grades 1, 2, or 3, depending on its severity and nature. Twelve of the 193 kidney transplant patients developed US. Their ages ranged from 30 to 71 years, and there were 8 men and 4 women. Ten cases were a first kidney transplant at the right iliac fossa, while 2 cases were a second kidney transplant at the left iliac fossa. Of the 12 cases of US, 10 recipients had LD transplants, whereas 2 recipients had DD transplants. The time between kidney transplant and diagnosis of US ranged from 4 weeks to 9 months, with follow-ups from 6 months to 5 years. Methods for treatment of US ranged from minimally interventional procedures, such as percutaneous antegrade cutting balloon (Boston Scientific Corp, Natick, MA, USA), dilatation, and stent insertion, to endoscopic incision of the US and open surgery of urinary tract reconstruction.

Among the 12 patients with US, 4 had perigraft lymphocele after kidney transplant. One patient had a kidney graft rupture 4 days after transplant, for which surgical exploration and repair were performed. One patient developed a perigraft hematoma secondary to a renal graft biopsy 3 weeks after transplant that required surgical exploration and evacuation of the hematoma. This study excludes urinary leaks, as there were only 2 cases (1%) in this cohort.

### Statistical analyses

Logistic regression was used to model the relations between US and age, sex, donor type (LD or DD), and posttransplant complications (present or absent). Odds ratios and 95% confidence intervals are reported. Hosmer and Lemeshow statistics were used to test the multivariate logistic regression models for goodness of fit. Analyses were conducted using SPSS software (SPSS: An IBM Company, version 18.0, IBM Corporation, Armonk, NY, USA). Statistical significance was set to .05.

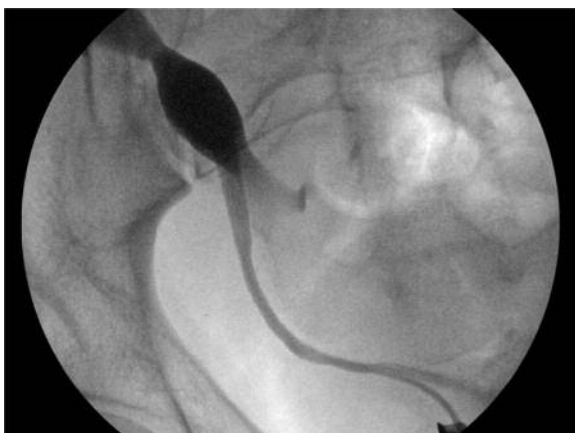### Results

As shown in Table 1, one case was classified as grade 1 (Figure 1). This case presented with increased serum creatinine (SCr) and hydronephrosis on ultrasound, but there was no obvious stricture identified on the pyelogram. This case was successfully treated with cystoscopy and ureteral stent reinsertion for 6 weeks. Six cases that presented with increased SCr, hydronephrosis on ultrasound, and significant focal stricture (< 1 cm) at the site of ureteroneocystostomy on the pyelogram were classified as grade 2 (Figure 2). Of the 6 cases, 4 underwent cystoscopy and incision of the ureteral orifice with stent placement for 6 weeks. Two cases were treated with percutaneous antegrade cutting balloon dilatation at the stenosis area and stent placement for 6 weeks. The remaining 5 cases were classified as grade 3 (Figure 3) and presented

**Table 1.** Definition for Classification of US

Degree of US	No.	LD / DD	Hydronephrosis on US	Pyelogram	Associated Lymphocele/Hematoma	Representative Image
Grade 1	1	1/	Yes	No ureteric stricture identified	No	Figure 1
Grade 2	6	5/1	Yes	Focal stricture (< 1 cm) at ureteroneocystostomy	1/0	Figure 2
Grade 3	5	4/1	Yes	Distal long segment ureteral stricture extending to proximal ureter/pelvis ( $\geq 1$ cm)	3/2	Figure 3

**Abbreviations:** DD, deceased donor; LD, living donor; US, ureteric stricture

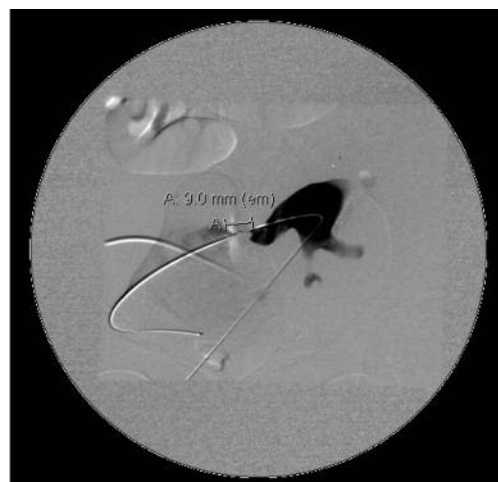**Figure 1.** Retrograde Pyelogram of Transplant Kidney at Right Iliac Fossa

Grade 1 US: No obvious ureteral stricture seen on retrograde pyelogram.

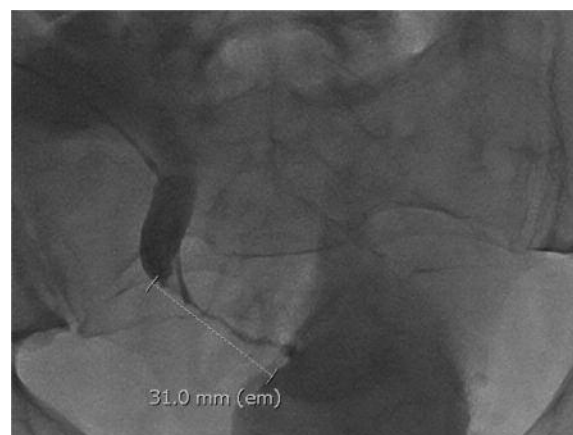
with SCr elevation, hydronephrosis on ultrasound, and significant long segment (> 1 cm) distal ureteral stricture on a pyelogram. Three of these grade 3 US were initially treated with cutting balloon dilatation (Boston Scientific) and stent placement; but subsequently, open surgery reconstruction was performed owing to poor response to interventional treatment. The other 2 grade 3 US were treated with open surgery (Figures 4A, 4B, and 4C) as the first-line therapy to avoid unnecessary interventional procedures.

All cases of US were treated successfully with the procedures described. There was no graft loss, no further complication, and no patient death caused by US on follow-up from 3 to 58 months, with median follow-up of 22 months. The hydronephrosis resolved completely in 11 cases and 1 case improved with mild prominent of collecting system on ultrasound. The graft function improved dramatically after stenosis resolution. Levels of SCr were maintained at  $138 \pm 29.4 \mu\text{mol/L}$  on follow-up, compared with  $263 \pm 63.8 \mu\text{mol/L}$  before treatment.

Donor type and presence or absence of complications, such as graft rupture, lymphocele, or symptomatic hematoma were significantly associated with US (see Table 2). In those recipients without US, 9 cases developed perigraft lymphocele/hematoma (4.7%). After adjusting for age, sex, and presence of complications, patients with a LD had 4.5 times greater odds of experiencing a US than did patients with a DD. After adjusting for age, sex, and donor type, patients with complications had 29.5 times greater odds of US than did patients without complications.

**Figure 2.** Antegrade Pyelogram of Kidney Graft at Left Iliac Fossa Via Percutaneous Nephrostomy

Grade 2 US: Obvious distal ureteral stricture 9.0 mm long (&lt; 10 mm) on antegrade pyelogram.

**Figure 3.** Antegrade Pyelogram of Kidney Graft at Right Iliac Fossa Via Percutaneous Nephrostomy

Grade 3 US: Long segment distal ureteral stricture 31.0 mm long (&gt; 10 mm) on antegrade pyelogram.

## Discussion

Surgical complications, consisting predominantly of US and urine leakage, are a major cause of morbidity, delay graft function, graft loss, and patient mortality after kidney transplant.<sup>11,12</sup> The incidence of ureteral complications ranged from 3% to 14% among different transplant units.<sup>1,12-15</sup> Ureteral stricture is more commonly encountered (3% to 8%)<sup>1,5,16,17</sup> than is urinary leakage (1.55%).<sup>17</sup> These 2 major complications can be promptly identified and repaired or corrected without compromising graft function in the long term. However, if treatment is delayed or inappropriate, graft loss or patient death may result.<sup>12,18,19</sup>

**Table 2.** Risk of US Associated With Age, Sex, Donor Type, and Complications

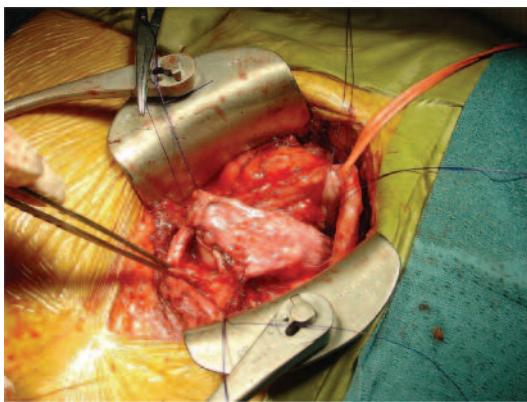
Variable	Mean (SD) or n (%)	Crude OR (95% CI)	Adjusted <sup>†</sup> OR (95% CI)	Multivariate <sup>‡</sup> OR (95% CI)
Age (y)	46.2 (13.2)	1.01 (0.96-1.06)		0.97 (0.92-1.02)
Sex	Male	132 (68.4)	1.00	1.00
	Female	61 (31.6)	1.09 (0.31-3.76)	1.50 (0.36-6.20)
Donor type	Live	91 (47.2)	1.00	1.00
	Deceased	102 (52.8)	5.92 (1.26-27.8)	5.98 (1.27-28.2)
Complications	Absent	180 (93.3)	1.00	1.00
	Present	13 (6.7)	24.9 (6.38-96.9)	37.8 (7.44-192.5)

**Abbreviations:** CI, confidence interval; OR, odds ratio; SD, standard deviation; US, ureteric stricture

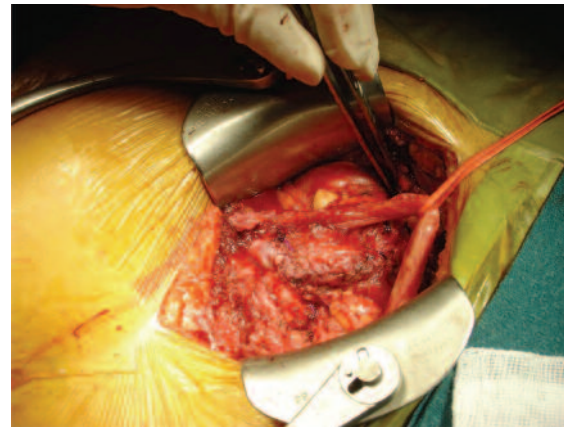
<sup>†</sup>Adjusted for age and sex

<sup>‡</sup>Multivariate model with all variables included

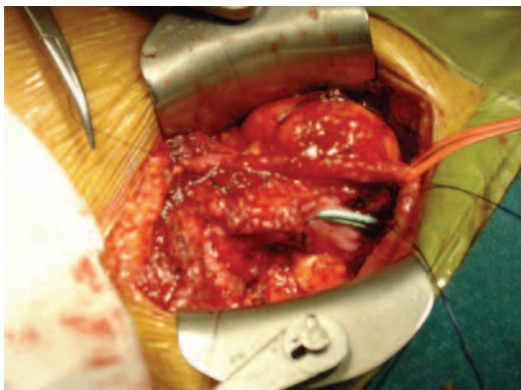
**Figure 4A.** Boari Flap Urinary Tract Reconstruction: Oblique Incision at the Right Iliac Fossa. Bladder Boari Flap Created and Being Anastomosed to the Dilated Renal Pelvis Above the Ureteral Stenosis



**Figure 4C.** Boari Flap Urinary Tract Reconstruction: Completion of the Urinary Tract Reconstruction by Using a Bladder Boari Flap



**Figure 4B.** Boari Flap Urinary Tract Reconstruction: Anastomosis of a Tubularized Bladder Boari Flap to the Renal Pelvis With 2 Stents Placed In Situ



The cause of US is known to be a poor organ recovery with destruction of ureteral blood supply or anastomotic technique error. Other risk factors include administering steroids, chronic rejection, and/or virus infection.<sup>2,16,20,21</sup> It has been observed that the features of presentation of US are associated with its causes. To perform prompt, effective treatment, we recommend the following 3 level classifications, based on the degree of US after a

transplant. Grade 1 US is defined as *graft function deterioration with presence of hydronephrosis on ultrasound, but no obvious stricture identified on a pyelogram* (Figure 1). It is usually caused by ureteral edema or debris in the collecting system. Grade 2 US is defined as *SCr elevation, presence of hydronephrosis on ultrasound, and a focal (< 1 cm) distal ureteral stricture at the ureteral anastomotic site on a pyelogram*. It is usually caused by a technique error or fibrotic hyperplasia at the anastomosis (Figure 2). Grade 3 US is defined as *SCr elevation, hydronephrosis on ultrasound, and a long segment (> 1 cm) distal ureteral stricture extending to proximal ureter or pelvis on pyelogram*. It is usually caused by ischemic damage to the ureter or fibrosis secondary to virus infection or rejection (Figure 3).

Classification of US is useful in making precise, targeted decisions about the most effective treatment and reducing unnecessary procedures. Based on the classification grade, the associated strategy can be determined promptly. The strategy for grade 1 US is prolonged ureteral stent insertion for 6 weeks. The ureteral stent insertion is preferably by cystoscopy;

otherwise, by percutaneous nephrostomy. Grade 2 US can be effectively treated by cystoscopy and incision of the stenosis with stent reinsertion for 6 weeks, or percutaneous cutting balloon dilatation and stent reinsertion for 6 weeks. The grade 3 US is best treated with open surgery, either proximal ureter-bladder reanastomosis, pyelovesicostomy, or Boari flap urinary tract reconstruction (Figures 4A, 4B, and 4C). In our series, there was one grade 1 and six grade 2 US; all of which responded effectively to the associated treatment. There were 5 cases classified as grade 3, of which 3 were initially treated by interventional procedures, and then subsequent open surgery urinary tract reconstruction was necessary as the stenoses recurred. Subsequently, two grade 3 US were treated with open surgery reconstruction as the first-line therapy to avoid unnecessary interventional procedures. All cases resolved completely after being treated according to the classification strategy. There were no further complications and no mortality resulting from US on follow-up.

Before introducing the interventional radiology procedure, in our clinical practice, the therapy for US was always open surgery urinary tract reconstruction. There are reports of success rates of 69.5% to 85% in treating US by interventional radiology.<sup>12,22-26</sup> Therefore, the endoscopic or percutaneous pyelogram and dilatation of stenosis had become used commonly as a first-line treatment in some transplant units. However, using these interventional procedures for grade 3 US increase the risk of infection owing to prolonged external/internal drainage. Classification of US provides guidance for precise decision making regarding the most effective treatment strategy and avoids unnecessary procedures and further complications.

In the papers that we reviewed, there were no selection criteria for the types of cases that should have responded well to interventional procedures, although it was observed that short perianastomotic stricture had better results.<sup>26</sup> In our series, 3 of 5 grade three US had an interventional procedure of cutting balloon dilatation and stent reinsertion as a first-line therapy, but the stenosis recurred soon after stent removal. Surgical reconstruction was subsequently performed and the stricture was corrected completely. Therefore, for grade 3 US, reconstruction surgery is a better option than is an interventional procedure. By referring to these new classification criteria, identifying the grade of US,

and using the associated strategy, unnecessary procedures can be avoided.

For surgical repair of grade 3 US, bladder or Boari flap reanastomosis to the proximal ureter/renal pelvis is preferred in our unit. The technique is to perform bladder mucosa to ureter anastomosis with bladder muscular layer to periureteric tissue stitches as a second layer. There were no further complications after urinary tract reconstruction, and all US were corrected completely with satisfactory results. We prefer to use internal stents rather than external drainage to reduce the risk of infection. Scheduling surgery should be done as early as possible to avoid prolonged percutaneous drainage or the stent placement.

In addition, we found that US was associated with the donor group in this series. This included 10 cases of which 4 were grade 3 US were from LD kidney transplants. The risk may be related to the laparoscopic technique, as increased ureteral complications were reported in recipients from laparoscopic donor nephrectomy compared with open donor nephrectomy.<sup>3,4,27</sup> The manipulation of the ureter during the laparoscopic donor nephrectomy may have an adverse effect on the ureter blood circulation, although the periureter tissue is preserved. There was no technique difference identified in dealing with ureter dissection and division between the donors whose recipient developed US and those who did not. Laparoscopic donor nephrectomy has been a consistent technique to preserve the gonadal vein with the ureter as well as periureteric tissues. Therefore, extra care is required during ureter and renal hilum dissection to prevent subsequent ureteral ischemic damage.

Ureteral strictures in our group are significantly related to posttransplant complications. The incidence of lymphocele and perigraft hematoma was significantly higher in US group compared with those without US (50% vs 4.7%;  $P < .001$ ). In 5 of the grade 3 US patients, 1 patient developed graft rupture 4 days after transplant surgery. The patient required surgical exploration and repair of the ruptured graft. Three recipients had lymphocele at the lower pole of the kidney graft, which was treated by percutaneous drainage and povidone-iodine instillation. One patient had a perigraft hematoma secondary to renal graft biopsy, for which surgical exploration and evacuation were necessary.

In conclusion, this classification of US provides

guidance for effective management of US after kidney transplant, with accurate diagnosis and targeted strategies that avoid unnecessary procedures and further complications. In addition, US is significantly associated with LD kidney transplant and complications such as lymphocele and symptomatic hematoma. Extra care must be taken during laparoscopic donor nephrectomy to prevent ischemic damage to the ureter, and all efforts should be made to prevent lymphocele formation and perigraft hematoma.

## References

- Mäkisalo H, Eklund B, Salmela K, et al. Urological complications after 2084 consecutive kidney transplantations. *Transplant Proc.* 1997;29(1-2):152-153.
- Shoskes DA, Hanbury D, Cranston D, Morris PJ. Urological complications in 1,000 consecutive renal transplant recipients. *J Urol.* 1995;153(1):18-21.
- Loughlin KR, Tilney NL, Richie JP. Urologic complications in 718 renal transplant patients. *Surgery.* 1984;95(3):297-302.
- Cimic J, Meuleman EJ, Oosterhof GO, Hoitsma AJ. Urological complications in renal transplantation. A comparison between living-related and cadaveric grafts. *Eur Urol.* 1997;31(4):433-435.
- El-Mekresh M, Osman Y, Ali-El-Dein B, El-Diasty T, Ghoneim MA. Urological complications after living-donor renal transplantation. *BJU Int.* 2001;87(4):295-306.
- Kekec Y, Tokyay R, Tavli S, Bilgin N, Haberal M. Urological complications in 884 consecutive transplants. *Transplant Proc.* 1992;24(5):1870-1871.
- Rigg KM, Proud G, Taylor RM. Urological complications following renal transplantation. A study of 1016 consecutive transplants from a single centre. *Transpl Int.* 1994;7(2):120-126.
- Salomon L, Saporta F, Amsellem D, et al. Results of pyeloureterostomy after ureterovesical anastomosis complications in renal transplantation. *Urology.* 1999;53(5):908-912.
- Ghasemian SM, Guleria AS, Khawand NY, Light JA. Diagnosis and management of the urologic complications of renal transplantation. *Clin Transplant.* 1996;10(2):218-223.
- He B, Mitchell A, Delriviere L, et al. Laparoscopic donor nephrectomy. *ANZ J Surg.* 2011;81(3):159-163.
- Beyga ZT, Kahan BD. Surgical complications of kidney transplantation. *J Nephrol.* 1998;11(3):137-145.
- Englesbe MJ, Dubay DA, Gillespie BW, et al. Risk factors for urinary complications after renal transplantation. *Am J Transplant.* 2007;7(6):1536-1541.
- Emiroğlu R, Karakayall H, Sevmiş S, Akkoç H, Bilgin N, Haberal M. Urological complications in 1275 consecutive renal transplantations. *Transplant Proc.* 2001;33(1-2):2016-2017.
- Reek C, Noster M, Burmeister D, Wolff JM, Seiter H. Urological complications of renal transplantation: a series of 900 cases. *Transplant Proc.* 2003;35(6):2106-2107.
- Hakim NS, Benedetti E, Pirenne J, et al. Complications of ureterovesical anastomosis in kidney transplant patients: the Minnesota experience. *Clin Transplant.* 1994;8(6):504-507.
- Keller H, Nöldge G, Wilms H, Kirste G. Incidence, diagnosis, and treatment of ureteric stenosis in 1298 renal transplant patients. *Transpl Int.* 1994;7(4):253-257.
- Dinckan A, Tekin A, Turkyilmaz S, et al. Early and late urological complications corrected surgically following renal transplantation. *Transpl Int.* 2007;20(8):702-707.
- van Rooijen JH, Kirkels WJ, Zietse R, Roodnat JJ, Weimar W, Ijzermans JN. Long-term graft survival after urological complications of 695 kidney transplantations. *J Urol.* 2001;165(6 Pt 1):1884-1887.
- Streeter EH, Little DM, Cranston DW, Morris PJ. The urological complications of renal transplantation: a series of 1535 patients. *BJU Int.* 2002;90(7):627-634.
- Maier U, Madersbacher S, Banyai-Falger S, Susani M, Grünberger T. Late ureteral obstruction after kidney transplantation. Fibrotic answer to previous rejection? *Transpl Int.* 1997;10(1):65-68.
- Faenza A, Nardo B, Catena F, et al. Ureteral stenosis after kidney transplantation. A study on 869 consecutive transplants. *Transpl Int.* 1999;12(5):334-340.
- Benoit G, Alexandre L, Moukarzel M, Yataghene Y, Charpentier B, Jardin A. Percutaneous antegrade dilatation of ureteral strictures in kidney transplants. *Transplant Proc.* 1994;26(1):290-291.
- Lojanapiwat B, Mital D, Fallon L, et al. Management of ureteral stenosis after renal transplantation. *J Am Coll Surg.* 1994;179(1):21-24.
- Kim JC, Banner MP, Ramchandani P, Grossman RA, Pollack HM. Balloon dilation of ureteral strictures after renal transplantation. *Radiology.* 1993;186(3):717-722.
- Bhagat VJ, Gordon RL, Osorio RW, et al. Ureteral obstructions and leaks after renal transplantation: outcome of percutaneous antegrade ureteral stent placement in 44 patients. *Radiology.* 1998;209(1):159-167.
- Kobayashi K, Censullo ML, Rossman LL, Kyriakides PN, Kahan BD, Cohen AM. Interventional radiologic management of renal transplant dysfunction: indications, limitations, and technical considerations. *Radiographics.* 2007;27(4):1109-1130.
- Philosophe B, Kuo PC, Schweitzer EJ, et al. Laparoscopic versus open donor nephrectomy: comparing ureteral complications in the recipients and improving the laparoscopic technique. *Transplantation.* 1999;68(4):497-502.