



Case Report

Early Maxillary Expansion with the Ni-Ti Memory Leaf Expander-A Compliance-Free Fixed Slow Maxillary Expansion Screw: A Report of 2 Cases

Bahar Ulug¹, Ayça Arman Özçırpıcı¹

¹Department of Orthodontics, Faculty of Dentistry, Baskent University, Ankara, Turkey

Cite this article as: Ulug B, Arman-Özçırpıcı A. Early maxillary expansion with the Ni-Ti memory leaf expander-A compliance-free fixed slow maxillary expansion screw: A report of 2 cases. *Turk J Orthod.* 2021; 34(2): 143-149.

143

ABSTRACT

Transversal problems such as crowding and crossbite are one of the most common problems dealt with in early orthodontic treatments. Early correction of these problems may ease or even eliminate the future need for treatment. This paper presents the management of 2 cases with transverse discrepancy using the Ni-Ti Memory Leaf Expander—a new compliance-free slow maxillary expansion appliance. The total treatment time for both cases was 9 months. In both cases, the inter-canine, inter-premolar, and inter-molar distances, as well as the arch length, have all increased.

Keywords: Non-compliance therapy, leaf expander, posterior crossbite, transverse discrepancy

INTRODUCTION

Transversal problems due to insufficient palatal arch dimension are usually accompanied by upper arch crowding and/or crossbite.¹ Early maxillary expansion treatment allows the permanent teeth to erupt into normal occlusion, eliminating interferences and providing more favorable dental and skeletal changes during growth.² The method used for maxillary expansion may vary depending on the activation frequency, magnitude, and duration of the force applied, and age of the patient.³ Rapid palatal expansion (RPE) is one of the most commonly used methods to treat transversal discrepancies. However, the opening of the mid-palatal suture may sometimes cause discomfort for the patient. On the other hand, slow maxillary expansion (SME) allows more physiological adaptation of the mid-palatal suture and therefore causes less discomfort. Despite applying smaller forces, SME has been shown to have orthopedic effects in growing patients.⁴ Lanteri et al.⁵ compared the volumetric changes in the upper airways after rapid and slow maxillary expansion in growing patients using the Leaf Expander as the SME device. They concluded that effective maxillary expansion can be achieved with SME. Moreover, posterior crossbite correction by SME in mixed dentition has been reported to have 84% stability in permanent dentition.⁶ The Ni-Ti Memory Leaf Expander screw shows similarities in design to conventional rapid palatal expander (RPE) screws. However, unlike a typical RPE screw, it applies constant small force through its double nickel-titanium leaf springs and eliminates the need for parent or patient cooperation as there is no need for home activation. The aim of this paper is to present 2 cases of maxillary expansion using the Leaf Expander to show the treatment results of this new compliance-free expansion method.

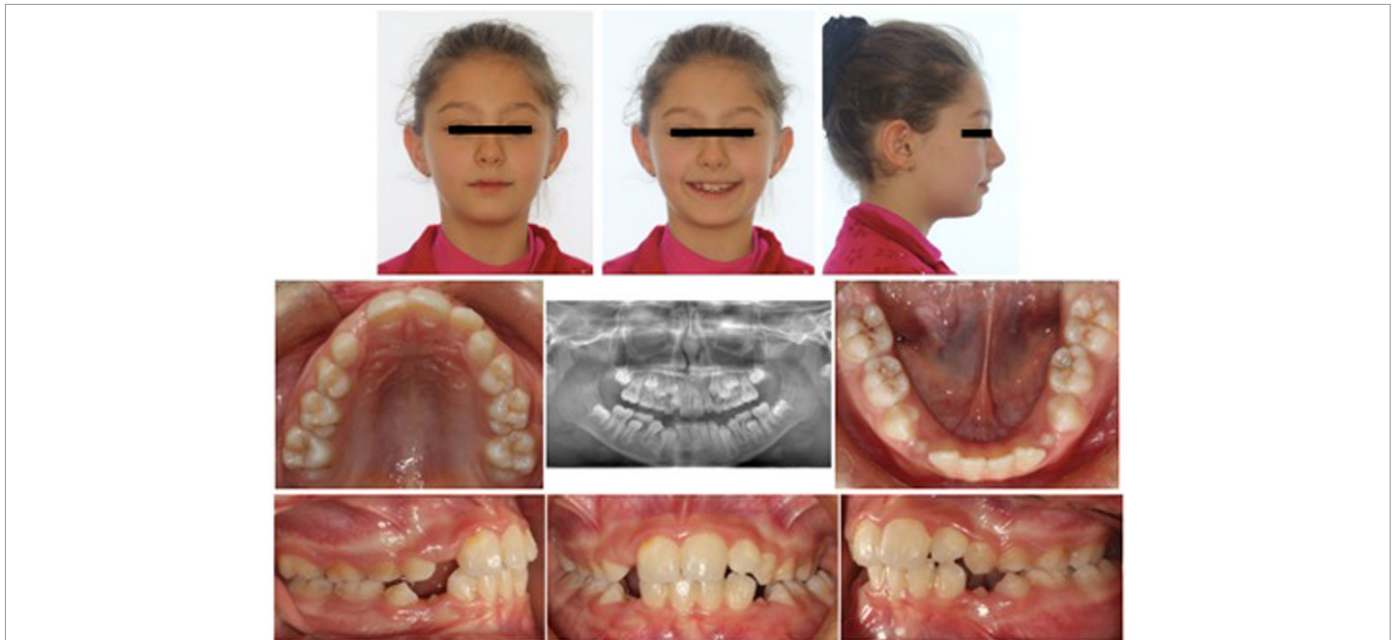

Figure 1. Case 1: An 8-year-old female patient with unilateral posterior crossbite and unerupted lateral incisor.

CASE PRESENTATION

Case 1 Diagnosis

A female patient aged 8 years and 2 months was referred to the Department of Orthodontics with the chief complaint that her lateral incisors had not erupted. After a detailed clinical intra-oral examination, dental radiographs and impressions were taken and a detailed evaluation of the patient was carried out. The patient had moderate crowding, single-tooth crossbite on the left first molar area, and 2.5 mm of dental midline shift to the right on the lower arch. The panoramic radiograph further revealed that the right lateral incisor had failed to erupt due to inadequate space. Lateral cephalometric analysis revealed no skeletal anomalies (Figure 1).

Treatment Goals

Our primary goal was to expand the maxilla and create enough space for the natural eruption of the right lateral incisor, and

simultaneously solve the single-tooth crossbite on the left side. Written informed consent was obtained from the patient's parents.

Treatment Plan and Progress

The Leaf Expander was chosen as the expansion appliance. It was anchored to the deciduous second molars (Figure 2). The Leaf Expander has a double nickel-titanium leaf spring that recovers its shape during deactivation. There is no need for home activation. All the activations were done during the patient's monthly visit to the clinic. The expansion screw was pre-activated in the laboratory to produce 3 mm of expansion, and it was ligated with metal ligatures by squeezing the leaves of the expander before placing it in the patients' mouth. The Leaf Expander was bonded to deciduous teeth and the ligatures were then cut to allow expansion. Our choice of the Leaf Expander screw was 6 mm, which delivers an amount of 450 g force during deactivation. The patient visited the clinic every 4-5 weeks for the activation of the Leaf Expander. During each visit, the screw was activated by 10 quarter-turns until the

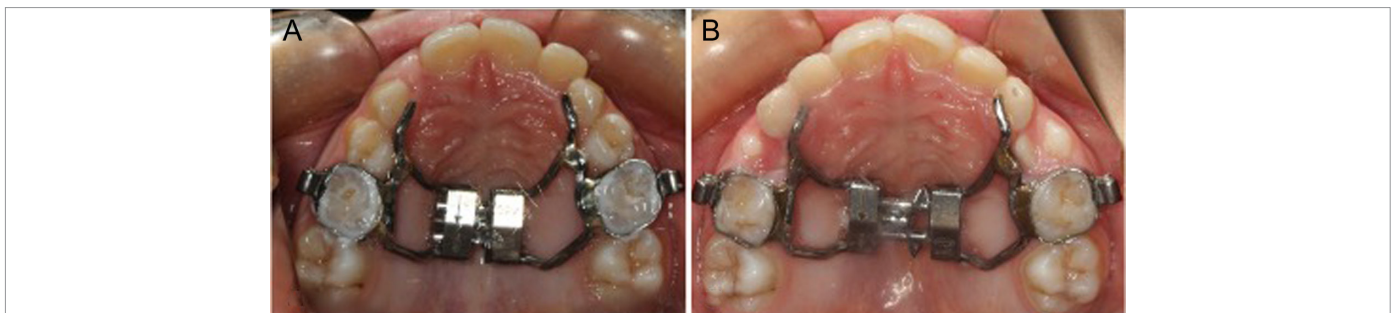


Figure 2. A. Leaf expander in place. B. Leaf Expander after 6 months of active expansion.




Figure 3. Activation protocol for Ni-Ti Memory Leaf Expander. (1, Pre-activated expander screw blocked with metal ligatures in the laboratory; 2, Ligature cut to activate the Nickel-Titanium Leaves. 3, Deactivated Leaf spring indicating expansion is achieved. 4, Leaves re-activated by 10 quarter-turns of the screw to produce 1 mm expansion. 5, Re-activation complete. 6, Additional expansion produced by Leaf spring).

expansion was completed (Figure 3). The maximum number of activations was 30. After the completion of active expansion (6 months), the appliance was kept in place for 3 more months for retention purposes. Therefore, the total treatment lasted 9 months.

Treatment Results

Successful expansion of the maxillary arch was achieved, providing enough space for the right lateral incisor to erupt. The

crossbite on the left side was corrected and lower midline deviation was improved but not fully corrected, as it was mostly a dental problem rather than a functional shift (Figure 4). After the treatment, the pre- and post-treatment dental models were scanned using the 3Shape D700 3D Scanner (Copenhagen, Denmark) and converted to digital models. The digital models were then evaluated using Blender Software Version 2.90. The inter-canine, inter-premolar, and inter-molar distances, as well as the arch length, were all found to have increased (Figure 5 and Table 1).

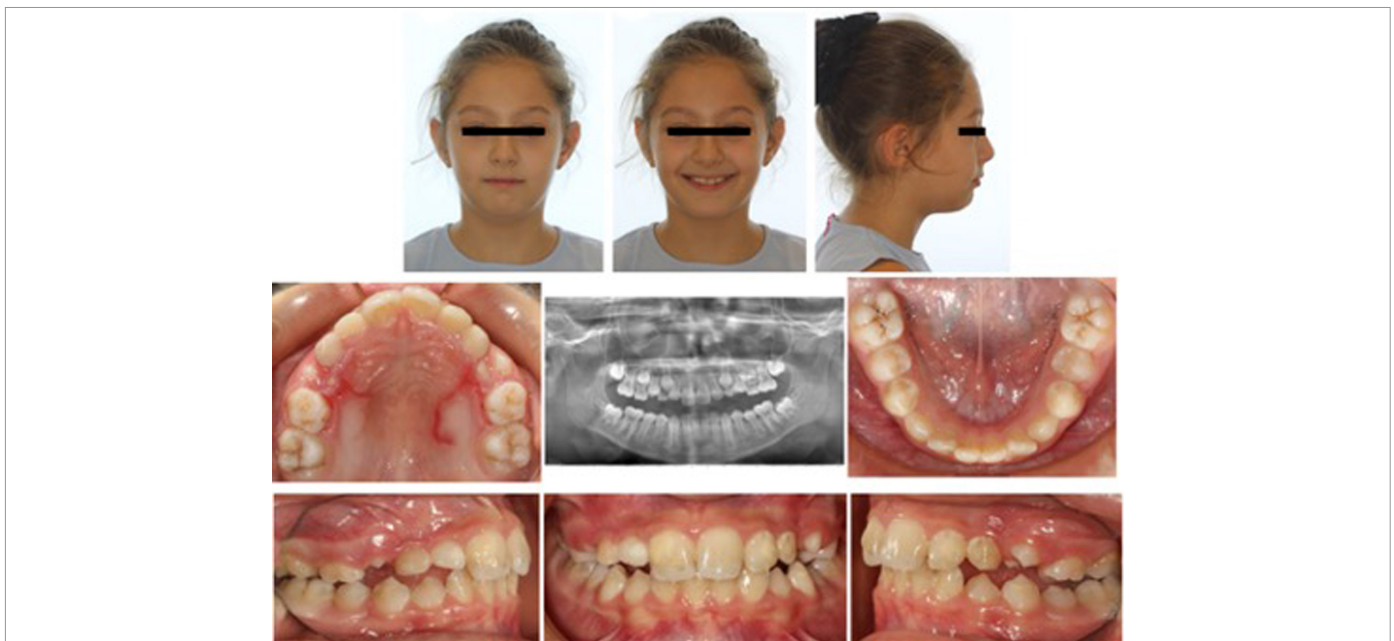

Figure 4. Case 1: Treatment results after 9 months of treatment (6 months of active expansion followed by 3 months of retention) with Ni-Ti Memory Leaf Expander.

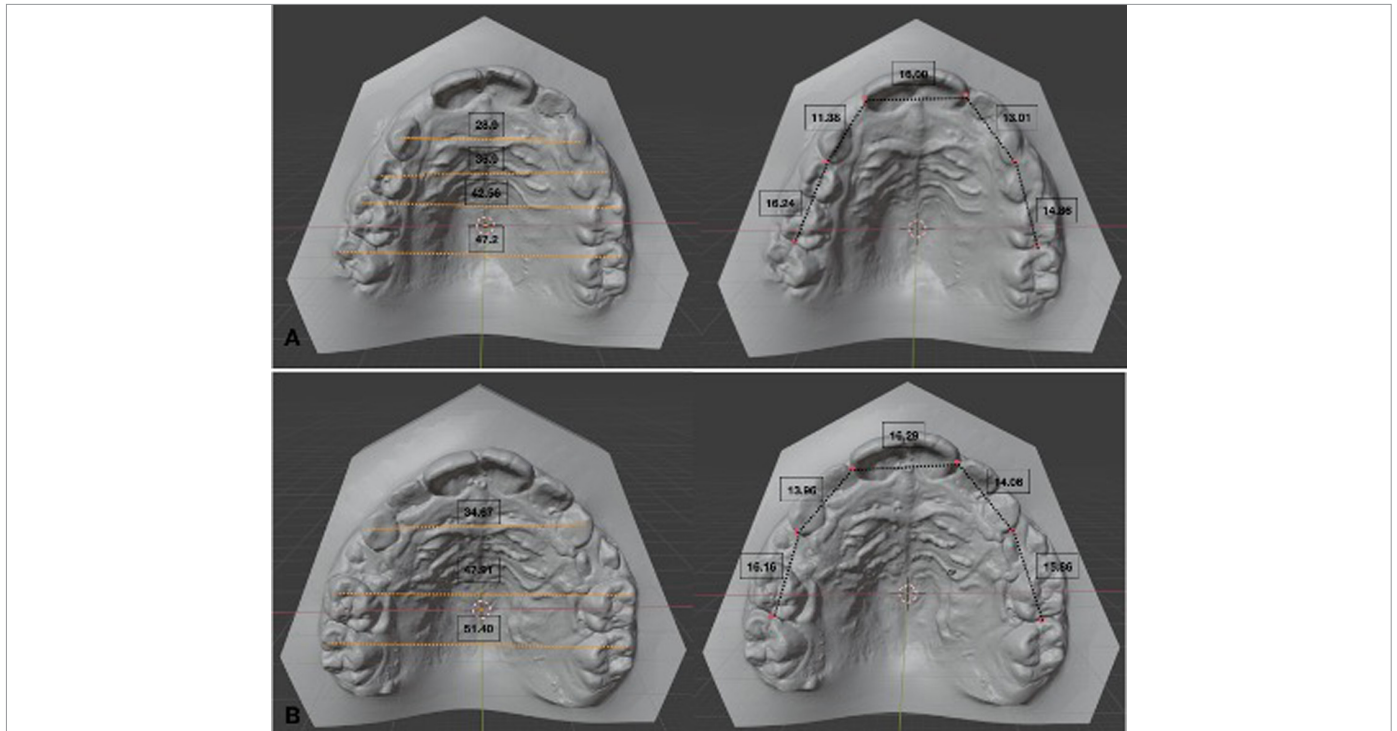


Figure 5. A. Pre-treatment and B. Post-treatment model analyses for Case 1.

Table 1. Arch width and aArch length measurements on STL (Standart Triangle Language) digital casts obtained from patients before and after treatment

Parameter	Case 1		Case 2	
	Pre-treatment, T_0	Post-treatment, T_1	Pre-treatment, T_0	Post-treatment, T_1
III-III (mm)	28.9	34.67	27.37	34.65
IV-IV (mm)	36.9	-	33.57	43.54
V-V (mm)	42.56	47.91	44.10	49.91
6-6 (mm)	47.2	51.40	-	-
Total Arch Length (mm)	71.32	76.37	74.2	79

Case 2 Diagnosis

A 7-year-old male patient was referred to our clinic from the Department of Pediatric Dentistry. The patient was in the early mixed dentition stage. Clinical examination showed the presence of bilateral crossbite in the primary canine region. Both upper and lower midlines were coincident with the facial midline. The patient had a Class I molar relationship on the right side and normal overjet and overbite values. His panoramic radiograph and lateral cephalometric analysis showed no skeletal or alveolar abnormalities, while his posteroanterior radiographs revealed mild transverse deficiency in the upper arch (Figure 6).

Treatment Goals

The primary goal was to widen the maxilla and free the primary canines of the crossbite, providing the necessary space for

permanent teeth to erupt. Written informed consent was taken from the patient’s parents.

Treatment Plan and Progress

The Leaf Expander was chosen as the expansion appliance for maxillary expansion (Figure 7). The same procedures and protocols were applied, as detailed in the above description.

Treatment Results

Expansion of the maxillary arch using the Leaf Expander was achieved, and the bilateral crossbite of the primary canines was corrected (Figure 8). As a result of the maxillary expansion, inter-canine, inter-premolar, and arch length increased (Figure 9 and Table 1); a possible crossbite of the first molars was prevented even though the expansion screw was anchored to the deciduous teeth. The scanning process and

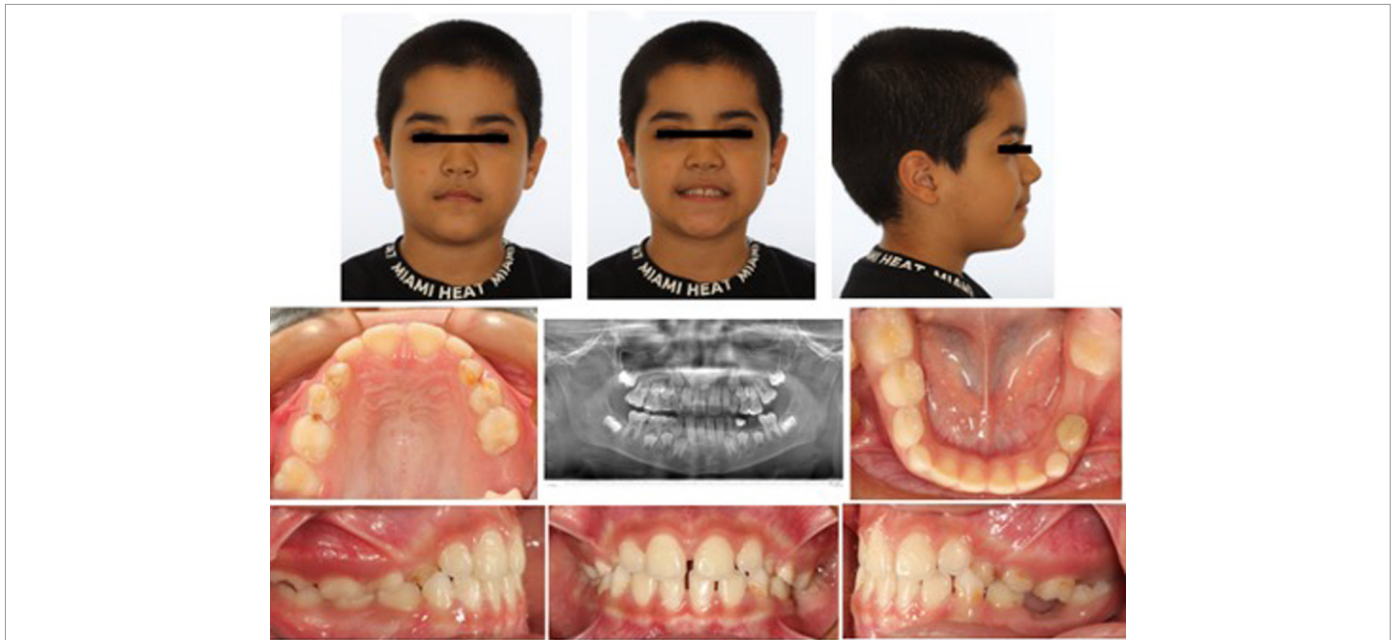


Figure 6. Case 2: A 7-year-old male patient with bilateral crossbite in the primary canine region.

measuring methodology used were the same as described above for Case 1.

DISCUSSION

Early orthodontic intervention is recommended in cases of crossbite and space deficiencies.⁷ Maxillary expansion in mixed dentition allows the permanent teeth to erupt into normal occlusion, providing favorable dental and skeletal changes.⁸⁻¹⁰ Both patients presented in this report were in the early mixed dentition stage, and maxillary expansion with the Leaf Expander was successfully carried out, both correcting the crossbite, and in Case 1, providing enough space for the lateral incisor to erupt.

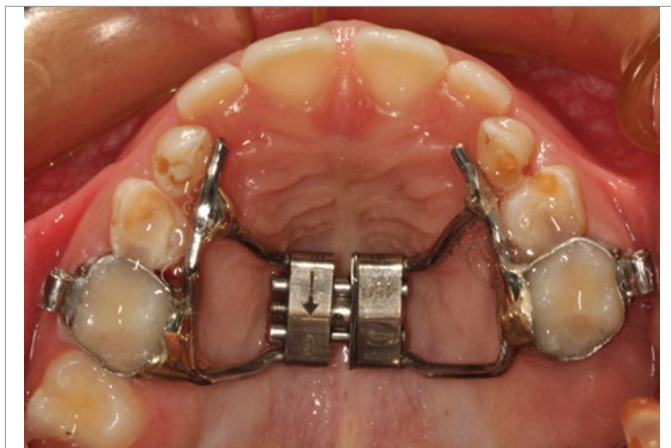

Figure 7. Case 2: Leaf Expander anchored to deciduous molars.

In both cases, the Leaf Expander was bonded to second primary molars. Primary teeth are used as anchorage for the Leaf Expander during early mixed dentition, allowing spontaneous expansion of the permanent molars,¹ whereas the conventional fixed expansion screws are usually anchored to permanent teeth, which has some drawbacks such as buccal tipping, buccal alveolar bone resorption, root resorption, and periodontal damage to the anchorage teeth.¹⁰⁻¹³ In a recent study, it was shown that reduction in buccal bone thickness around permanent molars was insignificant in cases where the Leaf Expander was used as the SME device.¹⁴

Moreover, the compliance-free nature of the Ni-Ti Memory Leaf Expander is a big advantage compared to conventional RPE screws. When the activation is left to parents, they often have difficulty turning the screw because they fear hurting the child, or simply because they cannot locate the hole on the expander screw. Doing away with the home activation process solves this problem and means that the patient does not need to visit the clinic as often.

Another advantage of the Leaf Expander over traditional RPE appliances is that its nickel-titanium leaves apply constant small force, which is easier for the patient to tolerate. In a recent study, it was also shown that the patients experience considerably less pain and discomfort with the Leaf Expander.¹⁵

One may argue that treatment with the Leaf Expander takes more time compared to RPE protocols. However, the overall time of treatment, including the retention period, is similar. It could be criticized that no overcorrection was made for both cases. A drawback of the Leaf Expander is that the capacity of the screw is fixed, and in these cases, it could be said that the 6 mm

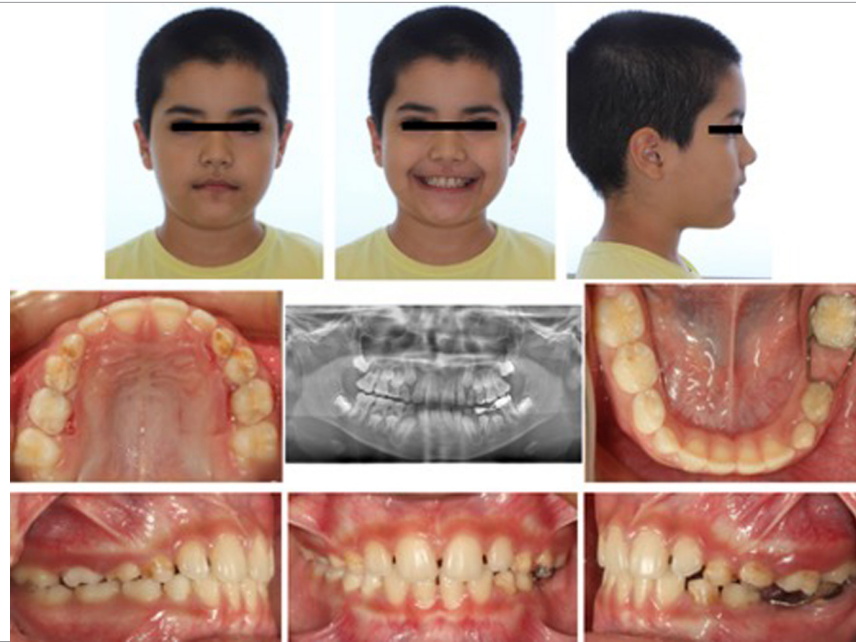


Figure 8. Case 2: Treatment results after 9 months of expansion treatment (6 months of active expansion followed by 3 months of retention) with the Ni-Ti Memory Leaf Expander

148

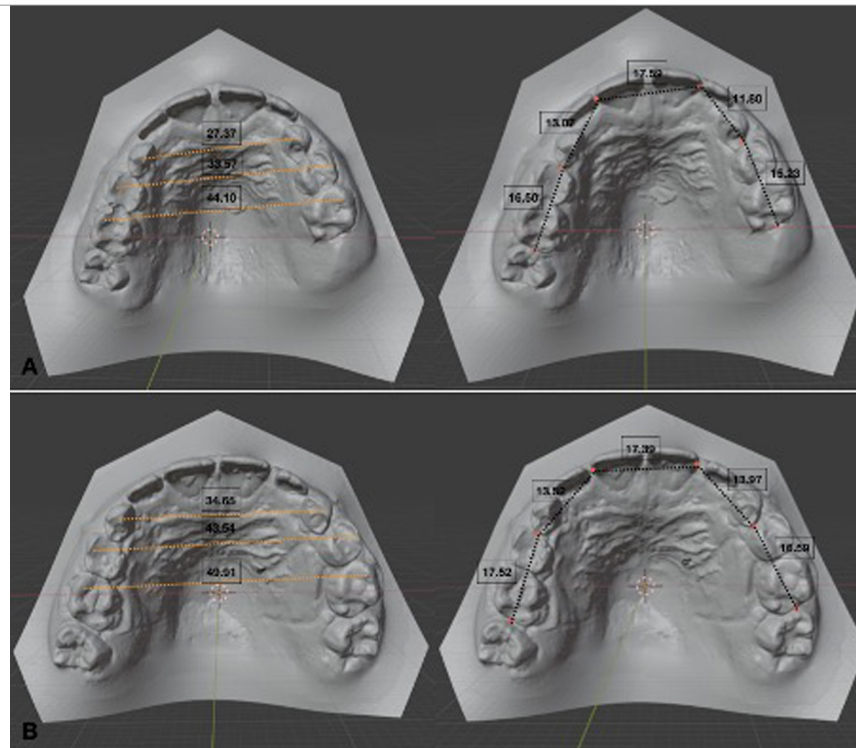


Figure 9 . A. Pre-treatment and B. post-treatment model analyses for Case 2.

expansion screw was inadequate for overcorrection. However, there are more options to choose from, and a wider expansion screw can be chosen if overcorrection is desired.

CONCLUSION

The nickel-titanium Memory Leaf Expander provides a good alternative to conventional RPE screws for maxillary expansion in

mixed dentition. Furthermore, the compliance-free nature of the expander provides an advantage over the conventional expansion screws as it eliminates the need for home activation.

Informed Consent: Written informed consent was obtained from the patients who agreed to take part in the study.

Peer Review: Externally peer-reviewed.

Author Contributions: Conflict of Interest: The authors have no conflict of interest to declare.

Financial Disclosure: The authors declared that this study has received no financial support.

REFERENCES

- Lanteri C, Beretta M, Lanteri V et al. The leaf expander for non-compliance treatment in the mixed dentition. *J Clin Orthod.* 2016;50(9):552-560.
- Bukhari A, Kennedy D, Hannam A, Aleksejūnienė J, Yen E. Dimensional changes in the palate associated with slow maxillary expansion for early treatment of posterior crossbite. *Angle Orthod.* 2018;88(4):390-396. [\[CrossRef\]](#)
- Sandıkçioğlu M, Hazar S. Skeletal and dental changes after maxillary expansion in the mixed dentition. *Am J Orthod Dentofacial Orthop.* 1997;111(3):321-327. [\[CrossRef\]](#)
- Martina R, Cioffi I, Farella M et al. Transverse changes determined by rapid and slow maxillary expansion—a low-dose CT-based randomized controlled trial. *Orthod Craniofac Res.* 2012;15(3):159-168. [\[CrossRef\]](#)
- Lanteri V, Farronato M, Ugolini A et al. Volumetric changes in the upper airways after rapid and slow maxillary expansion in Growing patients: A case-control study. *Materials (Basel).* 2020;13(10):2239. [\[CrossRef\]](#)
- Ciambotti C, Ngan P, Durkee M, Kohli K, Kim H. A comparison of dental and dentoalveolar changes between rapid palatal expansion and nickel-titanium palatal expansion appliances. *Am J Orthod Dentofacial Orthop.* 2001;119(1):11-20. [\[CrossRef\]](#)
- Cozzani M, Rosa M, Cozzani P, Siciliani G. Deciduous dentition-anchored rapid maxillary expansion in crossbite and non-crossbite mixed dentition patients: reaction of the permanent first molar. *Prog Orthod.* 2003;4(1):15-22. [\[CrossRef\]](#)
- Kurul J, Berglund L. Longitudinal study and cost-benefit analysis of the effect of early treatment of posterior cross-bites in the primary dentition. *Eur J Orthod.* 1992;14(3):173-179. [\[CrossRef\]](#)
- Bell RA. A review of maxillary expansion in relation to rate of expansion and patient's age. *Am J Orthod.* 1982;81(1):32-37. [\[CrossRef\]](#)
- da Silva Filho OG, Montes LA, Torelly LF. Rapid maxillary expansion in the deciduous and mixed dentition evaluated through posteroanterior cephalometric analysis. *Am J Orthod Dentofacial Orthop.* 1995;107(3):268-275. [\[CrossRef\]](#)
- Cozzani M, Guiducci A, Mirengi S, Mutinelli S, Siciliani G. Arch width changes with a rapid maxillary expansion appliance anchored to the primary teeth. *Angle Orthod.* 2007;77(2):296-302. [\[CrossRef\]](#)
- Haas AJ. Palatal expansion: just the beginning of dentofacial orthopedics. *Am J Orthod.* 1970;57(3):219-255. [\[CrossRef\]](#)
- Sari Z, Uysal T, Usumez S, Basciftci FA. Rapid maxillary expansion. Is it better in the mixed or in the permanent dentition? *Angle Orthod.* 2003;73(6):654-661. [\[CrossRef\]](#)
- Lanteri V, Cavagnetto D, Abate A et al. Buccal bone changes Around first permanent molars and second primary molars after maxillary expansion with a low compliance Ni-ti leaf spring expander. *Int J Environ Res Public Health.* 2020;17(23):9104. [\[CrossRef\]](#)
- Ugolini A, Cossellu G, Farronato M, Silvestrini-Biavati A, Lanteri V. A multicenter, prospective, randomized trial of pain and discomfort during maxillary expansion: leaf expander versus hyrax expander. *Int J Paediatr Dent.* 2020;30(4):421-428. [\[CrossRef\]](#)