

Intrapelvic low grade leiomyosarcoma with good prognosis

B. Serdar¹, K. Meral², S. Ugur³, D. Binnaz⁴, D. Namık⁵

¹Department of Gynecology and Obstetrics, Baskent University, Ankara ²Department of Pathology, Dokuz Eylul University, Izmir 35000

³Department of Gynecology and Obstetrics, Dokuz Eylul University, Izmir 35000 ⁴Department of Internal Disease, Dokuz Eylul University, Izmir 35000 ⁵Department of Gynecology and Obstetrics, Kent Hospital, Izmir 35000 (Turkey)

Summary

Soft tissue sarcomas (STS) are rare mesenchymal neoplasms arising from nonepithelial connective tissue origins. Retroperitoneal soft tissue sarcomas may be primary tumours or metastases especially from the uterus. Here, the authors present a case of intrapelvic leiomyosarcoma treated with hormone therapy after surgery. A 40-year-old multiparous woman was admitted to the hospital with abdominal pain. Abdominopelvic ultrasound was performed, and an uncircumscribed mass was seen in the Douglas pouch. At laparotomy, a tumour measuring 7 cm in size, appearing as a sarcoma attached to the sigmoid colon serosa was found. The tumour was positive with H-caldesmon, actin, desmin, oestrogen and progesterone receptors (ER/PR). The patient with a diagnosis of low-grade intrapelvic leiomyosarcoma received adjuvant hormone therapy after adjuvant radiotherapy. She is doing well without disease recurrence during a two-year follow-up period. Despite contradictory data according to recent limited investigations, the present authors suggest that ER and PR should be routinely quantified in STS by immunohistochemical methods, and it should be kept in mind that hormone therapy may be a beneficial option.

Key words: Intrapelvic leiomyosarcoma; Tumour receptors; Hormone therapy.

Introduction

Soft tissue sarcomas (STS) are rare mesenchymal neoplasms arising from nonepithelial connective tissue origins. STS are a heterogeneous group of tumours with a wide range of clinical features, behaviours and prognoses. STS represent only 1% of human malignancies, and retroperitoneal and abdominal/visceral STS account for one-third of all STS [1]. Retroperitoneal STS may be primary tumours or metastases especially from the uterus. Indeed, they still remain a challenging clinical problem. Their tendency for locally advanced disease at presentation, difficulty to resect with widely clear margins and predilection for local recurrences contribute to the complexity of their clinical management. Single-centre series have demonstrated five-year overall survival rates ranging from 36% to 57% [2, 3]. However, only a few patients are ultimately cured. The mitotic rate, presence of atypia and coagulative tumour necrosis have been used as criteria, and tumours with such features in any combination have a high risk of recurrence and metastasis. Here, the authors present a case of intrapelvic leiomyosarcoma treated with hormone therapy after surgery.

Case Report

A 40-year-old multiparous woman was operated for an endometriotic cyst in 2001. Endometriosis was detected on the tubal serosa. In May 2008, she was admitted to the hospital with abdominal pain. Abdominopelvic ultrasound was performed, and an uncircumscribed mass was seen in the Douglas pouch. Magnetic resonance imaging also revealed

the same findings. The mass was uncircumscribed and removed (Figure 1A). Total abdominal hysterectomy, bilateral salpingo-oophorectomy and total omentectomy (under suspicion of extra-gastrointestinal stromal tumour) were performed. At laparotomy, a tumour measuring 7 cm in size, appearing as a sarcoma attached to the sigmoid colon serosa was observed. Intraoperative frozen section diagnosis was reported as leiomyosarcoma. The foci of endometriosis were also seen on colonic serosal surfaces. After the postoperative period, she was discharged from the hospital as healthy, and routine follow-up appointment was arranged for her.

The mass consisted of spindle cells. Necrosis and 3 mitoses per 50HPF were seen (Figures 1B-G). The tumour involvement was microscopically seen in the omentum and sigmoid colon serosa. There was only adenomyosis in the uterus (Figures 2A, B). The tumour was positive with actin, desmin, oestrogen and progesterone receptors (ER/PR), h-caldesmon, CD10 (in some cells), WT-1 and negative with CD117, CD34, s-100 and myoglobin (Figure 3). The final diagnosis was low-grade extrauterine leiomyosarcoma. To evaluate the patient with a suspected spread to distant organs, the authors arranged appropriate body-scans, and there was no metastasis.

The patient with a diagnosis of low-grade intrapelvic leiomyosarcoma received adjuvant hormone therapy after adjuvant radiotherapy. After eight months of therapy, the patient gave up hormone therapy (based on her own decision) in consequence of occurring diabetes mellitus. Because of tumoral expression of ER/PR, megestrol acetate 160 mg/day from the peroral route was recommended. She

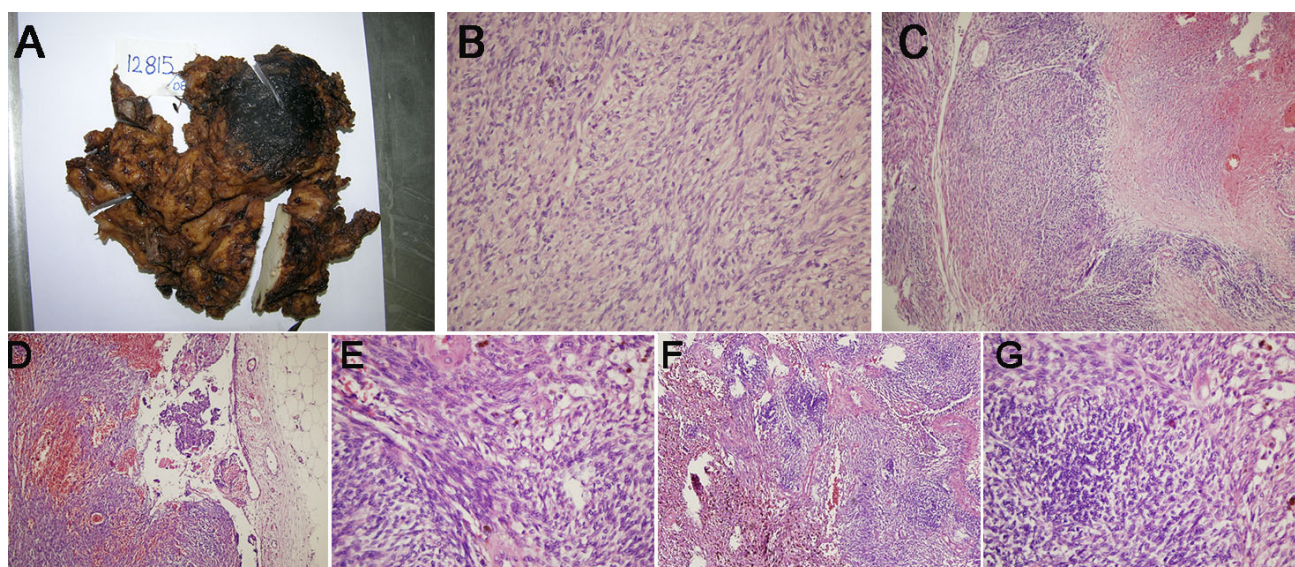


Figure 1. — A: Uncircumscribed mass in Douglas pouch; B: Cellular findings of the mass; C: Cellular findings of the mass; D: Cellular findings of the mass; E: Cellular findings of the mass; F: Cellular findings of the mass; 1G: Cellular findings of the mass.

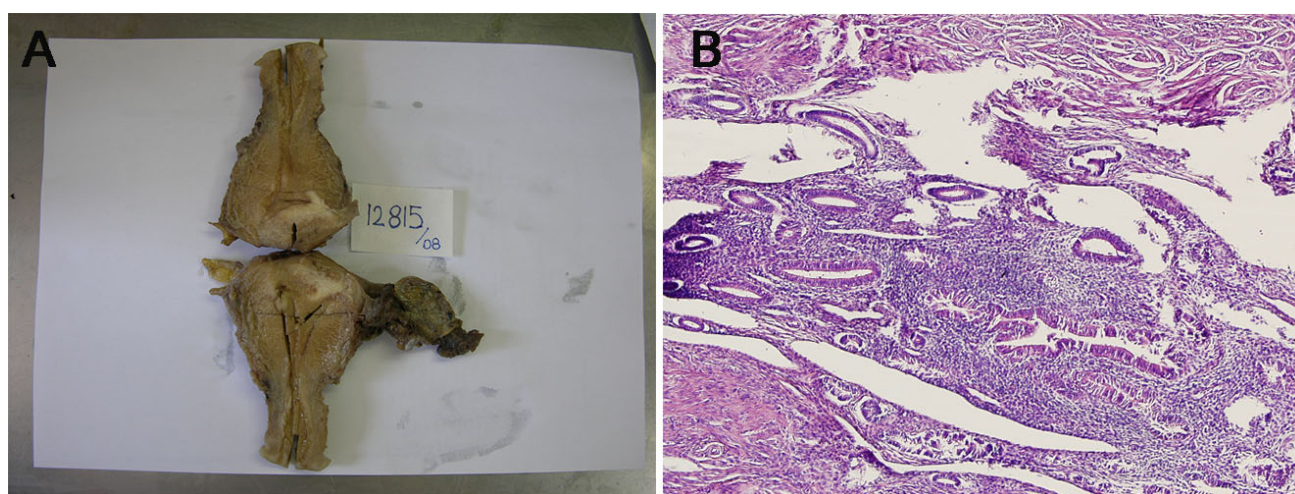


Figure 2. — A: Adenomyosis in the uterus; B: Cellular findings of adenomyosis.

is doing well without disease recurrence during a six-year follow-up period.

Discussion

Tumour size is considered to be one of the most important prognostic factors in STS [4]. The retroperitoneum and abdominal cavity have such a large capacity that tumours can grow without exhibiting any symptoms or recognizable signs in conventional physical examination. This feature, along with their generally non-invasive and slow growth, as well as the paucity of symptoms, contributes to a late presentation and a far-advanced stage at diagnosis. Consequently, STS in the retroperitoneum and abdominal cavity tend to be relatively large, resulting comparatively in poor prognoses. However, there is an increasing belief among some researchers that histologic type and grade indepen-

dently impact the prognosis in STS [4, 5].

Liposarcoma and leiomyosarcoma are the major STS in the retroperitoneum and abdominal cavity [2]. Liposarcomas are larger tumours than leiomyosarcomas, but their biological malignant potential is also lower. Another point is that most liposarcomas recur at local sites, and distant metastases are rare. Thus, aggressive surgical resection of local recurrence may result in the long-term survival of patients with retroperitoneal and abdominal liposarcomas. Retroperitoneal leiomyosarcomas are more common at older ages and in women and are usually large, often > 100 mm, when diagnosed. They usually have poor prognosis due to high recurrence and metastatic rates, despite sometimes having relatively low mitotic indices. In one study, all tumours had at least 3 mitoses/10 HPF, and 15 of 17 patients (including all five patients with grade 1 tu-

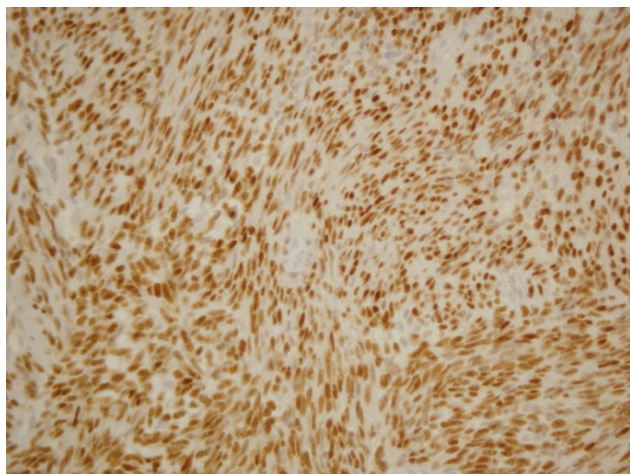


Figure 3. — The tumour was positive for oestrogen receptors.

mours) died of tumour or had metastatic disease during a median follow-up of 3.5 years [6].

The variable outcome of leiomyosarcomas may be related to different therapeutic approaches: excision, enucleation and curettage or radical surgery have been advocated as treatment options. After the standard surgical approach, pelvic radiation therapy was used for adjuvant treatment of leiomyosarcomas [6]. However, although radiation therapy has been shown to reduce the pelvic relapse rate by 50%, studies have not demonstrated a significant survival benefit with this approach. No adjuvant chemotherapy has been shown to improve survival in leiomyosarcomas. In any case, based on some recent limited data, combinations of medications such as gemcitabine, docetaxel and trabectedin merit further evaluation in prospective trials of adjuvant treatment [7]. Endocrine therapy may represent an opinion in chemotherapy or radiation therapy pre-treated patients with hormone receptor positive tumours. Most extrauterine LMSs have no expression of oestrogen and/or progesterone receptors [7, 8]. However, a subset of extrauterine LMSs show positive immunoreactivity for ER and PR. Hormonotherapy may be beneficial in management of these subgroups of patients. Despite contradictory data according to recent limited investigations, the authors suggest that ER and PR should be routinely quantified in STS by immunohistochemical methods, and it should be kept in mind that hormone therapy may be a beneficial option.

Author contributions

B. Serdar was in charge of conception and design of article, analysis and interpretation of data, drafting of the manuscript, statistical analysis. K.Meral acquired the data. S.Ugur was responsible for critical revision of the manuscript for important intellectual content. C.Binnaz administered technical or material support. D. Namik supervised.

Ethics approval and consent to participate

The study were obtained with the informed consent of all participants. The institutional review board of the Eylul University Medical Faculty Ethics committee approved, code 32.

Acknowledgments

Thank numerous individuals participated in this study.

Conflict of interest

The authors declare no conflict of interest.

Submitted: January 15, 2018

Accepted: October 17, 2019

Published: June 15, 2020

References

- [1] Nishimura J., Morii E., Takahashi T., Souma Y., Nakajima K., Doki Y., *et al.*: "Abdominal soft tissue sarcoma: a multicenter retrospective study". *Int. J. Clin. Oncol.*, 2010, 15, 399.
- [2] Anaya D.A., Lahat G., Wang X., Xiao L., Pisters P.W., Cormier J.N.: "Postoperative nomogram for survival of patients with retroperitoneal sarcoma treated with curative intent". *Ann. Oncol.*, 2010, 21, 397.
- [3] Lewis J.J., Leung D., Woodruff J.M., Brennan M.F.: "Retroperitoneal soft-tissue sarcoma: analysis of 500 patients treated and followed at a single institution". *Ann. Surg.*, 1998, 228, 355.
- [4] Tseng W., Martinez S.R., Tamurian R.M., Borys D., Canter R.J.: "Histologic type predicts survival in patients with retroperitoneal soft tissue sarcoma". *J. Surg. Res.*, 2012, 172, 123.
- [5] Verweij J., Baker L.H.: "Future treatment of soft tissue sarcomas will be driven by histological subtype and molecular aberrations". *Eur. J. Cancer*, 2010, 46, 863.
- [6] Miettinen M., Fetsch J.F.: "Evaluation of biological potential of smooth muscle tumours". *Histopathology*, 2006, 48, 97.
- [7] Amant F., Coosemans A., Debiec-Rychter M., Timmerman D., Vergote I.: "Clinical management of uterine sarcomas". *Lancet Oncol.*, 2009, 10, 1188.
- [8] Zagouri F., Dimopoulos A.M., Fotiou S., Christos V.K., Papadimitriou A.: "Treatment of early uterine sarcomas: disentangling adjuvant modalities". *World J. Surg. Oncol.*, 2009, 7, 38.

Corresponding Author:

S. BALCI, M.D.

1819 sokak no: 4 d: 9

Karsiyaka, 35000 Izmir (Turkey)

e-mail: serdarbal@hotmail.com