



Elastofibroma dorsi: A case report on an unobserved cause of back pain

Şükran Güzel, MD¹, Selin Özen, MD¹, Seyhan Sözyay, MD¹, Mehmet Dalokay Kılıç, MD²

¹Department of Physical Medicine and Rehabilitation, Başkent University Faculty of Medicine, Ankara, Turkey

²Department of Thoracic Surgery, Başkent University Faculty of Medicine, Ankara, Turkey

Elastofibroma dorsi (ED) is a rare benign soft tissue tumor characterized by fibrous and adipose tissue proliferation in the infrascapular region which is usually seen in elderly females.^[1] Even though the prevalence of ED is estimated at 2%, it is generally asymptomatic, mostly goes undiagnosed and clinical reports are scarce. Indeed, retrospective computed tomography (CT) and autopsy studies have shown a prevalence of 11-24% in those over the age of 55.^[2-4]

Inevitably, the general asymptomatic nature of ED can mean that this diagnosis is not at the forefront of our minds when presented with a case of persistent back and shoulder pain. In this article, we present a patient with progressively worsening back and shoulder pain present for more than 10 years, who was unsuccessfully treated, in which a diagnosis of ED was missed.^[5]

ABSTRACT

Elastofibroma dorsi (ED) is a rare, benign soft tissue tumor which often occurs in the subscapular region of elderly individuals and shows a female predominance. While many patients remain asymptomatic, ED can cause pain in the periscapular region. The clinical signs of ED are non-specific and variable which can result in misdiagnoses; it is often confused with rotator cuff and cervical spine pathologies. In this article, we present the case of a 78-year-old female patient with persistent back and shoulder pain. The patient was admitted to various clinics over a number of years for diagnostic investigations and treatment. However, the true etiology of back pain was never established and treatments were applied without any positive effect. Finally, when the patient presented to our clinic, a mass was detected in the right subscapular region. Thoracic computed tomography imaging was consistent with a diagnosis of ED. Due to the patient's persistent back pain, surgical excision of the tumor was performed. The pathology report confirmed the diagnosis. This case emphasizes the importance of a thorough examination in patients who may initially only have very subtle signs of the underlying pathology. This case also highlights the importance of re-visiting initial evaluations and differential diagnoses when faced with a difficult case of persistent back and shoulder pain so to avoid misdiagnoses and unnecessary treatments.

Keywords: Back pain, benign neoplasms, diagnostic errors.

Received: March 20, 2020

Accepted: April 09, 2020

Published online: September 11, 2020

Correspondence: Şükran Güzel, MD, Başkent Üniversitesi Tıp Fakültesi Fiziksel Tıp ve Rehabilitasyon Anabilim Dalı, 06490 Bahçelievler, Ankara, Türkiye.

E-mail: sukranguzel@windowslive.com

Doi: 10.5606/ehc.2020.74955

Citation: Güzel Ş, Özen S, Sözyay S, Dalokay Kılıç M. Elastofibroma dorsi: A case report on an unobserved cause of back pain. Jt Dis Relat Surg 2020;31(3):644-647.

©2020 All right reserved by the Turkish Joint Diseases Foundation

This is an open access article under the terms of the Creative Commons Attribution-NonCommercial License, which permits use, distribution and reproduction in any medium, provided the original work is properly cited and is not used for commercial purposes (<http://creativecommons.org/licenses/by-nc/4.0/>).

CASE REPORT

A 78-year-old female patient presented to the outpatient clinic with a 10-year history of back and right shoulder pain. The pain could be localized to a single point, did not radiate to the extremities and increased at night. The etiology of the pain had previously been investigated in the physical medicine and rehabilitation, chest diseases, neurology and algology departments of various hospitals. To date, investigations included routine blood tests and multiple radiographs, CTs and magnetic resonance imaging (MRI) of the

thorax which were unremarkable. Treatment over the years included nonsteroidal anti-inflammatory drugs, physical therapy, trigger point injections, neural therapy, ozone therapy, acupuncture for musculoskeletal pain and antiepileptics and serotonin norepinephrine reuptake inhibitors for neuropathic pain. Right paravertebral nerve blocks had also been performed. Despite these treatments, the pain had steadily increased. The patient's past medical history of note included diabetes mellitus and hypertension.

Physical examination revealed a solid mass in the right subscapular region, approximately 10 cm in size, which was adherent to the deep subcutaneous layers and tender on palpation. The mass was more prominent on ipsilateral arm abduction.

The CT imaging of the thorax revealed a poorly defined soft-tissue mass with attenuation similar to that of the adjacent muscle tissue mass in the right thoracic wall (Figure 1). It was later discovered that a similar lesion was present in the same location three years previously. The thoracic surgery department was consulted. A preliminary diagnosis of ED was established based on the physical examination findings and CT imaging. Due to the patient's persistent pain, which considerably affected her quality of life, the mass was surgically excised. Macroscopically, the mass was approximately 13.5×8.7×2.7 cm in size (Figure 2) and histochemical analysis findings were consistent with a diagnosis of ED. The patient's back pain significantly decreased following surgery. A

written informed consent was obtained from the patient.

DISCUSSION

Elastofibroma dorsi is a slow-growing, rare, benign connective tissue tumor first defined by Jarvi and Saxen in 1961^[6] which represents 1-2% of all primary tumors of the chest wall.^[7] Elastofibroma dorsi is typically found situated adjacent to the periosteum of the sixth, seventh, and eighth ribs deep to the latissimus dorsi, rhomboids, or serratus anterior muscles, as was the case here.

On clinical examination, ED is often asymptomatic and discovered incidentally;^[8,9] small tumors only become visible when they reach a size above 5 cm.^[10]

When symptoms are present, they are usually mild, consisting of pain and/or clicking, snapping, or clunking of the scapula with movement. A painful scapula is only observed in 10%.^[11] For these reasons, the differential diagnosis of ED often consists of a whole variety of pathologies including rotator cuff impingement and tears.^[12-15]

In this case, the patient was one of the rare few who suffered from shoulder and back pain due to ED. Not only were the symptoms of back and right shoulder pain significant enough to affect the patient's quality of life, they had become progressively worse over time and were even affecting her sleep quality. Despite this, the diagnosis of ED was overlooked. The

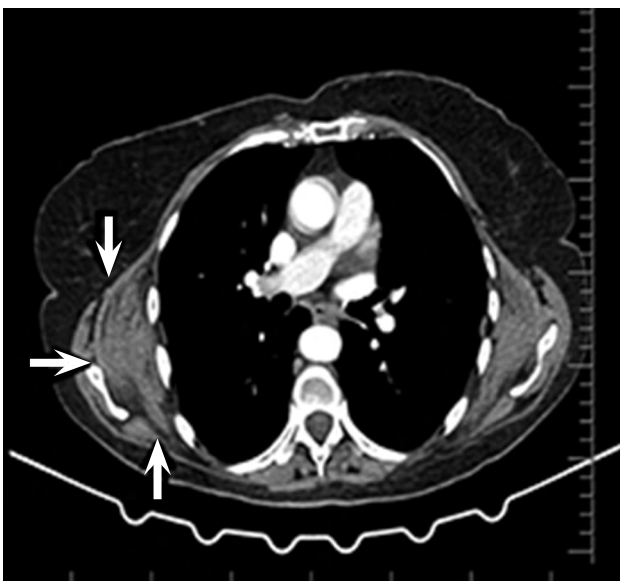

FIGURE 1. Thorax computed tomography.

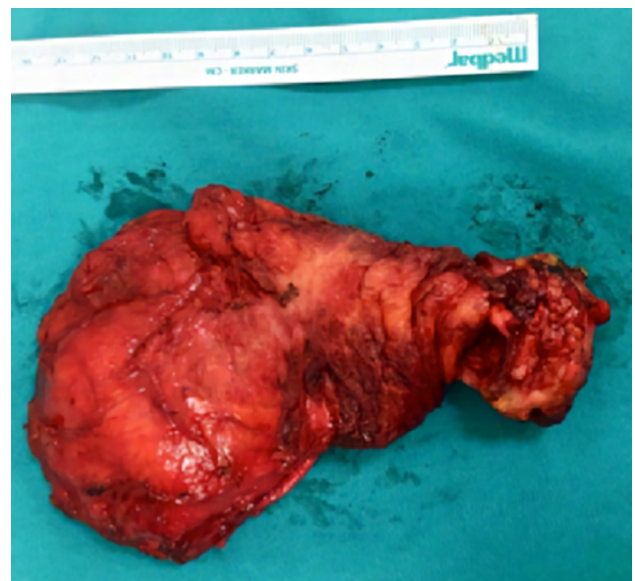

FIGURE 2. Postoperative macroscopic appearance of mass.

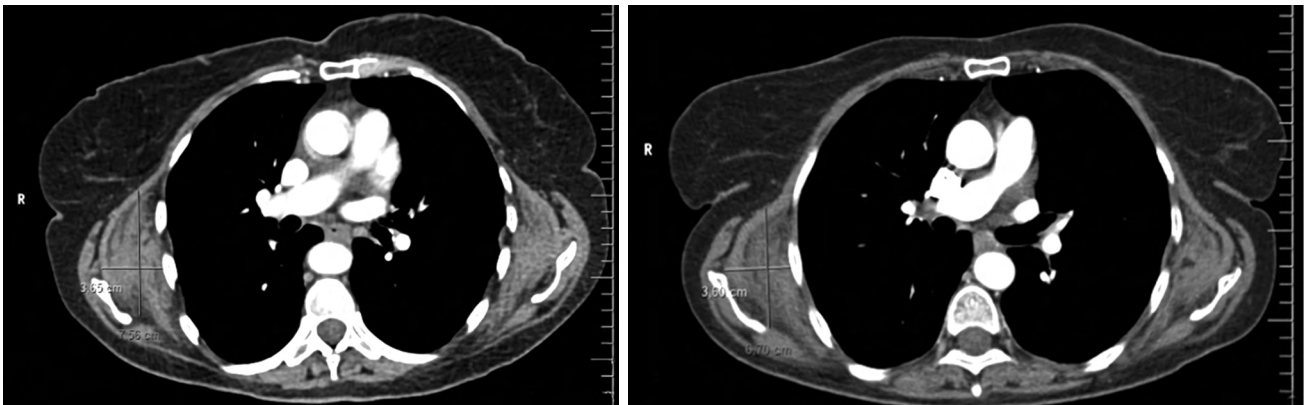


FIGURE 3. Thorax computed tomography; years 2015 vs. 2018.

patient was evaluated by a number of different specialists in different fields and a great number of investigations were performed. This highlights that ED is a diagnosis which must be considered in the differential diagnosis of patients presenting with dorsalgia and shoulder pain not only by chest surgeons, but also by physical medicine and rehabilitation specialists, rheumatologists, chest physicians and even neurologists.

In the past, ED has been misdiagnosed as a rotator cuff tear and subacromial bursitis. In the present case, the patient was treated for adhesive capsulitis of the shoulder and impingement syndrome as well as non-specific musculoskeletal pain for many years prior to the achievement of the correct diagnosis. Not to mention the possible harmful side effects of treatment following misdiagnosis; physical therapy has been reported to accelerate ED tumor growth.^[16]

Eventually, a number of complimentary therapies were also used. Even so, the presence of the tumor on CT imaging obtained three years previously (Figure 3) suggests that physicians had neglected to systematically re-evaluate investigation findings, a problem which many physicians face in cases of undiagnosed chronic pain.

In conclusion, although ED is a rare clinical entity, it should be remembered when evaluating refractory shoulder and back pain and included in its differential diagnosis. This case also reminds us that a meticulous physical examination should be performed and investigatory tests should be reviewed, particularly in the over 50 age group, in which a diagnosis of ED can be confused with commonly occurring shoulder and vertebral problems.

Declaration of conflicting interests

The authors declared no conflicts of interest with respect to the authorship and/or publication of this article.

Funding

The authors received no financial support for the research and/or authorship of this article.

REFERENCES

1. Patnayak R, Jena A, Settipalli S, Nagesh N. Elastofibroma: An Uncommon Tumor Revisited. *J Cutan Aesthet Surg* 2016;9:34-7.
2. Hoven-Gondrie ML, Ijpma FF, Havenith MG, van Geldere D. Elastofibroma dorsii: a characteristic, benign, subscapular swelling. *Ned Tijdschr Geneesk* 2009;153:A569.
3. Suliman MS, Higginbotham ZS, Amro A, McCorkle C, Saunders E. Elastofibroma dorsii: A rare connective tissue tumor. *Cureus* 2020;12:e6874.
4. Järvi OH, Lämsimies PH. Subclinical elastofibromas in the scapular region in an autopsy series. *Acta Pathol Microbiol Scand A* 1975;83:87-108.
5. Atik OŞ. Which articles do we prefer to publish? *Eklemler Hastalıkları Cerrahisi* 2018;29:1.
6. Jarvi O, Saxen E. Elastofibroma dorsii. *Acta Pathol Microbiol Scand Suppl* 1961;51(Suppl 144):83-4.
7. Freixinet J, Rodríguez P, Hussein M, Sanromán B, Herrero J, Gil R. Elastofibroma of the thoracic wall. *Interact Cardiovasc Thorac Surg* 2008;7:626-8.
8. Goyal P, Gandhi D, Gupta S, Li S, Kumar Y, Olsavsky TD, et al. Elastofibroma dorsii. *Proc (Bayl Univ Med Cent)* 2017;30:340-2.
9. Pilge H, Hesper T, Holzapfel BM, Prodinger PM, Straub M, Krauspe R. Elastofibroma: clinical results after resection of a rare tumor entity. *Orthop Rev (Pavia)* 2014 16;6:5329.
10. Kara M, Dikmen E, Kara SA, Atasoy P. Bilateral elastofibroma dorsii: proper positioning for an accurate diagnosis. *Eur J Cardiothorac Surg* 2002;22:839-41.
11. Dlimi M, Boukind S, Elatiqi O, Elamrani D, Benchamkha Y, Ettalbi S. Tumor subscapularis: bilateral dorsal elastofibroma - about a case. *Pan Afr Med J* 2015;21:43.

12. Majó J, Gracia I, Doncel A, Valera M, Núñez A, Guix M. Elastofibroma dorsi as a cause of shoulder pain or snapping scapula. *Clin Orthop Relat Res* 2001;388:200-4.
13. Parratt MT, Donaldson JR, Flanagan AM, Saifuddin A, Pollock RC, Skinner JA, et al. Elastofibroma dorsi: management, outcome and review of the literature. *J Bone Joint Surg [Br]* 2010;92:262-6.
14. El Hammoumi M, Qtaibi A, Arsalane A, El Oueriachi F, Kabiri el H. Elastofibroma dorsi: clinicopathological analysis of 76 cases. *Korean J Thorac Cardiovasc Surg* 2014;47:111-6.
15. Doğruoz Karatekin B, Yaşın Ş, İçağasıoğlu A. Bilateral and atypical localized elastofibroma dorsi in a patient with shoulder and back pain: A case report. *Turk J Phys Med Rehabil* 2019;65:287-9.
16. Tokat AO, Karasu S, Turan A, Gözel S. Rapid enlargement of elastofibroma dorsi after physical therapy. *Ann Thorac Surg* 2011;91:1622-4.