

Commentary on: "Evaluation of variations in sinonasal region with computed tomography"

Can A Çağıcı

Can A Çağıcı, ENT Department, Baskent University Seyhan Hospital, 01150 Adana, Turkey

Author contributions: Çağıcı CA designed research, performed research, analyzed data, wrote the letter, and revised the letter.

Conflict-of-interest statement: The author declares that he has no conflicts of interest.

Open-Access: This article is an open-access article which was selected by an in-house editor and fully peer-reviewed by external reviewers. It is distributed in accordance with the Creative Commons Attribution Non Commercial (CC BY-NC 4.0) license, which permits others to distribute, remix, adapt, build upon this work non-commercially, and license their derivative works on different terms, provided the original work is properly cited and the use is non-commercial. See: <http://creativecommons.org/licenses/by-nc/4.0/>

Manuscript source: Unsolicited manuscript

Correspondence to: Can A Çağıcı, MD, Associate Professor, ENT Department, Baskent University Seyhan Hospital, Gazipaşa Mahallesi Baraj Caddesi No. 7, Seyhan, 01150 Adana, Turkey. ccagici@hotmail.com
Telephone: +90-542-6878525
Fax: +90-322-4592622

Received: July 29, 2016

Peer-review started: July 31, 2016

First decision: September 2, 2016

Revised: September 19, 2016

Accepted: October 17, 2016

Article in press: October 18, 2016

Published online: December 28, 2016

Abstract

This letter is a commentary on the article titled "Evaluation of variations in sinonasal region with computed tomography", published in the January 2016 issue of World Journal of Radiology. The authors definition of the secondary middle turbinate is incorrect. The authors

stated that the secondary middle turbinate is an accessory turbinate that is seen between the superior and middle turbinates. It should originate from the middle meatus posterosuperior to the ethmoid infundibulum.

Key words: Anatomic variations; Secondary middle turbinate; Concha; Paranasal sinus; Tomography

© **The Author(s) 2016.** Published by Baishideng Publishing Group Inc. All rights reserved.

Core tip: This letter is a commentary on the article titled "Evaluation of variations in sinonasal region with computed tomography," published in the January 2016 issue of World Journal of Radiology. The authors evaluated the paranasal sinus tomography of 400 patients to determine the frequency of 39 anatomic variations. Their study required a great deal of time and effort. Unfortunately, their definition of the secondary middle turbinate and the figure that showed its structure are incorrect. It should originate, however, from the middle meatus posterosuperior to the ethmoid infundibulum, not from between the middle and superior turbinates.

Çağıcı CA. Commentary on: "Evaluation of variations in sinonasal region with computed tomography". *World J Radiol* 2016; 8(12): 933-934 Available from: URL: <http://www.wjgnet.com/1949-8470/full/v8/i12/933.htm> DOI: <http://dx.doi.org/10.4329/wjr.v8.i12.933>

TO THE EDITOR

I read the article by Dasar *et al*^[1] with great interest. The authors evaluated the paranasal sinus tomography of 400 patients to determine the frequency of each of 39 possible anatomic variations. Their study required a great deal of time and effort. Unfortunately, their

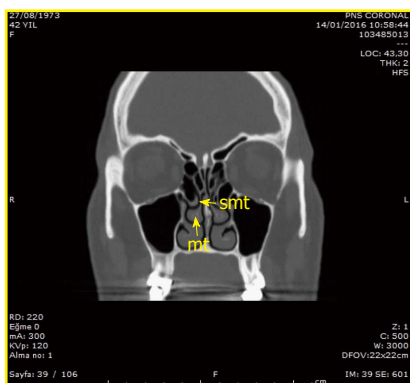


Figure 1 Secondary middle turbinate is apparent on the right side of the figure. smt: Secondary middle turbinate; mt: Middle turbinate.

definition of the secondary middle turbinate and the figure that showed its structure are incorrect.

The authors stated that the secondary middle turbinate is an accessory turbinate that is seen between the superior and middle turbinates^[1]. It should originate, however, from the middle meatus posterosuperior

to the ethmoid infundibulum, not from between the middle and superior turbinates^[2]. The secondary middle turbinate is not part of the middle turbinate. The appearance of a secondary middle turbinate is probably due to the partial absence of the anterior wall of the ethmoidbulla^[2].

Their figure 3D, which was used to illustrate the secondary middle turbinate, is also not appropriate. A sagittal cleft on the middle turbinate is seen in this figure, which is not an appropriate example for the secondary middle turbinate. The secondary middle turbinate is actually a bony prominence that extends from the lateral nasal wall to the middle meatus, as shown in Figure 1^[2].

REFERENCES

- 1 **Dasar U**, Gokce E. Evaluation of variations in sinonasal region with computed tomography. *World J Radiol* 2016; **8**: 98-108 [PMID: 26834948 DOI: 10.4329/wjr.v8.i1.98]
- 2 **Khanobthamchai K**, Shankar L, Hawke M, Bingham B. The secondary middle turbinate. *J Otolaryngol* 1991; **20**: 412-413 [PMID: 1774799]

P- Reviewer: Chandra R, Lobo D, Rapidis AD, Shen J, Sali L, van Beek EJR **S- Editor:** Kong JX **L- Editor:** A **E- Editor:** Wu HL





Published by **Baishideng Publishing Group Inc**

8226 Regency Drive, Pleasanton, CA 94588, USA

Telephone: +1-925-223-8242

Fax: +1-925-223-8243

E-mail: bpgoffice@wjgnet.com

Help Desk: <http://www.wjgnet.com/esps/helpdesk.aspx>

<http://www.wjgnet.com>

