



OLGU SUNUMU / CASE REPORT

Duodenitis caused by *Sarcina ventriculi* in a case with Celiac disease and selective IgA deficiency

Çölyak hastalığı ve selektif IgA eksikliği olan bir çocukta *Sarcina ventriculi* duodeniti

Oğuz Canan¹, Murat Özkale², Fazilet Kayaselçuk³

¹Baskent University Faculty of Medicine, Department of Pediatrics, Division Of Child Gastroenterology, Hepatology and Nutrition, ²Department of Pediatrics, ³Department of Pediatrics, Department of Pathology, Adana, Turkey

Cukurova Medical Journal 2017;42(4):766-768

Abstract

Sarcina ventriculi is a gram-positive, obligate anaerobic bacteria first documented in the human gastrointestinal tract in 1842. *Sarcina ventriculi* are found to be associated with delayed gastric emptying and gastric outlet obstruction. Up to date numerous cases of fatal disease have been attributed to this organism in the veterinary literature, but only a few human cases have been documented. Herein we report a case of a 10-year-old girl patient who was diagnosed Celiac disease, selective IgA deficiency and *Sarcina ventriculi* duodenitis. To the best of our knowledge the association Celiac disease and *Sarcina ventriculi* duodenitis has not been previously reported in children. Therefore, in the present study we want to draw attention to the importance of a rare coexistence of Celiac disease and *Sarcina ventriculi* duodenitis.

Key words: Celiac disease, *Sarcina ventriculi*, duodenitis, selective IgA deficiency.

Öz

Sarcina ventriculi gram pozitif, oblik, anaerobik bir bakteri olup insanlarda ilk kez 1842 yılında gastrointestinal sistemde tanımlanmıştır. *Sarcina ventriculi* gecikmiş mide boşalması ve mide çıkış tıkanıklığı ile ilişkili bulunmuştur. Bugüne kadar veterinerlik literatüründe bu mikroorganizmaya bağlı sayısız ölümcül hastalık bildirilmiş ancak insanlarla ilişkili birkaç vaka bildirilmiştir. Bu yazıda Çölyak hastalığı, selektif IgA eksikliği ve *Sarcina ventriculi* duodeniti tanısı alan 10 yaşında bir kız hastayı sunduk. Bilgilerimize göre Çölyak hastalığı ve *Sarcina ventriculi* duodeniti birlikteliği daha önce tanımlanmamıştır. Bu nedenle bu yazıda nadir olan Çölyak hastalığı ve *Sarcina ventriculi* duodeniti birlikteliğine dikkat çekmek istedik.

Anahtar kelimeler: Çölyak hastalığı, *Sarcina ventriculi* duodeniti, selektif IgA eksikliği.

INTRODUCTION

Sarcina organisms were first observed and recorded from the stomach contents of a patient suffering from vomiting by John Goodsir in 1842¹. Although numerous cases of fatal disease have been attributed to this organism in the veterinary literature, only a few human cases have been documented². Its pathogenic status is unclear³. *Sarcina ventriculi* is a Gram-positive, nonmotile, strictly anaerobic, carbohydrate-fermenting, and relative aerotolerance⁴.

Celiac disease (CD) that is a permanently food allergy in a common childhood which can cause to

chronic diarrhea, failure to thrive, anemia, and hypoalbuminemia. Additionally, primary immune deficiency syndrome in association with selective immunoglobulin (Ig) A deficiency is not uncommon in CD. Patients with selective IgA deficiency have a 10- to 20-fold increased risk of CD. In these patients, serological diagnosis of CD can be difficult, since specific IgA-based assays are usually negative. Herein, we were presented to a rare case with selective IgA deficiency and CD who was determined to *Sarcina ventriculi* duodenitis.

CASE

10-year-old-male patient was admitted to hospital

Yazışma Adresi/ Address for Correspondence: Dr. Oğuz Canan, Baskent University Faculty of Medicine, Department of Pediatrics, Division of Child Gastroenterology, Hepatology and Nutrition, Adana, Turkey.

E-mail: oguzcanan72@yahoo.com

Geliş tarihi/Received: 29.10.2016 Kabul tarihi/Accepted: 21.01.2017

with weakening, abdominal bloating, and chronic diarrhea. Physical examination was significant cachectic appearance and abdominal distension. Laboratory findings were detected anemia (hemoglobin: 9.2 g/dL) and hypoalbuminemia (albumin: 2.8 g/dL). The serum IgA level was tested through nephelometric method, and IgA level was lower than 5 g/L. The serum IgG, IgE and IgM values were within the normal range, and no concomitant deficiency was observed. The flow cytometry and lymphocyte subset analysis was normal. Whereas tissue transglutaminase IgA and anti-gliadin IgA antibodies were negative, tissue transglutaminase IgG (> 200 IU/L) and anti-gliadin IgG antibodies were positive. Abdominal ultrasonography was related minimal hepatomegaly, mild ascite, and a large amount gase appearance in the bowel loops. Upper gastrointestinal endoscopy was showed thinning and scalloping in duodenal folds in which were indicated diffuse mucosal atrophy. The duodenal biopsy examination was revealed to chronic atrophic duodenitis (Fig-1).

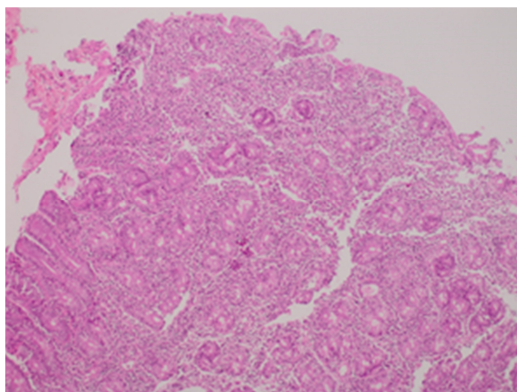


Figure 1. Total villous atrophy, diffuse mononuclear cell infiltration, and lymphoepithelial lesions in the duodenum (HE X 100)

The immunohistochemical staining with CD3 was positive. Additionally, *Sarcina ventriculi* morphologically appearing in groups of 4 or 8 cells were detected in duodenal biopsy materials (Fig-2). According to these findings, selective IgA deficiency, CD and *Sarcina ventriculi* duodenitis was diagnosed to the patient. Anti-anaerobic antibiotic therapy (during 4 weeks) and gluten-free diet was started. Although biopsy specimens were taken during latter endoscopies, no bacteria could be detected through microscopy and or culture. The clinically and laboratory findings were completely improved during follow-up 7 months.

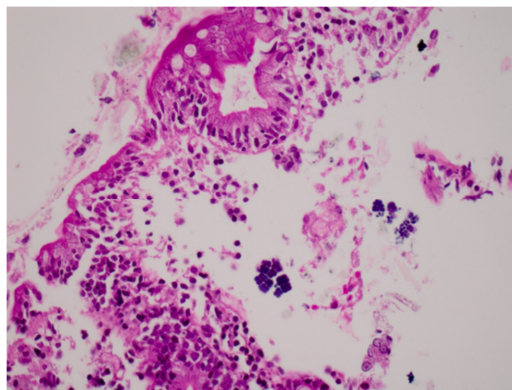


Figure 2. Sarcina ventriculi characteristically appearing in groups of 4 or 8 cells in the duodenum (HE X 400)

DISCUSSION

Sarcina has been demonstrated as a causative organism in the abdominal bloating and death of livestock, particularly of sheep and goats⁵. Descriptions of deadly emphysematous conditions and bloat in other animals soon followed in the veterinary literature². A few cases of human disease have also been associated with *Sarcina* organisms, including cases of emphysematous gastritis, peritonitis following gastric perforation, and gastric ulcer^{6,7}. The association of severe human disease with the *Sarcina* organism raises the question of whether the bacteria are pathogenic in humans.

Sarcina strains are able to grow at a pH as low as 2⁸. It is possible that *Sarcina ventriculi* can only thrive in the human stomach when gastric emptying is delayed⁵. Therefore, *Sarcina ventriculi* is most commonly found in patients with a history of gastric outlet obstruction or delayed gastric emptying⁵. Although the organism does not appear to cause direct mucosal injury, the presence of a concurrent gastric or duodenal ulcer may put the patient at increased risk for complications such as emphysematous gastritis or perforation. In our case, there was no apparent damage to the mucosal lesion in the stomach such as emphysematous gastritis, and no appearance of gastric outlet obstruction in upper gastrointestinal endoscopic examine. Furthermore, there was no evidence to suggest the delay in gastric emptying. Selective IgA deficiency is the most common primary immunodeficiency syndrome in childhood. The majority of IgA-deficient individuals are considered asymptomatic, even though IgA

deficiency has been associated with an increased frequency of recurrent infections. In literature, the relationship *Sarcina ventriculi* infection and primary or secondary immune deficiency was unclear. In our case had only selective IgA deficiency, and no concomitant deficiency was observed. When selective IgA deficiency in children with celiac disease is suspected, serological tests are important diagnostic IgG species. To the best of our knowledge, there was no reported that any case with selective IgA deficiency and *Sarcina ventriculi* duodenitis in literature.

The fewer cases with *Sarcina ventriculi* infection were reported in literature. Laass et al⁶, reported to 3-year-girl who has mental and psychomotor retardation was admitted with acute massive abdominal distension, and diagnosed acute emphysematous gastritis secondary *Sarcina ventriculi* in Germany. Lam-Hilmin et al⁹, detected to *Sarcina* organism in 5 patients of 145 adult patients who taken biopsy from upper gastrointestinal and performed histopathologic examination. In this study, chronic active gastritis in 1 case, reflux esophagitis in 1 case, and gastric hyperplastic polyp in another case was detected⁹. Only 46 year-old-case who was performed pancreaticoduodenectomy cause pancreatic adenocarcinoma was founded chronic active duodenitis⁹. In our literature screening, *Sarcina ventriculi* duodenitis could not demonstrate to the any case with CD. Our case had evidences of severe malabsorption (such as excessive weakening, profound anemia and hypoalbuminemia, and mild ascite). In the clinical and laboratory evaluation of the patient after 7 months follow-up that was noted quite improvement by combined therapy with gluten-free diet and anti-anaerobic antibiotic. Therefore, we considered that *Sarcina ventriculi*

infection can lead to more severe course of the celiac findings. We wanted to emphasize, especially the diet therapy fail to full respond in severe celiac patients with selective IgA deficiency, who should be considered to *Sarcina ventriculi* duodenitis, and duodenal biopsy specimen should be examined carefully in terms of this rare infection.

REFERENCES

1. Goodsir J. History of a case in which a fluid periodically ejected from the stomach contained vegetable organisms of an undescribed form. *Edinb Med Surg J.* 1842;57:430-43.
2. Vatn S, Gunnes G, Nybo K, Juul HM. Possible involvement of *Sarcina ventriculi* in canine and equine acute gastric dilatation. *Acta Vet Scand.* 2000;41:333-7.
3. Crowther JS. *Sarcina ventriculi* in human faeces. *J Med Microbiol.* 1971;4:343-50.
4. Goodwin S, Zeikus JG. Physiological adaptations of anaerobic bacteria to low pH: metabolic control of proton motive force in *Sarcina ventriculi*. *J Bacteriol.* 1987;169:2150-7.
5. DeBey BM, Blanchard PC, Durfee PT. Abomasal bloat associated with *Sarcina*-like bacteria in goat kids. *J Am Vet Med Assoc.* 1996;209:1468-9.
6. Laass MW, Pargac N, Fischer R, Bernhardt H, Knoke M, Henker J. Emphysematous gastritis caused by *Sarcina ventriculi*. *Gastrointest Endosc.* 2010;72:1101-3.
7. Tolentino LF, Kallichanda N, Javier B, Yoshimori R, French SW. A case report of gastric perforation and peritonitis associated with opportunistic infection by *Sarcina ventriculi*. *Lab Med.* 2003;34:535-7.
8. Burget GE. Note on the flora of the stomach. *J Bacteriol.* 1920;5:299-303.
9. Lam-Hilmin D, Tsiatis AC, Montgomery E, Pai RK, Brown JA, Razavi M et al. *Sarcina* organisms in the gastrointestinal tract: a clinicopathologic and molecular study. *Am J Surg Pathol.* 2011;35:1700-5.