

## Case report and the surgical treatment of two cases with pulmonary atresia in which pulmonary arteries are perfused by coronary arteries

### Pulmoner arter kanlanması koroner arterler yoluyla olan pulmoner atrezili iki olgu sunumu ve cerrahi tedavisi

Kahraman Yakut, M.D.,<sup>1</sup> Kürşad Tokel, M.D.,<sup>1</sup> Birgül Varan, M.D.,<sup>1</sup> İlkey Erdoğan, M.D.,<sup>1</sup> Murat Özkan, M.D.<sup>2</sup>

<sup>1</sup>Department of Pediatric Cardiology, Başkent University Faculty of Medicine, Ankara, Turkey

<sup>2</sup>Department of Cardiovascular Surgery, Başkent University Faculty of Medicine, Ankara, Turkey

**Summary**– Pulmonary atresia (PA) and ventricular septal defect (VSD) can occur in a variety of ways, from simple valve atresia to a condition in which circulation to the pulmonary bed occurs through collateral arteries separated from the aorta and there are no real pulmonary arteries, or they are present but hypoplastic. The size of the pulmonary arteries and concomitant complex cardiac lesions are important in making decisions about treatment and correctional alternatives. While complete correction surgeries in the style of a correction of tetralogy of Fallot are performed in simpler cases, many very invasive procedures are also performed and the resulting quality of life is very variable. The size of the pulmonary artery and its branches and the presence of accompanying collateral vessels are determining factors in the management of the disease. In this report, 2 cases of VSD and PA, in which the circulation of the pulmonary arteries was through the coronary arteries, diagnosed as a result of echocardiography performed following murmurs heard during examination, are described. The first patient was 40 days old and the second was 2 days old. In the second case, diagnosis was confirmed by catheter angiography, and in the first case, the final diagnosis was made during surgery. The aim of this report is to emphasize the importance of pulmonary artery size, the presence of pulmonary confluence, the origin of circulation, and concomitant collateral arteries when considering treatment methods.

**P**ulmonary atresia (PA) is a complex congenital heart disease with very variable morphological characteristics which may be seen in association with ventricular septal defect (VSD) or intact ventricular septum.<sup>[1-3]</sup> In congenital heart diseases associated with PA surgical treatment still continues to be a

**Özet**– Pulmoner atrezi (PA), ventriküler septal defekt (VSD) ile birlikte basit bir kapak atrezisinden, akciğer yatağının aortadan ayrılan kollateral arterler ile kanlandığı gerçek pulmoner arterlerin bulunmadığı veya ağır hipoplazik olduğu tabloya kadar çok geniş spektrum halinde görülebilmektedir. Pulmoner arterin ve dallarının boyutu ile birlikte eşlik eden diğer karmaşık kalp lezyonlarının varlığı tedavi yönteminde ve tüm düzeltme seçeneklerinin belirlenmesinde önemlidir. Basit formlarında Fallot tetralojisi onarımı tarzında tam düzeltme ameliyatı yapılırken, spektrumun diğer ucundaki hastalarda çok sayıda girişim gerekmekte ve yaşam kalitesi oldukça değişken olmaktadır. Pulmoner arter ve dallarının boyutu, eşlik eden kollateral arterlerin varlığı tedavi yönetiminde belirleyicidir. Burada ilk olgu 40 günlük, ikinci olgu iki günlük iken muayene sırasında üfürüm fark edilmesi üzerine yapılan ekokardiyografik incelemede VSD, pulmoner atrezi tanısı konmuş olan ve pulmoner arterlerin koroner arter aracılığı ile kanlanmasının sağlandığı iki olgu sunmak istedik. İkinci olgumuzda tanı kateter anjiyografi ile kesinleşti. İlk olgumuzda ancak cerrahi sırasında kesin tanı konulabildi. Bu çalışmayı sunmaktaki amacımız pulmoner atrezili hastalarda pulmoner arter boyutu, pulmoner konfluansın varlığı, kanlanmasının nereden sağlandığı ve eşlik eden kollateral arterlerin tedavi yönetimindeki önemini vurgulamaktır.

problematic issue, satisfactory results can be obtained using materials provided by developing technological facilities, and novel surgical techniques. If PAs are hypoplastic, palliative interven-

#### Abbreviations:

MAPCA	Major aortopulmonary collateral artery
PA	Pulmonary atresia
VSD	Ventricular septal defect

Received: March 31, 2017 Accepted: August 21, 2017

Correspondence: Dr. Kahraman Yakut. Başkent Üniversitesi Tıp Fakültesi, Çocuk Kardiyoloji Bilim Dalı, Ankara.

Tel: +90 312 - 203 68 68 / 1382 e-mail: e-posta: kahramanyakut@gmail.com

© 2018 Turkish Society of Cardiology



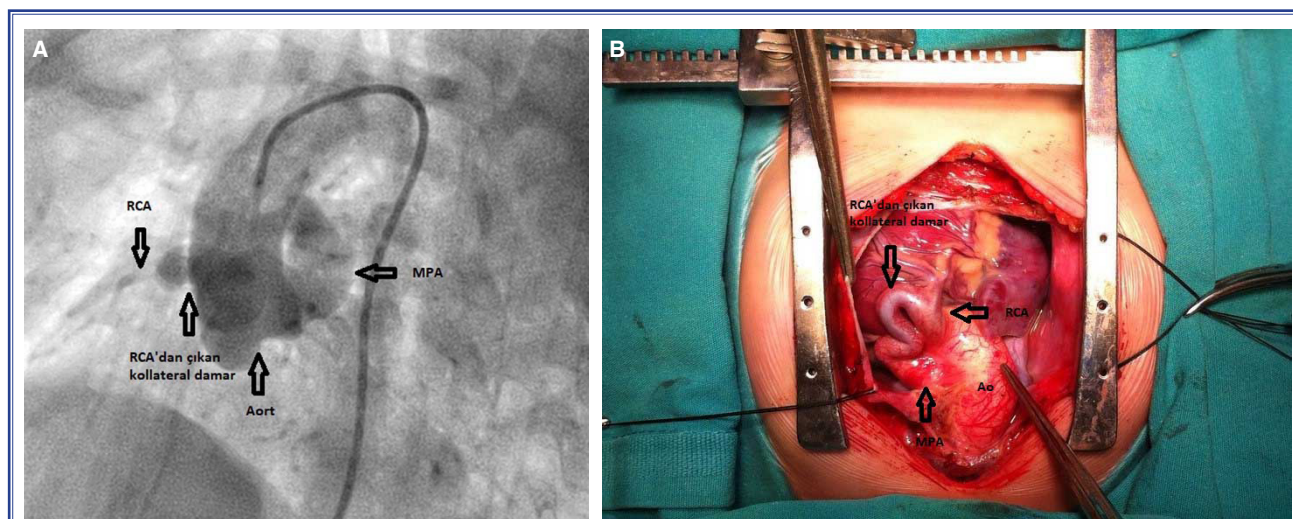
tions which will allow the development of PA so as to permit conduction of complete correction surgeries as soon as possible. With palliative methods it is possible to gain time for the development of pulmonary artery, and its branches, and perform complete correction surgeries at a later time. Although debates concerning the most optimal surgical approach still continue, with increasing information, more comfortable life is ensured for the patients. When diagnosis of PA is established, echocardiography, catheter angiography, and in case of need, computed tomography are important imaging modalities in determining dimensions of pulmonary artery, and its branches, presence of confluence (if any), source of its blood supply, dimensions, and location of the associated aortopulmonary collaterals, in specification of surgical, and interventional treatment methods, and decreasing postoperative morbidity, and mortality. Developments in diagnostic, and interventional methods, novel materials offered by technological facilities, accumulation of information about treatment modalities contribute significantly to survival time, and quality of life of the patients.

In this article we aimed to present rarely seen two cases with PA together with their surgical treatment whose pulmonary arterial perfusion was provided through coronary arteries.

### CASE REPORT

**Case 1**– During routine examination of a 2-month-

old male patient at another center, heart murmurs were heard. On echocardiographic examination, he received diagnoses of PA, VSD, and major aortopulmonary collateral artery (MAPCA) so he was sent to our clinic. When he was 10-month old, catheter angiography was performed preoperatively to evaluate main pulmonary artery, right, and left branches of pulmonary arteries, and collateral arteries. On angiography, a pulmonary artery arising from ventricles was not detected, while a collateral artery stemming from aortic root perfused pulmonary artery. Besides, common pulmonary artery, right, and left branches of pulmonary arteries had smaller calibres. Origins, and courses of right, and left coronary arteries were not anomalous, and two MACPAs which were not related to pulmonary arteries, and their branches but delivered contrast substance to the vascular beds of right, and left coronary arteries were detected. The patient was brought into the operating room with the decision to perform left Blalock-Taussig (BT) shunt. During surgery, it was determined that common pulmonary artery was not perfused by a collateral artery stemming from the aortic root, but its blood supply was provided by a tortuous collateral artery arising from the right coronary artery (Fig. 1a, b – Video 1, 2\*). Besides two MAPCAs unrelated to pulmonary artery, and its branches, delivered blood to the lungs Modified BT shunt was performed between left brachiocephalic artery, and left pulmonary artery. Collateral artery stemming from the right coronary artery was closed.



**Figure 1.** (A) Angiogram demonstrating blood circulation of the main pulmonary artery provided by a tortuous collateral vessel stemming from the right coronary artery. (B) Intraoperative view of the blood circulation of the main pulmonary artery provided by a tortuous collateral vessel stemming from right coronary artery.

In addition, two MAPCAs unrelated to pulmonary artery, and its branches, and unfit for unifocalization were also closed. Cardiac output of the patient who was monitored in the intensive care unit decreased on postoperative 2. day, and the patient exited the next day.

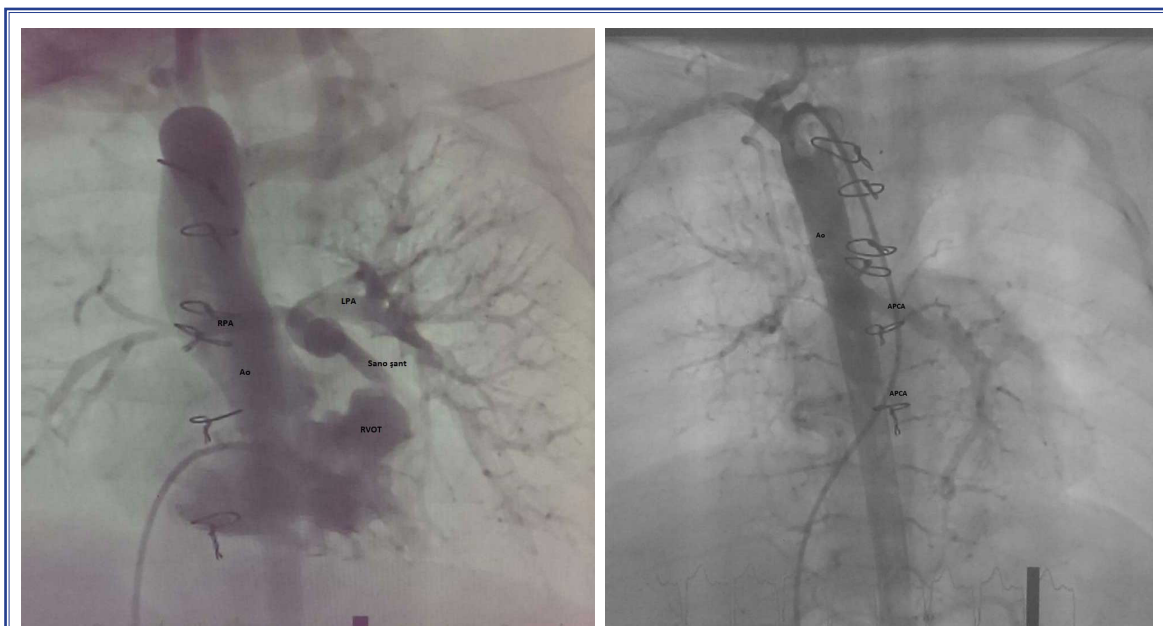**Case 2–** A 2-day-old newborn who had undergone echocardiographic examination at another center because of heart murmurs heard during its PE which necessitated catheter angiography due to persistently low oxygen saturation. The baby was referred to our center with the diagnoses of pulmonary atresia, VSD, and MAPCA for surgical intervention. The patient was referred to our clinic when it was 5-month-old, and underwent preoperative angiographic examination to determine, and evaluate the development, and the source of blood supply of main pulmonary artery, right, and left pulmonary arteries. On angiograms, any evidence suggesting pulmonary artery originating from ventricles was not observed, and also main pulmonary artery, right-left pulmonary arteries were hypoplastic. Blood supply of pulmonary artery was provided by a collateral artery arising from the right coronary artery which communicated with the main pulmonary artery in the supraclavicular region. Besides MAPCAs delivered blood into pulmonary arte-

rial bed, and these MAPCAs were not associated with confluent pulmonary arteries. The patient underwent Sano shunt when it was 8-month-old, and collateral vessel between the right coronary artery, and pulmonary artery was closed intraoperatively.

Since in this case peripheral pulmonary arterial bed was hypoplastic, MAPCAs were not closed with the intention to unifocalize them at a later date. Because of stenosis of outlet of the Sano shunt developed when the patient was 2 years of age, previously placed graft was replaced. Catheter angiographies performed during follow-up period revealed that pulmonary arterial bed, and collateral arteries did not develop adequately for complete correction surgery (Fig. 2a, b).

## DISCUSSION

Though considered as a term defining only pulmonary valvular pathology, pulmonary atresia also demonstrates its effects on all cardiac structures mainly left ventricle. In VSD patients with PA, very variable pulmonary artery circulation, and anatomy are the most effective determinant of natural course of this pathology, and treatment approach. Pulmonary circulation can be achieved with patent ductus arteriosus, and collaterals between coronary, and pulmonary arteries. Size of pulmonary artery, and its branches, presence



**Figure 2. (A)** Catheter angiogram demonstrating inadequately developed pulmonary arterial bed for complete correction, and unifocalization surgeries, and two collateral arteries stemming from aorta. **(B)** Catheter angiogram demonstrating inadequately developed pulmonary arterial bed for complete correction, and unifocalization surgeries, and two collateral arteries stemming from aorta.



of confluence, and suitability of collaterals for unifocalization are important factors in the preference for complete correction or palliative surgeries.<sup>[1–3]</sup> Post-operative survival, and morbidity may be related to the size of the remaining collaterals, and closure or unifocalization of these collaterals may be required before, and after surgery. Therefore in these patients confluence, and diameters of pulmonary arteries, location, and clinical significance of collaterals should be determined using echocardiography, and catheter angiography. In our two cases, preoperatively, catheter angiography was performed. Angiography report of Case 1, indicated that pulmonary artery was perfused from a collateral vessel stemming from a point near aortic root. However during surgery it was determined that blood circulation of pulmonary artery was provided by a collateral artery stemming from right coronary artery. Angiography of Case 2, could demonstrate that pulmonary arterial circulation was provided by a tortuous artery originating from coronary artery. Preoperative identification of the origin of these collaterals both increases success rate of surgery, and also shortens operative time. Although in our Case 1 any relationship between collaterals, and coronary arteries was not detected preoperatively, demonstration of collaterals stemming from a point near aortic root guided the surgical team.

In VSD patients with pulmonary atresia, pulmonary perfusion is entirely dependent on systemic circulation. Blood circulation of pulmonary artery is provided by MAPCAs mostly originating from aorta or ductus arteriosus. Pulmonary artery circulation is rarely provided by coronary arteries or plexuses formed by bronchial collateral arteries. Collateral arteries mostly stem from aorta. Since collateral arteries may rarely stem from coronary arteries, as was seen in our cases, aortography which also visualizes coronary arteries is recommended.<sup>[4,5]</sup>

While planning complete correction or palliative shunt surgeries, preoperative identification of large collaterals which might cause excess blood flow, and determination of their clinical importance are necessary prerequisites for decreasing rates of morbidity, and mortality.<sup>[1–3,6,7]</sup> In both of our cases collateral arteries arising from descending aorta, and delivering blood into lungs were angiographically demonstrated.

It has been reported that for achievement of an improved quality of life of the patients, at least 14–15

pulmonary artery segments should communicate with the right ventricle, and central pulmonary artery diameter should be  $\geq 50\%$  wider than normal. In our Case 1, since pulmonary arterial bed was adequate, and collateral arteries were not suitable for unifocalization, two collateral arteries were closed during operation. In our Case 2, pulmonary arterial bed was hypoplastic. Inadequacy of pulmonary arterial bed was predicted, so development of artery was awaited for unifocalization procedure. Many centers do not prefer shunting in newborns, and infants, however it has been reported that so as to achieve forward blood flow into pulmonary arteries at an early age, interposing 6–8 mm-wide homografts between the right ventricle, and pulmonary artery may further contribute to the development of pulmonary arterial bed. In our Case 2, we preferred Sano shunt based on the prediction that hypoplastic precapillary pulmonary arterial bed might develop faster with forward blood flow.

In cases with VSD, pulmonary atresia, dimensions of pulmonary artery, and its branches are the most important entities which determine the applicability of complete correction surgeries. Therefore adequacy of diameters of these vessels, and their branches should be evaluated using echocardiography, and angiography.<sup>[1,2,6,7]</sup> Since pulmonary arteries, and their branches are hypoplastic, complete correction surgery could not be performed in both of our cases. As a palliative treatment, modified BT shunt was preferred in Case 1, and Sano shunt in Case 2.

## Conclusion

In patients with VSD and pulmonary atresia, determination of dimensions, perfusion capability, presence, and origin of collateral arteries is important for the treatment, and prognosis. When performing imaging studies, it should not be forgotten that though collateral arteries may rarely stem from coronary arteries, ascending aorta together with coronary arteries should be evaluated during these radiological examinations.

**\*Complementary video file of this article can be found in online version of the journal.**

**Peer-review:** Externally, and independent.

**Informed consent:** Written, and undersigned informed consent forms were obtained from the parents of the patients related to the publication of the case, and relevant images.

**Conflict of interest:** None declared.

**Author contributions:** Concept – K.T., B.V., M.O.; Design – K.T., B.V., I.E.; Supervision – K.T., B.V., I.E., M.O.; Materials – K.Y.; Data collection &/or processing – K.Y., M.O.; Analysis and / or interpretation – K.Y., M.O., I.E.; Literature search – K.Y.; Writing – K.Y.; Critically revised by – K.T.

## REFERENCES

1. Reddy VM, McElhinney DB, Amin Z, Moore P, Parry AJ, Teitel DF, et al. Early and intermediate outcomes after repair of pulmonary atresia with ventricular septal defect and major aortopulmonary collateral arteries: experience with 85 patients. *Circulation* 2000;101:1826–32.
2. Tchervenkov CI, Roy N. Congenital Heart Surgery Nomenclature and Database Project: pulmonary atresia-ventricular septal defect. *Ann Thorac Surg* 2000;69:S97–105.
3. Zhu J, Meza J, Kato A, Saedi A, Chetan D, Parker R, et al. Pulmonary flow study predicts survival in pulmonary atresia with ventricular septal defect and major aortopulmonary collateral arteries. *J Thorac Cardiovasc Surg* 2016;152:1494–503.e1.
4. Cheung EW, Richmond ME, Turner ME, Bacha EA, Torres AJ. Pulmonary atresia/intact ventricular septum: influence of coronary anatomy on single-ventricle outcome. *Ann Thorac Surg* 2014;98:1371–7.
5. Walsh MA, Asoh K, Van Arsdell GS, Humpl T. Critical care outcomes in pulmonary atresia and intact ventricular septum undergoing single-ventricle palliation. *Cardiol Young* 2010;20:290–6.
6. Santos FC, Croti UA, Marchi CH, Hassem Sobrinho S. Double Aortic Arch Associated with Pulmonary Atresia with Ventricular Septal Defect. *Braz J Cardiovasc Surg* 2016;31:63–5.
7. Carotti A, Trezzi M. Pulmonary atresia with ventricular septal defect and major aortopulmonary collateral arteries: primary repair. *Multimed Man Cardiothorac Surg* 2016;2016. pii: mmv040.

**Keywords:** Congenital heart disease; coronary artery; pulmonary atresia; surgical treatment.

**Anahtar sözcükler:** Doğumsal kalp hastalığı; koroner arter; pulmoner atrezi; cerrahi tedavi.