

# A diffusion tensor imaging study in schizophrenia patients with clozapine induced obsessive compulsive symptoms

Şule Bıçakçı Ay<sup>1</sup> | Kader K. Oğuz<sup>2,3</sup> | Elçin Özçelik Eroğlu<sup>4</sup>  | Arzu Ceylan Has<sup>3</sup> | Aygün Ertuğrul<sup>4</sup>

<sup>1</sup>Department of Psychiatry, Baskent University Faculty of Medicine, Ankara, Turkey

<sup>2</sup>Department of Radiology, Hacettepe University Faculty of Medicine, Ankara, Turkey

<sup>3</sup>National MR Research Center (UMRAM), Bilkent University, Ankara, Turkey

<sup>4</sup>Department of Psychiatry, Hacettepe University Faculty of Medicine, Ankara, Turkey

## Correspondence

Aygün Ertuğrul, Department of Psychiatry, Hacettepe University Faculty of Medicine, Ankara, Turkey.

Email: [aertugru@hacettepe.edu.tr](mailto:aertugru@hacettepe.edu.tr)

## Funding information

Hacettepe Üniversitesi, Grant/Award Number: 10702

## Abstract

**Objective:** The aim of this study was to evaluate brain connectivity by diffusion tensor imaging (DTI) in schizophrenia patients with clozapine-induced obsessive compulsive symptoms (OCS).

**Methods:** Eighteen schizophrenia patients, nine of which had clozapine-induced OCS (Clz-OCS (+)), 9 without OCS (Clz-OCS (-)) and 9 healthy controls were included. Psychopathology was evaluated with Positive and Negative Syndrome Scale and Yale-Brown Obsession and Compulsion Scale in the patient groups. All groups were assessed with neurocognitive tests and DTI.

**Results:** Tract-Based Spatial Statistics based comparison of DTI revealed lower fractional anisotropy in the genu of corpus callosum (CC), right cingulum, left frontal white matter (WM) in the Clz-OCS (+) group, compared to controls. Fractional anisotropy was found to be lower in the bilateral occipital WM and higher in the bilateral medial temporal regions, anterior limb of internal capsule, cingulum, frontoparietal peripheral WM, right external capsule and genu of CC in Clz-OCS (+) patients compared to Clz-OCS (-).

**Conclusions:** WM integrity in several pathways such as cortico-striato-thalamo-cortical circuitry and orbito-frontal tracts seems to be affected differently in patients with Clz-OCS (+). Different neuroplastic effects of clozapine leading to occurrence of OCS in a subgroup of patients is possible, and needs further evaluation by longitudinal follow-up studies.

## KEYWORDS

clozapine, diffusion tensor imaging, fractional anisotropy, obsessive compulsive symptom, schizophrenia

## 1 | INTRODUCTION

Obsessive compulsive symptoms (OCS) and obsessive compulsive disorder (OCD) are common in patients with schizophrenia, with a prevalence of 30.3% for OCS and 13.3% for OCD (Swets et al., 2014), higher than the lifetime OCD prevalence for the general population which is 2.3%–3% (Ruscio et al., 2010; Subramaniam et al., 2012). Schizophrenia patients with comorbid OCS have more

impairment in motor (Krüger et al., 2000; Mukhopadhyaya et al., 2009) and cognitive functions. Worse neurocognitive performance was demonstrated in tasks such as executive functions (Hwang et al., 2000; Lysaker et al., 2002), visuospatial skills, delayed non-verbal memory, impulse inhibition, and cognitive shifting (Berman et al., 1998; Schirmbeck et al., 2011). These result in a negative effect of accompanying OCS on the prognosis of the condition (Schirmbeck & Zink, 2013).

Comorbidity of schizophrenia and OCS/OCD has been explained by a variety of factors such as a possible common neurobiologic basis and/or secondary effect of treatment with atypical antipsychotics (Grillault Laroche & Gaillard, 2016). 'De-novo' OCS/OCD that occur during treatment with atypical antipsychotics are mostly reported with clozapine (Scheltema Beduin et al., 2012), but can also be seen with olanzapine and risperidone (Ke et al., 2004; Wu et al., 2019).

Clozapine is the prototype of atypical antipsychotics that antagonize serotonin 5-HT<sub>2</sub> receptors stronger than dopamine D<sub>2</sub> receptors (Meltzer, 2013), and its high antiserotonergic effect together with high 5HT<sub>2A</sub>/D<sub>2</sub> occupancy ratio are considered to be the main underlying mechanisms for induction of OCS (Kim et al., 2019). *De novo* OCS rates were reported to be 20%–28%, while overall OCS rates with preexisting OCS were reported to be 38.2%–76% in clozapine treated patients (Fonseka et al., 2014). In a recent study, 77.9% of clozapine using patients were reported to have OCS, 44.3% having *de novo* and 33.6% having preexistent OCS, higher than the previous studies (Gürcan et al., 2021).

It is not yet fully known why clozapine-induced OCS are seen in some patients but not others. There are inconsistent findings regarding the influence of clinical variables such as dose and duration of clozapine treatment, or levels of clozapine on induction of OCS. Some studies reported a relationship between clozapine-induced OCS/OCD and the use of high dose (Kim et al., 2020; Reznik et al., 2004), and long duration of clozapine treatment (Lin et al., 2006; Schirmbeck et al., 2011), while no significant correlation was found in others (Ertugrul et al., 2005; Gürcan et al., 2021). Studies comparing demographic and clinical variables such as age, sex, duration of illness between patients with clozapine-induced OCS and those without OCS did not reveal a significant difference (Ertugrul et al., 2005; Gürcan et al., 2021; Kim et al., 2020), while genetic factors such as polymorphisms in SLC1A1 and GRIN2B genes, which are related to glutamate transmission, were reported to have a possible role in clozapine induced OCS (Cai et al., 2013; Ryu et al., 2011). Considering that clozapine is reported to enhance L-glutamate release in the frontal cortex of rats (Tanahashi et al., 2012), these findings suggested glutamatergic enhancement could be one of the underlying mechanisms for OCS induction by clozapine.

Neuroimaging studies can help to understand the pathophysiological mechanisms underlying clozapine-induced OCS/OCD. Structural and functional magnetic resonance imaging (MRI) studies in OCD have mostly focused on the cortico-striato-thalamo-cortical (CSTC) circuitry which is thought to play a major role in pathophysiology of OCD (de Wit et al., 2014; Fitzgerald et al., 2011; Piras et al., 2015). Functional imaging studies have shown increased activation in orbitofrontal cortex, anterior cingulate cortex (ACC), and regions of the basal ganglia (particularly caudate nucleus) in patients with OCD compared with healthy controls (Goodman et al., 2021). CSTC circuit activity was actually studied in patients with atypical antipsychotic induced OCS, and stronger brain activation in the orbitofrontal cortex, the left parahippocampal gyrus

and the globus pallidus during a response inhibition task was detected in patients receiving clozapine and olanzapine, the atypical antipsychotics with prominent anti-serotonergic profile, compared to patients using amisulpride and aripiprazole (Schirmbeck et al., 2015). In a recent fMRI study, higher frequency and severity of comorbid OCS and lower activation of left amygdala during an emotional processing task was shown in clozapine or olanzapine receiving patients when compared to amisulpride or aripiprazole group, and functional connectivity from left amygdala to right ventral striatum was found to be reduced. In addition, reduced amygdala activation was associated with OCS severity. The authors discussed the involvement of amygdala-cortico-striatal network in occurrence of atypical antipsychotic-induced OCS (Mier et al., 2019).

Diffusion tensor imaging (DTI), which shows disturbances in white matter (WM) integrity, may help to clarify underlying neural mechanisms of clozapine-induced OCS. Although there are many DTI studies conducted to explain the pathophysiology in OCD (Hu et al., 2020; Zhang et al., 2021), and in schizophrenia (Ellison-Wright & Bullmore, 2009; Vitolo et al., 2017), to our knowledge, there is no DTI study which evaluates the possible changes in patients with clozapine-induced OCS/OCD. Previously, our group showed that clozapine could increase fractional anisotropy (FA) in widespread brain regions following 12 weeks of treatment suggesting it could alter WM microstructure in patients with schizophrenia (Ozcelik-Eroglu et al., 2014). Therefore, studying the DTI findings of patients with clozapine induced OCS would help to show any difference specific to this group which may enlighten underlying pathophysiology.

In this cross-sectional, exploratory study, we aimed to evaluate the brain connectivity with Tract-Based Spatial Statistics (TBSS) based DTI assessment in patients with clozapine induced OCS, and compare it to those of clozapine using patients without OCS and healthy controls. We hypothesized that WM alterations in schizophrenia patients who were on clozapine treatment and had OCS would be different than those who did not have OCS, as assessed by FA revealed by DTI.

## 2 | METHODS

### 2.1 | Participants

This study was conducted at Hacettepe University School of Medicine, Department of Psychiatry. Nine patients with schizophrenia who developed *de novo* OCS after clozapine treatment (Clz-OCS (+) group), 9 patients with schizophrenia who did not have OCS before or after clozapine treatment (Clz-OCS (–) group) and 9 healthy subjects matching the patient groups with regard to age, sex and education level were included in the study. Exclusion criteria were having OCS before clozapine treatment, alcohol or drug abuse/dependency, any major medical or neurological disorder and history of

head trauma that would affect neuroradiological assessment. The study protocol was approved by the Hacettepe University School of Medicine Ethics Committee (GO 161211-12) and all participants gave informed consent.

## 2.2 | Procedures

Sociodemographic and clinical information was obtained from patients and their relatives during clinical interviews and from medical records. Information regarding history of the illness and the treatments (age at onset of illness, duration of illness, duration of clozapine use, number of hospitalizations, reasons for clozapine initiation etc.) including timing of the initiation of OCS was gathered from electronic and paper records and during clinical interviews. The Structured Clinical Interview for DSM IV (Corapcioglu et al., 1999; First, 1997) was used to confirm diagnoses and to exclude any Axis-I disorder in the controls. The patient groups were assessed using Positive and Negative Syndrome Scale (PANSS) (Kay et al., 1987; Kostakoglu et al., 1999), Yale-Brown Obsession and Compulsion Scale (YBOCS) (Goodman et al., 1989; Karamustafaoglu et al., 1993), neurocognitive test battery; and DTI. The Clozapine-OCS (+) group included patients who had been using clozapine treatment for at least 6 months, whose OCS started after clozapine treatment, and who had a current Y-BOCS score > 16 at the time of assessment. The Clozapine-OCS (-) group was composed of the patients who had been using clozapine for at least 6 months, had no history of OCS, and found to have a current Y-BOCS score <8 at the time of assessment. The control group was assessed with neurocognitive test battery and DTI.

## 2.3 | Assessment instruments

Positive and Negative Syndrome Scale is a semi-structured interview scale with 30 items and a seven-point rating for severity of schizophrenia (Kay et al., 1987; Kostakoglu et al., 1999). Of the 30 psychiatric symptoms assessed by PANSS, 7 belong to the positive syndrome subscale, 7 to the negative syndrome subscale, and the remaining 16 to the general psychopathology subscale. This scale was applied to the patient group to determine the severity of schizophrenia symptoms.

Yale-Brown Obsession and Compulsion Scale is an interviewer-applied scale which measures the type and severity of obsessive-compulsive symptoms (Goodman et al., 1989; Karamustafaoglu et al., 1993; Tek et al., 1995). It consists of 19 items in total, but only the first 10 items are used to determine the total score. The score for each question ranges from 0 to 4.

Visual memory was assessed with Wechsler Memory Scale-Visual Reproduction Scale 1-2 (Karakas et al., 1996; Wechsler, 1987). For assessment of verbal fluency and speed of verbal production Phonemic and Semantic Verbal Fluency Tests (Erden Aki et al., 2013; Lezak, 1995); for attention, motor speed and mental

flexibility Trail Making Test A and B (Cangoz et al., 2009; Spreen & Strauss, 1998); for attention and motor impulsivity Go/no-go Test (Bezdjian et al., 2009) and for attention and working memory Digit Span Test Part A and B were administered (Karakas et al., 1996; Wechsler, 1987).

## 2.4 | Image acquisition

Imaging of the brain was performed on a 3T MRI scanner (Ingenia, Philips) equipped with a 8-channel phased-array head coil. Imaging protocol included DTI of the whole brain (single-shot EPI; TR/TE: 4251/99 msec, max. *b* factor: 1000 s/mm<sup>2</sup>, 32 independent directions, FOV: 224 mm, matrix: 128 × 128, 64 axial sections with 2 mm thickness without intersection gap, voxel size: 2 × 2 × 2 mm). Structural 3D T1-weighted high resolution (TR/TE: 2600/306 msec; FA: 80; FOV: 256 mm; matrix: 224 × 256; distance factor: %50) sequence was also obtained. Additionally, axial T2W turbo spin echo (TR/TE:5000/100 ms) series was obtained to exclude the presence of any abnormality.

## 2.5 | Processing and analysis of diffusion tensor imaging data

Tract-Based Spatial Statistics, a part of FSL, was used for multiple comparisons of the groups (<https://fsl.fmrib.ox.ac.uk/fsl/fslwiki/FDT/UserGuide>). Fractional anisotropy maps were computed following head motion and eddy current correction, skull stripping and diffusion tensor fitting processes for each diffusion weighted data. Registration and alignment of FA maps to the average space were performed as input for TBSS, and the thinned mean FA skeleton was computed. Then voxel-wise statistics were performed using the permutation-based inference with 5000 permutations. The voxel-wise comparison was controlled by the family wise error rate at a certain threshold ( $p < 0.05$ ) with the threshold free cluster enhancement. John Hopkins University White Matter Atlas was used to recognize the tracts (Hua et al., 2008). We used standard cluster-based thresholding corrected for multiple comparisons with a *t* threshold of 1.5 and obtained the contiguous clusters of supra-threshold voxels using 26-neighbour connectivity.

## 2.6 | Statistical analysis

Statistical analysis was performed using SPSS v.22.0 package software for Windows. Descriptive statistics were expressed as mean ± standard deviation for continuous variables and as number and percentages for categorical variables. Patient groups and controls were compared using the Kruskal-Wallis and Mann-Whitney *U*-test for numerical variables and the chi-square test for nominal variables.

Comparisons of FA values in the healthy controls versus Clz-OCS (–); healthy controls versus Clz-OCS (+), and Clz-OCS (–) versus Clz-OCS (+) were performed by the TBSS method.

The level of significance was taken as  $p < 0.05$  for all tests.

### 3 | RESULTS

#### 3.1 | Demographic and clinical characteristics

A total of 27 participants (18 patients with schizophrenia and 9 healthy controls), were included in the study. Nine patients with schizophrenia were in the group who had *de novo* OCS after clozapine treatment (Clz-OCS (+)), 9 patients were in the group who were using clozapine and had no history of OCS (Clz-OCS (–)). The mean age of the patients was  $42.78 \pm 9.37$  in the Clz-OCS (+) group,  $49.56 \pm 11.3$  in the Clz-OCS (–) group, and  $42.11 \pm 11.02$  in the control group. There were no significant differences between the groups in terms of age, sex and years of education. The sociodemographic characteristics of the patients and controls are summarized in Table 1.

When the clinical characteristics of Clz-OCS (+) and Clz-OCS (–) were compared no significant differences were found between the two groups in terms of age at onset of illness, duration of illness (Table 2). The number of hospitalizations were significantly higher in Clz-OCS (+) group ( $5.56 \pm 5.00$ ), compared to Clz-OCS (–) group ( $1.44 \pm 1.33$ ) ( $p < 0.05$ ). The mean clozapine dose in the Clz-OCS (+) group was  $366.67 \pm 119.89$  mg/day and the mean duration of clozapine treatment was  $157.33 \pm 87.45$  months, while the mean clozapine dose in the Clz-OCS (–) group was  $383.33 \pm 75.00$  mg/day and the mean duration of treatment was  $132.00 \pm 33.40$  months with no significant differences between the two groups.

Eight (88.8%) patients in the Clz-OCS (+) group and 1 patient (11.1%) in the Clz-OCS (–) group were taking antidepressant medication at the time of the study. Apart from this, drugs used in addition to clozapine treatment for patients in the Clz-OCS (+) group were; antipsychotics ( $n = 1$  haloperidol,  $n = 1$  aripiprazole,  $n = 1$  amisulpride), mood stabilizers ( $n = 1$  topiramate,  $n = 1$  lamotrigine), benzodiazepine ( $n = 1$  clonazepam), other ( $n = 1$  hydroxyzine,  $n = 1$  propranolol,  $n = 1$  tetrabenazine); Clz-OCS (–) group was; antipsychotic ( $n = 1$  risperidone) and mood stabilizer ( $n = 1$  sodium valproate).

Comparison of the psychopathology severity assessments in the patient groups showed that PANSS positive and general psychopathology scores, YBOCS total, obsession and compulsion scores were found to be significantly higher in the Clz-OCS (+) group compared to Clz-OCS (–). There were no significant differences with regard to PANSS negative and total scores in the patient groups.

When the cognitive test results of the patient groups were compared with each other and with healthy controls, the Clz-OCS (–) group performed significantly worse than the healthy controls at Category Fluency-Human, Category Fluency-Alternation, Visual Reproduction-immediate Visual Reproduction-delayed, Go/No-go

"Omission" part 1 and "Omission" total tests errors. In the Controlled Word Association Test and Digit Span-Forward Tests, the performance of the Clz-OCS (+) group was found to be significantly better than the Clz-OCS (–) group ( $p = 0.03$  and  $p = 0.025$  respectively). When the other cognitive test results were compared, no significant differences were found between the three groups (Table 3).

#### 3.2 | Comparison of fractional anisotropy values in the schizophrenia and control groups

Schizophrenia patients with or without clozapine-induced OCS showed significant WM alterations as compared to healthy controls. Furthermore there were also significant differences in terms of microstructural diffusion changes between the clozapine using schizophrenia patients with and without OCS.

Tract-Based Spatial Statistics showed that FA values were significantly lower in the left internal capsule of anterior limb (ALIC), genu of corpus callosum (CC), right cingulum and left frontal WM in the Clz-OCS (+) group than in the control group. On the other hand, right and left hippocampus, right internal capsule posterior limb (PLIC), left PLIC, right external capsule FA values were higher in Clz-OCS (+) group compared to controls (Table 4, Figure 1).

When compared to control group, TBSS showed that left ALIC, right and left forceps minor, genu of CC, right thalamus, right fornix, right and left cingulum FA values were lower in the Clz-OCS (–) group. However, right and left PLIC, and left thalamus FA values were higher in Clz-OCS (–) group compared to controls (Table 5, Figure 2).

When DTI imaging of Clz-OCS (+) and Clz-OCS (–) groups were compared by TBSS; right and left occipital WM FA values were found to be lower in Clz-OCS (+) group. Right and left medial temporal, right external capsule, right and left ALIC, genu of CC, right and left cingulum, right and left frontotemporal peripheral WM FA values were statistically higher in Clz-OCS (+) group than in the Clz-OCS (–) (Table 6, Figure 3).

### 4 | DISCUSSION

This study aimed to evaluate brain connectivity with TBSS based DTI in patients with clozapine induced OCS, and compare it with patients without clozapine-induced OCS and healthy controls, in order to increase our understanding of the pathophysiology of OCS induced by clozapine.

Previous studies reported inconsistent findings regarding the association of demographic and clinical variables with clozapine induced OCS (Ertugrul et al., 2005; Gürcan et al., 2021; Kim et al., 2020; Lin et al., 2006; Reznik et al., 2004; Schirmbeck et al., 2011). Our study showed no significant differences between clozapine-OCS (+) and clozapine-OCS (–) patients in terms of age, education, sex, age at onset of illness, duration of illness, dose of clozapine and duration of clozapine treatment similar to the results

TABLE 1 Sociodemographic characteristics of patient groups and healthy controls

	Clz-OCS (+) mean ± SD	Clz-OCS (-) mean ± SD	Control mean ± SD	Analyses <sup>a,b</sup> p Values
Age (year)	42.78 ± 9.37	49.5 ± 11.3	42.11 ± 11.02	0.25 <sup>a</sup>
Education (year)	10.78 ± 2.53	8.78 ± 3.80	11.11 ± 3.18	0.30 <sup>a</sup>
	N (%)	N (%)	N (%)	
Gender				0.85 <sup>b</sup>
Male	5 (55.6)	6 (66.7)	6 (66.7)	
Female	4 (44.4)	3 (33.3)	3 (33.3)	
Marital status				
Married	1 (11.1)	3 (33.3)	7 (77.8)	
Single	7 (77.8)	4 (44.4)	2 (22.2)	
Divorced	1 (11.1)	2 (22.2)	0 (0)	

Abbreviations: Clz-OCS, patient with obsessive compulsive symptoms; N, number; SD, standard deviation; %, percent.

<sup>a</sup>Kruskal-Wallis Test.

<sup>b</sup>Chi-squared test.

TABLE 2 Clinical characteristics and comparison of positive and negative syndrome scale (PANSS), CGI severity and Yale-Brown obsession and compulsion scale (YBOCS) scores of patient groups

	Clz-OCS (+) mean ± SD	Clz-OCS (-) mean ± SD	Analyses <sup>a</sup> p
Age at onset of illness	18.67 ± 3.50	22.67 ± 6.70	0.13 <sup>a</sup>
Duration of illness (years)	24.11 ± 9.07	26.89 ± 8.82	0.48 <sup>a</sup>
Number of hospitalizations	5.56 ± 5.00	1.44 ± 1.33	0.02 <sup>a</sup>
Clozapine dose (mg/day)	366.67 ± 119.89	383.33 ± 75.00	0.73 <sup>a</sup>
Duration of clozapine use (months)	157.33 ± 87.45	132.00 ± 33.40	0.60 <sup>a</sup>
PANSS score			
Total	60.67 ± 14.69	49.11 ± 12.39	p = 0.07 <sup>a</sup>
Positive	14 ± 4.33	8.78 ± 1.09	p = 0.004 <sup>a</sup>
Negative	15.22 ± 4.08	16.89 ± 7.60	p = 0.73 <sup>a</sup>
General psychopathology	31.44 ± 7.41	23.44 ± 4.61	p = 0.008 <sup>a</sup>
YBOCS score			
Total	22.33 ± 2.29	0.44 ± 1.01	p = 0.00 <sup>a</sup>
Obsession	10.33 ± 1.80	0.11 ± 0.33	p = 0.00 <sup>a</sup>
Compulsion	12.00 ± 1.41	0.33 ± 0.70	p = 0.00 <sup>a</sup>

Abbreviations: Clz-OCS, patient with obsessive compulsive symptoms; CGI-S, Clinical Global Impression Scale-Severity; min, minimum; max, maximum; PANSS, Positive and Negative Syndrome Scale; SD, standard deviation; YBOCS, Yale-Brown Obsession and Compulsion Scale.

<sup>a</sup>Mann-Whitney U test.

of other studies (Ertugrul et al., 2005; Gürcan et al., 2021; Kim et al., 2020). The patients with clozapine-induced OCS/OCD who naturally had higher YBOCS scores compared to those without OCS, also reported higher number of hospitalizations, and had higher PANSS positive and general psychopathology subscores. Although clozapine is an effective treatment in patients with schizophrenia, clozapine-induced OCS is reported to cause higher severity and burden of disease (Schirmbeck & Zink, 2012), which is in concordance

with increased number of hospitalizations and higher scores of psychopathology in clozapine-OCS (+) group in our study.

How does clozapine induce OCS in some patients while not in others? The results of this study revealed a widespread, but differential alteration in the WM integrity of patients with clozapine induced OCS compared to those without. Several functional neuroimaging studies tried to explore the pathophysiology of OCS induction by antipsychotics including clozapine, and in these studies they

TABLE 3 Neurocognitive test results of patient groups and healthy controls

	Clz-OCS (+) mean ± SD	Clz-OCS (-) mean ± SD	Control mean ± SD	Analyses <sup>a</sup> , p values			
				Comparison of three groups <sup>a</sup>	Control versus Clz-OCS (+) <sup>a</sup>	Control versus Clz-OCS (-) <sup>a</sup>	Clz-OCS (+) versus Clz-OCS (-) <sup>a</sup>
Controlled word association test	31.00 ± 10.86	17.33 ± 8.90	20.89 ± 9.28	0.03	0.27	1.00	0.03
Category fluency- animal	16.89 ± 6.29	14.89 ± 5.41	14.67 ± 3.24	0.61			
Category fluency- human	20.33 ± 7.34	16.33 ± 4.06	23.44 ± 3.04	0.008	0.48	0.006	0.26
Category fluency- alternation	11.67 ± 6.06	9.44 ± 3.20	14.67 ± 2.29	0.023	0.48	0.018	0.53
Digit span-forward	5.78 ± 1.20	3.89 ± 1.36	4.89 ± 1.53	0.035	0.42	0.74	0.025
Digit span- backward	4.67 ± 1.50	3.89 ± 1.45	5.22 ± 1.64	0.15			
Visual reproduction- immediate	12.44 ± 6.00	10.33 ± 3.12	16.89 ± 3.33	0.01	0.18	0.01	1.00
Visual reproduction- delayed	9.67 ± 7.58	7.78 ± 3.42	14.33 ± 4.47	0.02	0.12	0.03	1.00
Trail making test A-time	59.00 ± 23.68	74.11 ± 27.46	51.56 ± 11.77	0.16			
Trail making test B-time	180.38 ± 81.62	189.71 ± 91.13	123.25 ± 47.39	0.24			
Go/No-go 'Omission' part 1	13.11 ± 17.83	34.56 ± 35.78	12.33 ± 33.64	0.02	1.00	0.01	0.21
Go/No-go 'Omission' part 2	3.22 (3.27)	4.11 (7.94)	0.44 (0.72)	0.07			
Go/No-go 'omission' total	16.33 (20.56)	38.67 (41.14)	12.78 (34.24)	0.02	0.70	0.01	0.33
Go/No-go 'Comission' part 1	12.67 (8.83)	7.89 (3.51)	6.67 (4.18)	0.28			
Go/No-go 'Comission' part 2	7.00 (6.91)	7.44 (7.21)	2.67 (2.34)	0.15			
Go/No-go 'comission' total	19.67 (14.50)	15.56 (8.76)	9.33 (5.87)	0.18			

Abbreviations: Clz-OCS, patient with obsessive compulsive symptoms; SD, standard deviation.

<sup>a</sup>Kruskal-Wallis Test.

observed that similar brain regions with OCD were involved in the pathophysiological processes (Mier et al., 2019; Piras et al., 2015; Schirmbeck et al., 2015). The CSTC circuitry plays a major role in pathophysiology of OCD, and structural and functional neuroimaging studies in OCD have mostly focused on the circuitry which includes the orbitofrontal cortex, cingulate cortex, striatum, thalamus and temporolimbic regions (lateral and medial temporal cortex, amygdala, hippocampus, parahippocampus, hypothalamus and insular cortex) (de Wit et al., 2014; Fitzgerald et al., 2011; Gan et al., 2017; Piras et al., 2015). There are several DTI studies which evaluated the CSTC circuitry in OCD patients, and the findings of these studies are inconsistent due to different methodologies and heterogeneity of

samples. Despite the inconsistency, a recent metaanalysis of TBSS studies reported that the most consistent findings were lower FA in the genu of CC (Hu et al., 2020; Zhang et al., 2021), and left orbitofrontal WM (Hu et al., 2020) which suggested disturbances in WM connectivity. The genu of CC connects the two hemispheres of the frontal cortices, including the medial prefrontal cortex and the ACC, which are the major components of CSTC circuitry (Roland et al., 2017). In the current study, FA was found to be significantly lower in the genu of CC, right cingulum and left frontal WM in the group of Clz-OCS (+) compared to controls, supporting the role of CSTC circuitry, and which may actually represent a difference caused by combination of the effects of underlying pathophysiological

changes due to schizophrenia, the influence of clozapine treatment, and the existence of OCS. While the most frequently repeated finding was lower FA in the genu of CC in patients with OCD (Hu et al., 2020; Zhang et al., 2021), higher FA in the genu of CC were also reported in some studies (Yoo et al., 2007; Zarei et al., 2011) and suggested to result from a pathological neural remodelling process that modified the tissue integrity (Yoo et al., 2007). We found a higher FA in the genu of CC in the Clz-OCS (+) group compared to

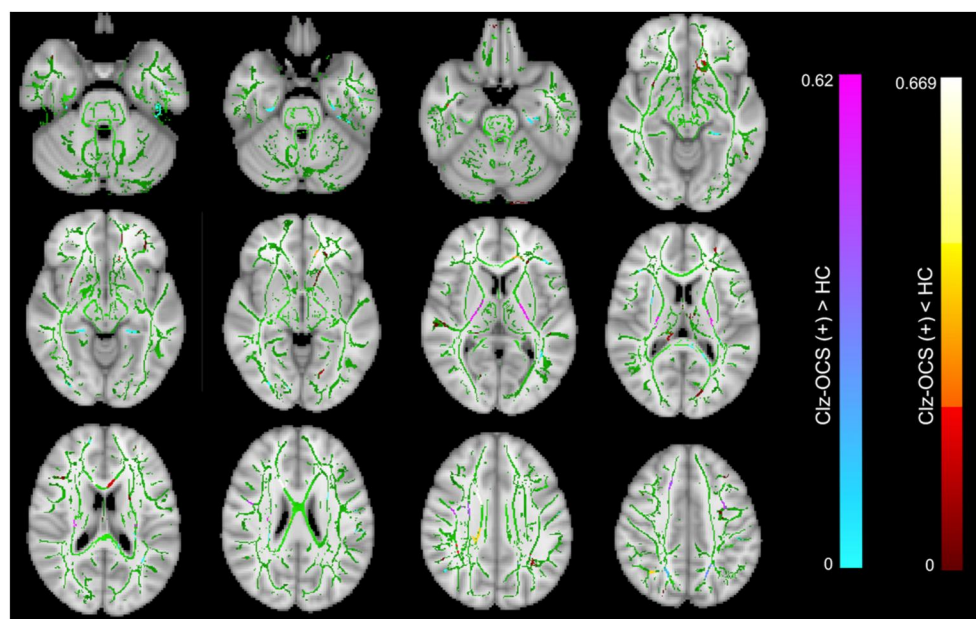
the Clz-OCS (-), although FA was significantly lower in the genu of CC in the clozapine treated groups compared to the healthy controls. Considering the previous findings, higher FA in the genu of CC in the group of Clz-OCS (+) compared to Clz-OCS (-) may suggest another example of differential neuronal remodelling which resulted to or from a pathological process. Previously, we reported that FA increased in the CC after 12-week of clozapine treatment (Ozcelik-Eroglu et al., 2014) whereas a follow-up study reported decreased FA in CC after 6-month of clozapine treatment (Tronchin et al., 2021), although no significant relationship between alteration of FA and symptoms were present in these studies. In the current study, the mean duration of clozapine treatment is very long, and found to be  $157,33 \pm 87,45$  and  $132,00 \pm 33,40$  months in Clz-OCS (+) and Clz-OCS (-) groups respectively. Although this is a cross-sectional study, lower FA in the genu of CC in the clozapine treated groups compared to healthy controls is consistent with result of the 6 months follow-up study, and suggest that the increase in FA in the early phase of clozapine treatment may not remain in the long term. As the lower FA in the CC is usually suggested to be a biomarker in schizophrenia (Zhao et al., 2018), and clozapine using groups in this study had lower FA compared to controls, the finding of higher FA in CC in the group of Clz-OCS (+) may be linked to the existence of OCS/OCD.

The other regions which play a role in the pathophysiology of OCD include the orbitofrontal gyrus, and orbitofrontal WM tracts such as the uncinate fasciculi (UF) and the inferior fronto-occipital fasciculi (IFOF) (Hu et al., 2020). The UF connects the orbitofrontal cortex with medial temporal structures such as the hippocampus and amygdala (Zarei et al., 2011). The IFOF connects the ventrolateral prefrontal cortex and medial orbitofrontal cortex to posterior parietal and occipital associative cortices, these associative cortices participate in an excessive visual attention to irrelevant details in

**TABLE 4** The MNI coordinates of the brain regions which are significantly different between clozapine using patients with obsessive compulsive symptoms (OCS) and healthy controls according to Tract-Based Spatial Statistics (TBSS)

Regions	x	y	z
Clz-OCS (+) FA < Control FA			
Left ALIC	-14	3	7
Genu CC	-3	26	5
Right cingulum	10	-37	32
Left frontal white matter	-38	-2	-27
Clz-OCS (+) FA > Control FA			
Left hippocampus	-22	-27	-18
Right hippocampus	24	-25	-19
Right PLIC	24	-18	13
Left PLIC	-23	-18	13
Right external capsule	32	5	-8

Abbreviations: ALIC, anterior limb of the internal capsule; CC, corpus callosum; Clz-OCS, patient with obsessive compulsive symptoms; FA, Fractional Anisotropy; PLIC, posterior limb of the internal capsule.



**FIGURE 1** Red shows decreased and blue shows increased fractional anisotropy (FA) in patients with clozapine-induced obsessive compulsive symptoms (OCS) compared to healthy controls (FWE-corrected threshold-cluster extend voxel P maps <0.05).

OCD (Garibotto et al., 2010). In this study, the clozapine with OCS/OCD group had lower FA in bilateral occipital WM, which also includes fibres of the IFOF, and higher FA in bilateral frontoparietal WM when compared to group without OCS. Higher or lower FA in different pathways involving the orbitofrontal gyrus may suggest that different regions play a different role in pathophysiology of clozapine

**TABLE 5** The MNI coordinates of the significantly different brain regions in comparison of clozapine using patients without obsessive compulsive symptoms (OCS) and healthy controls by TBSS-DTI

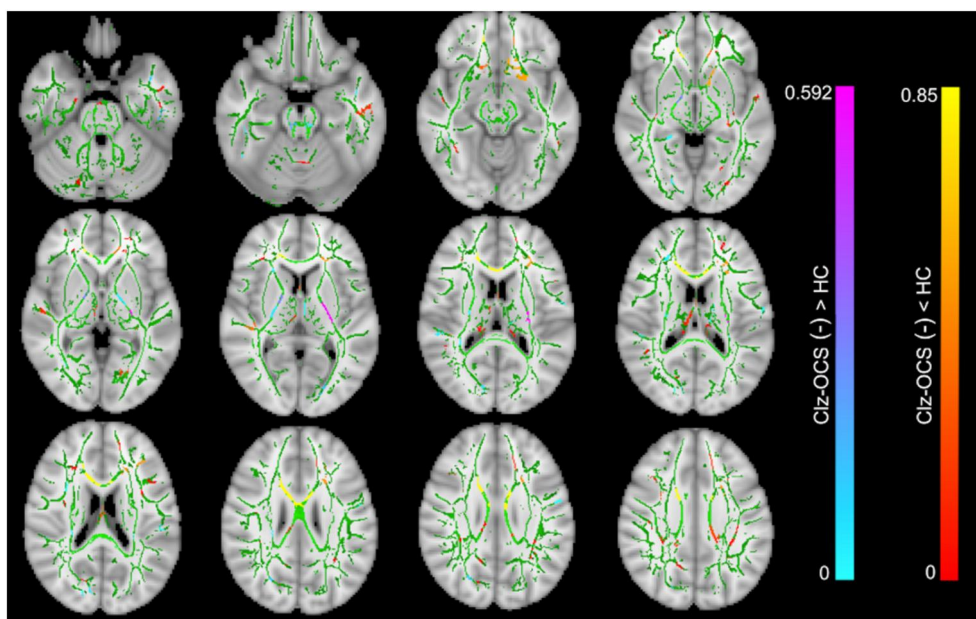
Regions	x	y	z
Clz-OCS (-) FA < Control FA (red)			
Left ALIC	-14	3	7
Right forceps minor	16	37	1
Left forceps minor	-20	37	1
Genu of CC	-3	26	5
Right thalamus	14	-24	6
Right fornix	3	-10	16
Right cingulum	10	-37	32
Left cingulum	-7	-36	32
Clz-OCS (-) FA > Control FA (blue)			
Right PLIC	24	-18	13
Left PLIC	-23	-18	13
Left thalamus	-12	-24	6

Abbreviations: ALIC, anterior limb of the internal capsule; CC, corpus callosum; Clz-OCS, patient with obsessive compulsive symptoms; FA, Fractional Anisotropy; PLIC, posterior limb of the internal capsule.

induced OCS/OCD. However it should be kept in mind that changes in WM integrity may not only be a direct cause of disease or treatment, but adaptive or maladaptive compensatory mechanisms may also play role.

The findings of our study should be interpreted in caution, because the abnormalities in the CSTC circuitry have been reported both in patients with schizophrenia and OCD (Wang et al., 2020), while clozapine and antidepressants have also been reported to have effects on WM connectivity (Ozcelik-Eroglu et al., 2014; Vieira et al., 2021). In a study comparing the OCD patients who were drug naive with the patients who had an ongoing drug treatment, there was a lower FA in IFOF, UF, anterior corona radiata and forceps minor in patients with an ongoing drug treatment, and it was argued that lower FA in OCD could be related to the effect of drugs (Benedetti et al., 2013). In the 12-week follow-up study about the effects of clozapine on DTI, it was reported that white matter FA increased in widespread brain regions including bilateral uncinate fasciculus, thalamus, CC, left cingulum, ALIC of internal capsule (Ozcelik-Eroglu et al., 2014). These findings were suggested to result from a possible neuroplastic effect of clozapine (Critchlow et al., 2006; Ozdemir et al., 2012) which might have changed the WM connectivity. In the current study, the differences in FA values between Clz-OCS(+) and Clz-OCS(-) patients may represent a different neuroplastic effect of clozapine in a group of patients with schizophrenia leading to occurrence of OCS.

Regarding neurocognitive test results, the performance of the Clz-OCS(+) group was significantly better than the Clz-OCS(-) group in the Controlled Word Association Test and Digit Span-Forward Tests, ( $p = 0.03$  and  $p = 0.025$  respectively). No significant differences were found between the two groups in other cognitive tests. Controlled Word Association Test helps assessment of attention,



**FIGURE 2** Red shows decreased and blue shows increased fractional anisotropy (FA) in patients without clozapine-induced obsessive compulsive symptoms (OCS) compared to healthy controls. (FWE-corrected threshold-cluster extend voxel  $P$  maps  $<0.05$ ).



working memory and executive functions while digit span-forward test is defined as a test mostly related to attention. The fact that the performance on these tests were significantly better in the Clz-OCS(+) group than the Clz-OCS(-) group can be interpreted as a

**TABLE 6** The MNI coordinates of the brain regions which are significantly different between clozapine using patients with and without obsessive compulsive symptoms (OCS) according to TBSS-DTI

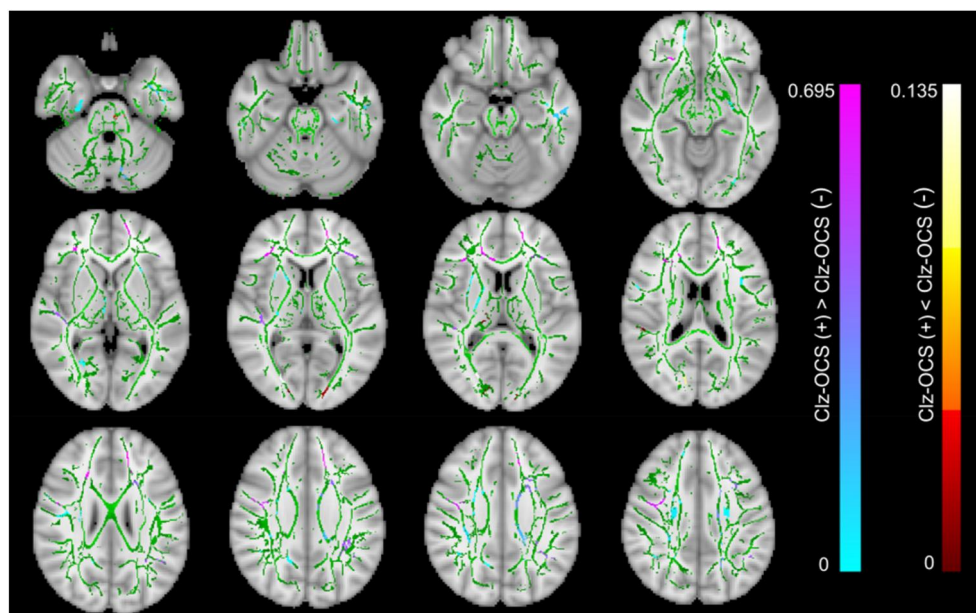
Regions	x	y	z
Clz-OCS (+) FA < Clz-OCS (-) FA			
Right occipital white matter	26	-80	9
Left occipital white matter	-10	-90	9
Clz-OCS (+) FA > Clz-OCS (-) FA			
Right medial temporal	62	-24	12
Left medial temporal	-58	-8	20
Right external capsule	32	5	-8
Right ALIC	15	3	7
Left PLIC	-14	3	7
Genu of CC	11	31	0
Right cingulum	10	-37	32
Left cingulum	-7	-36	32
Right frontoparietal peripheral white matter	-20	-16	36
Left frontoparietal peripheral white matter	21	-18	36

Abbreviations: ALIC, anterior limb of the internal capsule; CC, corpus callosum; Clz-OCS, patient with obsessive compulsive symptoms; FA, Fractional Anisotropy; PLIC, posterior limb of the internal capsule

better attention in the group with OCS, similar to the studies which showed that patients with comorbid OCS/OCD performed better than those without comorbid OCS/OCD on attention domain in patients with schizophrenia (Borkowska et al., 2003; Lee et al., 2009), although this finding was not confirmed in others (Kazhungil et al., 2017; Sahoo et al., 2018).

Two different hypotheses have been proposed regarding the increased attentional tendency in OCD. According to the vigilance hypothesis, it is suggested that OCD patients are hypersensitive to obsession-related stimuli and the perception threshold is lowered to identify and address OCD-related stimuli (Armstrong & Olatunji, 2012). In contrast, the delayed withdrawal/maintenance hypothesis suggests that these patients do not have an enhanced hypervigilance towards OCD stimuli; rather, patients with OCS have problems with getting rid of the stimuli or stay fixed in the stimulus while transitioning to later processing stages (Georgiou et al., 2005). Better attention-related performance in the clozapine group with obsessive-compulsive symptoms, compared to the group without accompanying OCS, may be explained by either of these hypothesis. On the other hand, a review which analysed the results of 113 studies with more than 3000 OCD patients showed that OCD patients performed lower in almost every cognitive domain compared to healthy controls (Abramovitch et al., 2013). Two other meta-analyses performed by Shin et al. (2014) and Snyder et al. (2015) which had included 23 studies and 32 studies, respectively, and evaluated different cognitive abilities, confirmed this observation.

An important limitation of this study was the lack of correlation analysis between FA values and neurocognitive test results/YBOCS scores as the FA values could not be calculated for each individual by the TBSS method which is an automated groupwise observer-independent whole-brain approach that analyses aligned FA images



**FIGURE 3** Red shows decreased and blue shows increased fractional anisotropy (FA) in patients with clozapine-induced obsessive compulsive symptoms (OCS) compared to patients without symptoms. (FWE-corrected threshold-cluster extend voxel P maps <0.05).

from multiple subjects to allow statistically powerful comparisons of DTI without the need for subjectively defined regions or features of interest (Smith et al., 2006). Another limitation is the small number of patients. In spite of these, we may speculate that the better performance on attention in clozapine with OCS/OCD group may be related to changes of FA in orbitofrontal gyrus. This speculation should be tested in future studies with larger samples. Heterogeneity of the sample and the possible effects of various psychotropics were the other limitations when discussing the results.

As a conclusion, this is the first study which evaluated and reported differences in the brain connectivity with TBSS based DTI assessment in patients with clozapine induced OCS/OCD. The findings of this study may shed light on the pathophysiology of clozapine-induced OCS/OCD, however what causes this different alterations in connectivity in clozapine using patients needs further investigation. Large scale, prospective follow-up studies which include data on genetic differences may help to understand why clozapine induced OCS are seen in some patients but not in others.

#### AUTHOR CONTRIBUTORS

**Şule Bıçakçı Ay:** conceptualization, data analysis/interpretation and writing. **Kader K. Oğuz:** Conceptualization, data curation, image analyses, writing. **Elçin Özçelik-Eroğlu:** Conceptualization, data analysis/interpretation, writing. **Arzu Ceylan Has:** Data curation, image analyses. **Aygün Ertuğrul:** Conceptualization, data curation, formal analyses, writing and editing. All authors reviewed and approved the final version of the manuscript.

#### ACKNOWLEDGEMENTS

This study was supported by Hacettepe University Scientific Research and Development Office (project no: 10702).

#### CONFLICT OF INTEREST

Authors state that there are no conflicts of interest.

#### DATA AVAILABILITY STATEMENT

The data that support the findings of this study are available from the corresponding author upon reasonable request.

#### ORCID

Elçin Özçelik Eroğlu  <https://orcid.org/0000-0002-2447-7263>

#### REFERENCES

- Abramovitch, A., Abramowitz, J. S., & Mittelman, A. (2013). The neuropsychology of adult obsessive-compulsive disorder: A meta-analysis. *Clinical Psychology Review, 33*(8), 1163–1171. <https://doi.org/10.1016/j.cpr.2013.09.004>
- Armstrong, T., & Olatunji, B. O. (2012). Eye tracking of attention in the affective disorders: A meta-analytic review and synthesis. *Clinical Psychology Review, 32*(8), 704–723. <https://doi.org/10.1016/j.cpr.2012.09.004>
- Benedetti, F., Giacosa, C., Radaelli, D., Poletti, S., Pozzi, E., Dallspezia, S., Falini, A., & Smeraldi, E. (2013). Widespread changes of white matter microstructure in obsessive-compulsive disorder: Effect of drug status. *European Neuropsychopharmacology: The Journal of the European College of Neuropsychopharmacology, 23*(7), 581–593. <https://doi.org/10.1016/j.euroneuro.2012.07.002>
- Berman, I., Merson, A., Viegner, B., Losonczy, M. F., Pappas, D., & Green, A. I. (1998). Obsessions and compulsions as a distinct cluster of symptoms in schizophrenia: A neuropsychological study. *The Journal of Nervous and Mental Disease, 186*(3), 150–156. <https://doi.org/10.1097/00005053-199803000-00003>
- Bezdjian, S., Baker, L. A., Lozano, D. I., & Raine, A. (2009). Assessing inattention and impulsivity in children during the Go/NoGo task. *British Journal of Developmental Psychology, 27*(2), 365–383. <https://doi.org/10.1348/026151008X314919>
- Borkowska, A., Pilaczyńska, E., & Rybakowski, J. K. (2003). The frontal lobe neuropsychological tests in patients with schizophrenia and/or obsessive-compulsive disorder. *Journal of Neuropsychiatry and Clinical Neurosciences, 15*(3), 359–362. <https://doi.org/10.1176/jnp.15.3.359>
- Cai, J., Zhang, W., Yi, Z., Lu, W., Wu, Z., Chen, J., Yu, S., Fang, Y., & Zhang, C. (2013). Influence of polymorphisms in genes SLC1A1, GRIN2B, and GRIK2 on clozapine-induced obsessive-compulsive symptoms. *Psychopharmacology, 230*(1), 49–55. <https://doi.org/10.1007/s00213-013-3137-2>
- Cangoz, B., Karakoc, E., & Seleklir, K. (2009). Trail making test: Normative data for Turkish elderly population by age, sex and education. *Journal of the Neurological Sciences, 283*(1–2), 73–78. <https://doi.org/10.1016/j.jns.2009.02.313>
- Corapcioglu, A., Aydemir, O., Yildiz, M., Esen, A., & Koroglu, E. (1999). *DSM-IV Eksen 1 bozuklukları için yapılandırılmış klinik görüşme (SCID), Klinik versiyon*. Hekimler Yayın Birliği.
- Critchlow, H. M., Maycox, P. R., Skepper, J. N., & Krylova, O. (2006). Clozapine and haloperidol differentially regulate dendritic spine formation and synaptogenesis in rat hippocampal neurons. *Molecular and Cellular Neurosciences, 32*(4), 356–365. <https://doi.org/10.1016/j.mcn.2006.05.007>
- de Wit, S. J., Alonso, P., Schwaren, L., Mataix-Cols, D., Lochner, C., Menchón, J. M., Stein, D. J., Fouche, J. P., Soriano-Mas, C., Sato, J. R., Hoexter, M. Q., Denys, D., Nakamae, T., Nishida, S., Kwon, J. S., Jang, J. H., Busatto, G. F., Cardoner, N., Cath, D. C., ..., & van den Heuvel, O. A. (2014). Multicenter voxel-based morphometry mega-analysis of structural brain scans in obsessive-compulsive disorder. *American Journal of Psychiatry, 171*(3), 340–349. <https://doi.org/10.1176/appi.ajp.2013.13040574>
- Ellison-Wright, I., & Bullmore, E. (2009). Meta-analysis of diffusion tensor imaging studies in schizophrenia. *Schizophrenia Research, 108*(1–3), 3–10. <https://doi.org/10.1016/j.schres.2008.11.021>
- Erden Aki, O., Alkan, B., & Demirsoz, T. (2013). *Adaptation of phonemic and semantic verbal fluency tests for Turkish language*. Poster presentation at World Psychiatric Association International Congress.
- Ertugrul, A., Anil Yagcioglu, A. E., Eni, N., & Yazici, K. M. (2005). Obsessive-compulsive symptoms in clozapine-treated schizophrenic patients. *Psychiatry and Clinical Neurosciences, 59*(2), 219–222. <https://doi.org/10.1111/j.1440-1819.2005.01362.x>
- First, M. B. (1997). *User's guide for the structured clinical interview for DSM-IV Axis I disorders SCID-I: Clinician version*. American Psychiatric Publishing.
- Fitzgerald, K. D., Welsh, R. C., Stern, E. R., Angstadt, M., Hanna, G. L., Abelson, J. L., & Taylor, S. F. (2011). Developmental alterations of frontal-striatal-thalamic connectivity in obsessive-compulsive disorder. *Journal of the American Academy of Child & Adolescent Psychiatry, 50*(9), 938–948. e3. <https://doi.org/10.1016/j.jaac.2011.06.011>
- Fonseka, T. M., Richter, M. A., & Müller, D. J. (2014). Second generation antipsychotic-induced obsessive-compulsive symptoms in schizophrenia: A review of the experimental literature. *Current Psychiatry Reports, 16*(11), 510. <https://doi.org/10.1007/s11920-014-0510-8>

- Gan, J., Zhong, M., Fan, J., Liu, W., Niu, C., Cai, S., Zou, L., Wang, Y., Wang, Y., Tan, C., Chan, R. C., & Zhu, X. (2017). Abnormal white matter structural connectivity in adults with obsessive-compulsive disorder. *Translational Psychiatry*, 7(3), e1062. <https://doi.org/10.1038/tp.2017.22>
- Garibotto, V., Scifo, P., Gorini, A., Alonso, C. R., Brambati, S., Bellodi, L., & Perani, D. (2010). Disorganization of anatomical connectivity in obsessive compulsive disorder: A multi-parameter diffusion tensor imaging study in a subpopulation of patients. *Neurobiology of Disease*, 37(2), 468–476. <https://doi.org/10.1016/j.nbd.2009.11.003>
- Georgiou, G. A., Bleakley, C., Hayward, J., Russo, R., Dutton, K., Eltiti, S., & Fox, E. (2005). Focusing on fear: Attentional disengagement from emotional faces. *Visual Cognition*, 12(1), 145–158. <https://doi.org/10.1080/13506280444000076>
- Goodman, W. K., Price, L. H., Rasmussen, S. A., Mazure, C., Fleischmann, R. L., Hill, C. L., Heninger, G. R., & Charney, D. S. (1989). The Yale-Brown obsessive compulsive scale. I. Development, use, and reliability. *Archives of General Psychiatry*, 46(11), 1006–1011. <https://doi.org/10.1001/archpsyc.1989.01810110048007>
- Goodman, W. K., Storch, E. A., & Sheth, S. A. (2021). Harmonizing the neurobiology and treatment of obsessive-compulsive disorder. *American Journal of Psychiatry*, 178(1), 17–29. <https://doi.org/10.1176/appi.ajp.2020.20111601>
- Grillault Laroche, D., & Gaillard, A. (2016). Induced obsessive compulsive symptoms (OCS) in schizophrenia patients under atypical 2 antipsychotics (AAPs): Review and hypotheses. *Psychiatry Research*, 246, 119–128. <https://doi.org/10.1016/j.psychres.2016.09.031>
- Gürçan, G., Şenol, Ş. H., Yağcıoğlu, A., & Ertuğrul, A. (2021). Clinical risk factors, phenomenology and the impact of clozapine induced obsessive compulsive symptoms. *Psychiatry Research*, 296, 113665. <https://doi.org/10.1016/j.psychres.2020.113665>
- Hu, X., Zhang, L., Bu, X., Li, H., Gao, Y., Lu, L., Tang, S., Wang, Y., Huang, X., & Gong, Q. (2020). White matter disruption in obsessive-compulsive disorder revealed by meta-analysis of tract-based spatial statistics. *Depression and Anxiety*, 37(7), 620–631. <https://doi.org/10.1002/da.23008>
- Hua, K., Zhang, J., Wakana, S., Jiang, H., Li, X., Reich, D. S., Calabresi, P. A., Pekar, J. J., van Zijl, P. C., & Mori, S. (2008). Tract probability maps in stereotaxic spaces: Analyses of white matter anatomy and tract-specific quantification. *NeuroImage*, 1, 336–347. <https://doi.org/10.1016/j.neuroimage.2007.07.053>
- Hwang, M. Y., Morgan, J. E., & Loscoszcy, M. F. (2000). Clinical and neuropsychological profiles of obsessive-compulsive schizophrenia: A pilot study. *Journal of Neuropsychiatry and Clinical Neurosciences*, 12(1), 91–94. <https://doi.org/10.1176/jnp.12.1.91>
- Karakaş, S., Kafadar, H., & Eski, R. (1996). Wechsler bellek Ölçeği Gelştirilmiş Formunun test-tekrar test güvenilirliği. *Türk Psikoloji Dergisi*, 11, 46–52.
- Karamustafaoglu, O., Ucsik, A., Ulusoy, M., & Erkmen, H. (1993). Yale-Brown obsessive-compulsive scale in Turkish: Reliability and validity. 29. In *Summary book* (Vol. 86). National Psychiatry Congress.
- Kay, S. R., Fiszbein, A., & Opler, L. A. (1987). The positive and negative syndrome scale (PANSS) for schizophrenia. *Schizophrenia Bulletin*, 13(2), 261–276. <https://doi.org/10.1093/schbul/13.2.261>
- Kazhungil, F., Kumar, K. J., Viswanath, B., Shankar, R. G., Kandavel, T., Math, S. B., Venkatasubramanian, G., & Reddy, Y. (2017). Neuropsychological profile of schizophrenia with and without obsessive compulsive disorder. *Asian Journal of Psychiatry*, 29, 30–34. <https://doi.org/10.1016/j.ajp.2017.04.004>
- Ke, C. L., Yen, C. F., Chen, C. C., Yang, S. J., Chung, W., & Yang, M. J. (2004). Obsessive-compulsive symptoms associated with clozapine and risperidone treatment: Three case reports and review of the literature. *The Kaohsiung Journal of Medical Sciences*, 20(6), 295–301. [https://doi.org/10.1016/S1607-551X\(09\)70121-4](https://doi.org/10.1016/S1607-551X(09)70121-4)
- Kim, D. D., Barr, A. M., Lu, C., Stewart, S. E., White, R. F., Honer, W. G., & Procyshyn, R. M. (2020). Clozapine-associated obsessive-compulsive symptoms and their management: A systematic review and analysis of 107 reported cases. *Psychotherapy and Psychosomatics*, 89(3), 151–160. <https://doi.org/10.1159/000505876>
- Kim, D. D., Barr, A. M., White, R. F., Honer, W. G., & Procyshyn, R. M. (2019). Clozapine-induced obsessive-compulsive symptoms: Mechanisms and treatment. *Journal of Psychiatry & Neuroscience*, 44(1), 71–72. <https://doi.org/10.1503/jpn.180087>
- Kostakoglu, E., Batur, S., Tiryaki, A., & Gogus, A. (1999). Pozitif ve Negatif Sendrom Ölçeğinin (PANSS) Türkçe uyarlamasının geçerlilik güvenilirliği. *Türk Psikoloji Dergisi*, 14, 23–32.
- Krüger, S., Bräunig, P., Höffler, J., Shugar, G., Börner, I., & Langkrär, J. (2000). Prevalence of obsessive-compulsive disorder in schizophrenia and significance of motor symptoms. *Journal of Neuropsychiatry and Clinical Neurosciences*, 12(1), 16–24. <https://doi.org/10.1176/jnp.12.1.16>
- Lee, M. J., Shin, Y. B., Sunwoo, Y. K., Jung, S. H., Kim, W. H., Kang, M. H., Lee, J. S., Bae, J. N., & Kim, C. E. (2009). Comparative analysis of cognitive function in schizophrenia with and without obsessive compulsive disorder. *Psychiatry Investigation*, 6(4), 286–293. <https://doi.org/10.4306/pi.2009.6.4.286>
- Lezak, M. D. (1995). *Neuropsychological assessment* (3rd ed.). Oxford University Press.
- Lin, S. K., Su, S. F., & Pan, C. H. (2006). Higher plasma drug concentration in clozapine-treated schizophrenic patients with side effects of obsessive/compulsive symptoms. *Therapeutic Drug Monitoring*, 28(3), 303–307. <https://doi.org/10.1097/01.ftd.0000211801.66569.80>
- Lysaker, P. H., Bryson, G. J., Marks, K. A., Greig, T. C., & Bell, M. D. (2002). Association of obsessions and compulsions in schizophrenia with neurocognition and negative symptoms. *Journal of Neuropsychiatry and Clinical Neurosciences*, 14(4), 449–453. <https://doi.org/10.1176/jnp.14.4.449>
- Meltzer, H. Y. (2013). Update on typical and atypical antipsychotic drugs. *Annual Review of Medicine*, 64(1), 393–406. <https://doi.org/10.1146/annurev-med-050911-161504>
- Mier, D., Schirmbeck, F., Stoessel, G., Esslinger, C., Rausch, F., Englisch, S., Eisenacher, S., de Haan, L., Meyer-Lindenberg, A., Kirsch, P., & Zink, M. (2019). Reduced activity and connectivity of left amygdala in patients with schizophrenia treated with clozapine or olanzapine. *European Archives of Psychiatry and Clinical Neuroscience*, 269(8), 931–940. <https://doi.org/10.1007/s00406-018-0965-4>
- Mukhopadhyaya, K., Krishnaiah, R., Taye, T., Nigam, A., Bailey, A. J., Sivakumar, T., & Fineberg, N. A. (2009). Obsessive-compulsive disorder in UK clozapine-treated schizophrenia and schizoaffective disorder: A cause for clinical concern. *Journal of Psychopharmacology*, 23(1), 6–13. <https://doi.org/10.1177/0269881108089582>
- Ozcelik-Eroglu, E., Ertugrul, A., Oguz, K. K., Has, A. C., Karahan, S., & Yazici, M. K. (2014). Effect of clozapine on white matter integrity in patients with schizophrenia: A diffusion tensor imaging study. *Psychiatry Research Neuroimaging*, 223(3), 226–235. <https://doi.org/10.1016/j.psychres.2014.06.001>
- Ozdemir, H., Ertugrul, A., Basar, K., & Saka, E. (2012). Differential effects of antipsychotics on hippocampal presynaptic protein expressions and recognition memory in a schizophrenia model in mice. *Progress in Neuro-Psychopharmacology & Biological Psychiatry*, 39(1), 62–68. <https://doi.org/10.1016/j.pnpbp.2012.05.009>
- Piras, F., Piras, F., Chiapponi, C., Girardi, P., Caltagirone, C., & Spalletta, G. (2015). Widespread structural brain changes in OCD: A systematic review of voxel-based morphometry studies. *Cortex: A Journal*

- Devoted to the Study of the Nervous System and Behavior*, 62, 89–108. <https://doi.org/10.1016/j.cortex.2013.01.016>
- Reznik, I., Yavin, I., Stryjer, R., Spivak, B., Gonen, N., Strous, R., Mester, R., Weizman, A., & Kotler, M. (2004). Clozapine in the treatment of obsessive-compulsive symptoms in schizophrenia patients: A case series study. *Pharmacopsychiatry*, 37, 52–56. <https://doi.org/10.1055/s-2004-815525>
- Roland, J. L., Snyder, A. Z., Hacker, C. D., Mitra, A., Shimony, J. S., Limbrick, D. D., Raichle, M. E., Smyth, M. D., & Leuthardt, E. C. (2017). On the role of the corpus callosum in interhemispheric functional connectivity in humans. *Proceedings of the National Academy of Sciences of the United States of America*, 114(50), 13278–13283. <https://doi.org/10.1073/pnas.1707050114>
- Ruscio, A. M., Stein, D. J., Chiu, W. T., & Kessler, R. C. (2010). The epidemiology of obsessive-compulsive disorder in the national comorbidity survey replication. *Molecular Psychiatry*, 15(1), 53–63. <https://doi.org/10.1038/mp.2008.94>
- Ryu, S., Oh, S., Cho, E. Y., Nam, H. J., Yoo, J. H., Park, T., Joo, Y. H., Kwon, J. S., & Hong, K. S. (2011). (Vol. 156B, pp. 949–959). Interaction between genetic variants of DLGAP3 and SLC1A1 affecting the risk of atypical antipsychotics-induced obsessive-compulsive symptoms. *American Journal of Medical Genetics Part B, Neuropsychiatric Genetics: The official publication of the International Society of Psychiatric Genetics*. <https://doi.org/10.1002/ajmg.b.31242>
- Sahoo, S., Grover, S., & Nehra, R. (2018). Comparison of neurocognitive domains in patients with schizophrenia with and without co-morbid obsessive compulsive disorder. *Schizophrenia Research*, 201, 151–158. <https://doi.org/10.1016/j.schres.2018.05.029>
- Scheltema Beduin, A. A., Swets, M., Machielsen, M., & Korver, N. (2012). Obsessive-compulsive symptoms in patients with schizophrenia: A naturalistic cross-sectional study comparing treatment with clozapine, olanzapine, risperidone, and no antipsychotics in 543 patients. *Journal of Clinical Psychiatry*, 73(11), 1395–1402. <https://doi.org/10.4088/JCP.11m07164>
- Schirmbeck, F., Esslinger, C., Rausch, F., Englisch, S., Meyer-Lindenberg, A., & Zink, M. (2011). Antiserotonergic antipsychotics are associated with obsessive-compulsive symptoms in schizophrenia. *Psychological Medicine*, 41(11), 2361–2373. <https://doi.org/10.1017/S0033291711000419>
- Schirmbeck, F., Mier, D., Esslinger, C., Rausch, F., Englisch, S., Eifler, S., Meyer-Lindenberg, A., Kirsch, P., & Zink, M. (2015). Increased orbitofrontal cortex activation associated with 'pro-obsessive' antipsychotic treatment in patients with schizophrenia. *Journal of Psychiatry & Neuroscience*, 40(2), 89–99. <https://doi.org/10.1503/jpn.140021>
- Schirmbeck, F., & Zink, M. (2012). Clozapine-induced obsessive-compulsive symptoms in schizophrenia: A critical review. *Current Neuropharmacology*, 10(1), 88–95. <https://doi.org/10.2174/157015912799362724>
- Schirmbeck, F., & Zink, M. (2013). Comorbid obsessive-compulsive symptoms in schizophrenia: Contributions of pharmacological and genetic factors. *Frontiers in Pharmacology*, 4, 99. <https://doi.org/10.3389/fphar.2013.00099>
- Shin, N. Y., Lee, T. Y., Kim, E., & Kwon, J. S. (2014). Cognitive functioning in obsessive-compulsive disorder: A meta-analysis. *Psychological Medicine*, 44(6), 1121–1130. <https://doi.org/10.1017/S003329171301803>
- Smith, S. M., Jenkinson, M., Johansen-Berg, H., Rueckert, D., Nichols, T. E., Mackay, C. E., Watkins, K. E., Ciccarelli, O., Cader, M. Z., Matthews, P. M., & Behrens, T. E. (2006). Tract-based spatial statistics: Voxelwise analysis of multi-subject diffusion data. *NeuroImage*, 31(4), 1487–1505. <https://doi.org/10.1016/j.neuroimage.2006.02.024>
- Snyder, H. R., Kaiser, R. H., Warren, S. L., & Heller, W. (2015). Obsessive-compulsive disorder is associated with broad impairments in executive function: A meta-analysis. *Clinical Psychological Science* : A *Journal of the Association for Psychological Science*, 3(2), 301–330. <https://doi.org/10.1177/2167702614534210>
- Spree, O., & Strauss, E. A. (1998). *Compendium of neuropsychological tests: Administration, norms, and commentary*. University Press.
- Subramaniam, M., Abdin, E., Vaingankar, J. A., & Chong, S. A. (2012). Obsessive-compulsive disorder: Prevalence, correlates, help-seeking and quality of life in a multiracial Asian population. *Social Psychiatry and Psychiatric Epidemiology*, 47(12), 2035–2043. <https://doi.org/10.1007/s00127-012-0507-8>
- Swets, M., Dekker, J., van Emmerik-van Oortmerssen, K., Smid, G. E., Smit, F., de Haan, L., & Schoevers, R. A. (2014). The obsessive compulsive spectrum in schizophrenia, a meta-analysis and meta-regression exploring prevalence rates. *Schizophrenia Research*, 152(2–3), 458–468. <https://doi.org/10.1016/j.schres.2013.10.033>
- Tanahashi, S., Yamamura, S., Nakagawa, M., Motomura, E., & Okada, M. (2012). Clozapine, but not haloperidol, enhances glial D-serine and L-glutamate release in rat frontal cortex and primary cultured astrocytes. *British Journal of Pharmacology*, 165(5), 1543–1555. <https://doi.org/10.1111/j.1476-5381.2011.01638.x>
- Tek, C., Uluğ, B., Rezaki, B. G., Tanriverdi, N., Mercan, S., Demir, B., & Vargel, S. (1995). Yale-Brown obsessive compulsive scale and US national institute of mental health global obsessive compulsive scale in Turkish: Reliability and validity. *Acta Psychiatrica Scandinavica*, 91(6), 410–413. <https://doi.org/10.1111/j.1600-0447.1995.tb09801.x>
- Tronchin, G., McPhilemy, G., Ahmed, M., Kilmartin, L., Costello, L., Forde, N. J., Nabulsi, L., Akudjedu, T. N., Holleran, L., Hallahan, B., Cannon, D. M., & McDonald, C. (2021). White matter microstructure and structural networks in treatment-resistant schizophrenia patients after commencing clozapine treatment: A longitudinal diffusion imaging study. *Psychiatry Research*, 298, 113772. <https://doi.org/10.1016/j.psychres.2021.113772>
- Vieira, R., Coelho, A., Reis, J., Portugal-Nunes, C., Magalhães, R., Ferreira, S., Moreira, P. S., Sousa, N., & Bessa, J. M. (2021). White matter microstructure alterations associated with paroxetine treatment response in major depression. *Frontiers in Behavioral Neuroscience*, 15, 693109. <https://doi.org/10.3389/fnbeh.2021.693109>
- Vitolo, E., Tatu, M. K., Pignolo, C., Cauda, F., Costa, T., Ando, A., & Zennaro, A. (2017). White matter and schizophrenia: A meta-analysis of voxel-based morphometry and diffusion tensor imaging studies. *Psychiatry Research: Neuroimaging*, 270, 8–21. <https://doi.org/10.1016/j.pscychres.2017.09.014>
- Wang, Y. M., Yang, Z. Y., Cai, X. L., Zhou, H. Y., Zhang, R. T., Yang, H. X., Liang, Y. S., Zhu, X. Z., Madsen, K. H., Sørensen, T. A., Møller, A., Wang, Z., Cheung, E., & Chan, R. (2020). Identifying schizo-obsessive comorbidity by tract-based spatial statistics and probabilistic tractography. *Schizophrenia Bulletin*, 46, 442–453. <https://doi.org/10.1093/schbul/sbz073>
- Wechsler, D. (1987). *The wechsler memory scale-revised*. The Psychological Corporation, Harcourt Brace Jovanovic, Inc.
- Wu, T. H., Chiu, C. C., Chen, P. Y., Huang, M. C., Chen, C. H., Shen, W. W., & Lu, M. L. (2019). Obsessive-compulsive symptoms in patients with schizophrenia: Relationships with olanzapine pharmacological parameters, psychopathology, and quality of life. *Psychiatry Research*, 276, 1–5. <https://doi.org/10.1016/j.psychres.2019.03.007>
- Yoo, S. Y., Jang, J. H., Shin, Y. W., Kim, D. J., Park, H. J., Moon, W. J., Chung, E. C., Lee, J. M., Kim, I. Y., Kim, S. I., & Kwon, J. S. (2007). White matter abnormalities in drug-naïve patients with obsessive-compulsive disorder: A diffusion tensor study before and after citalopram treatment. *Acta Psychiatrica Scandinavica*, 116(3), 211–219. <https://doi.org/10.1111/j.1600-0447.2007.01046.x>
- Zarei, M., Mataix-Cols, D., Heyman, I., Hough, M., Doherty, J., Burge, L., Winmill, L., Nijhawan, S., Matthews, P. M., & James, A. (2011). Changes in gray matter volume and white matter microstructure in adolescents with obsessive-compulsive disorder. *Biological Psychiatry*, 70(11), 1083–1090. <https://doi.org/10.1016/j.biopsych.2011.06.032>

- Zhang, Z., Ping, L., Zhai, A., & Zhou, C. (2021). Microstructural white matter abnormalities in obsessive-compulsive disorder: A coordinate-based meta-analysis of diffusion tensor imaging studies. *Asian Journal of Psychiatry*, 55, 102467. <https://doi.org/10.1016/j.ajp.2020.102467>
- Zhao, W., Guo, S., He, N., Yang, A. C., Lin, C. P., & Tsai, S. J. (2018). Callosal and subcortical white matter alterations in schizophrenia: A diffusion tensor imaging study at multiple levels. *NeuroImage Clinical*, 20, 594–602. <https://doi.org/10.1016/j.nicl.2018.08.027>

**How to cite this article:** Biçakcı Ay, Ş., Oğuz, K. K., Özçelik Eroğlu, E., Has, A. C., & Ertuğrul, A. (2023). A diffusion tensor imaging study in schizophrenia patients with clozapine induced obsessive compulsive symptoms. *Human Psychopharmacology: Clinical and Experimental*, 38(1), e2857. <https://doi.org/10.1002/hup.2857>