



A Rare Case of Primary Cardiac Diffuse Large B-cell Lymphoma Imaged with ¹⁸F-FDG PET/CT

¹⁸F-FDG PET/BT ile Görüntülenen Nadir Bir Primer Kardiyak Diffüz Büyük B-hücreli Lenfoma Olgusu

Seval Erhamamcı¹, Nesrin Aslan²

¹Başkent University Faculty of Medicine, Başkent University İstanbul Hospital, Department of Nuclear Medicine, İstanbul, Turkey

²Neolife Medical Center; Clinic of Nuclear Medicine, İstanbul, Turkey

Abstract

Primary cardiac lymphoma is an extremely rare malignancy. A few reports about the findings of ¹⁸fluorine-fluorodeoxyglucose (¹⁸F-FDG) positron emission tomography/computed tomography (PET/CT) imaging has been presented. We report a rare case of a 70-year-old male with diagnosed primary intracardiac diffuse large B-cell lymphoma referred for ¹⁸F-FDG PET/CT imaging for initial staging. The scan revealed an abnormal hypermetabolic gross tumoral lesion involving the right atrium and auricula. After completing three cycles of chemotherapy, post-treatment ¹⁸F-FDG PET/CT showed complete response.

Keywords: Primary cardiac tumor diffuse large B-cell lymphoma, ¹⁸F-FDG, PET/CT

Öz

Primer kardiyak lenfoma oldukça nadir görülen bir malignitedir. ¹⁸Flor-florodeoksiglukoz (¹⁸F-FDG) pozitron emisyon tomografisi/bilgisayarlı tomografi (PET/BT) görüntüleme bulguları hakkında birkaç bildiri sunulmuştur. Başlangıç evreleme amacıyla ¹⁸F-FDG PET/BT görüntüleme için gönderilen primer intrakardiyak diffüz büyük B-hücreli lenfoma tanısı almış 70 yaşında nadir bir erkek hastayı sunduk. Görüntüleme sağ atrium ve aurikulayı kapsayan anormal hipermetabolik büyük tümör lezyonunu ortaya çıkardı. Üç kür kemoterapi tamamlandıktan sonra, tedavi sonrası ¹⁸F-FDG PET/BT tam yanıt gösterdi.

Anahtar kelimeler: Primer kardiyak tümörler, diffüz büyük B-hücreli lenfoma, ¹⁸F-FDG, PET/BT

Address for Correspondence: Seval Erhamamcı Assoc. Prof., Başkent University Faculty of Medicine, Başkent University İstanbul Hospital, Department of Nuclear Medicine, İstanbul, Turkey

Phone: +90 216 554 15 00 **E-mail:** sevaler@yahoo.com ORCID ID: orcid.org/0000-0001-5016-4650

Received: 10.05.2020 **Accepted:** 17.01.2021

©Copyright 2022 by Turkish Society of Nuclear Medicine
Molecular Imaging and Radionuclide Therapy published by Galenos Yayınevi.

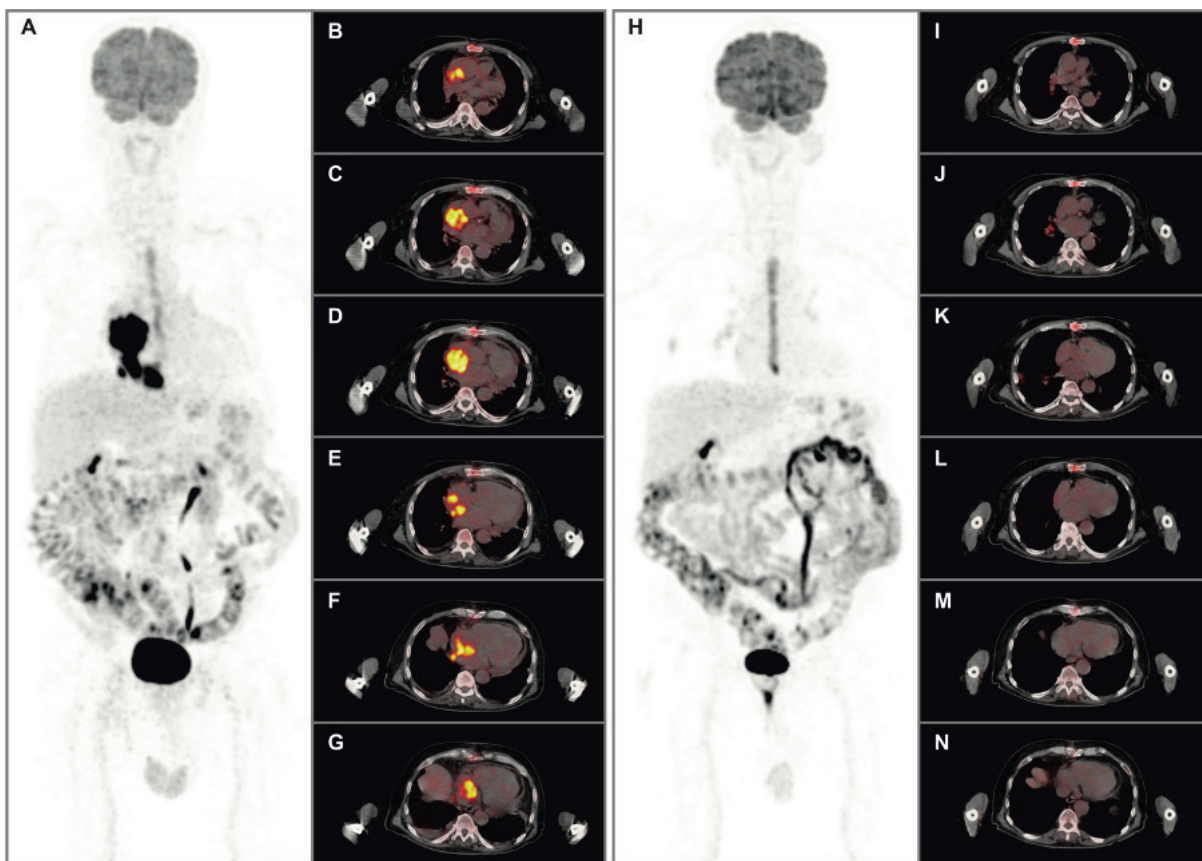


Figure 1. A 70-year-old male was admitted order to investigate dyspnea and weakness. Computed tomography (CT) imaging of the thorax revealed a large soft tissue mass in the right atrium (RA). He underwent excisional biopsy of the mass in the RA with histopathological result of diffuse large B-cell lymphoma (DLBCL). For initial staging, ^{18}F -fluorine-fluorodeoxyglucose (^{18}F -FDG) positron emission tomography (PET)/CT imaging was requested. The scan MIP (A) and transaxial fused (B, C, D, E, F, G) images demonstrated intense ^{18}F -FDG uptake with an maximum standardized uptake value (SUV_{max}) of 26.6 in an irregular gross tumoral lesion, approximately 6 cm in diameter, in the RA and auricula. Mild pericardial effusion without ^{18}F -FDG uptake and bilateral pleural effusion without ^{18}F -FDG uptake was seen. Linear increased ^{18}F -FDG uptake in the sternum was observed due to thoracotomy. There were no other findings elsewhere in the body, which suggested a metastatic disease. The patient underwent three cycles of combination chemotherapy with rituximab, cyclophosphamide, doxorubicin, vincristine and prednisone (R-CHOP). To therapy response early evaluation, post-treatment ^{18}F -FDG PET/CT MIP (H) and transaxial fused (I, J, K, L, M, N) images revealed complete resolution of the tumoral lesion and, pericardial and pleural effusion compared with baseline scan. Newly developed slightly hypermetabolic activities were seen in the right lung hilar lymph nodes, in the right lower lobe superior segment and on the right upper lobe bronchus level, which may be due to an infectious or inflammatory etiology. Primary cardiac lymphoma (PCL) is an extremely rare malignancy, comprising about 1% of primary cardiac tumors, which is accompanied by a poor prognosis, unless it is timely diagnosed and treated (1,2). PCL is most commonly reported to be a DLBCL, and the RA and right ventricle are the two most frequently involved sites (1,2). ^{18}F -FDG PET/CT imaging has become an essential method for staging and treatment response evaluation of lymphomas (3). A few reports have been presented about the ^{18}F -FDG PET/CT findings of PCLs due to its rare presentation, and most of the information comes from case reports and case series (4,5,6). specific findings of ^{18}F -FDG PET/CT imaging of primary cardiac DLBCL is reported to be the combination of a large right-sided cardiac mass, a large pericardial effusion and a high SUV_{max} value, compared with other cardiac malign and benign tumors (4,5,6). This case had a gross tumoral lesion with high SUV_{max} located in the RA, consistent with previous reports. However, the patient had mild pericardial effusion without ^{18}F -FDG uptake. Furthermore, after three chemotherapy cycles, the patient showed a good response to treatment and considered to have a better prognosis with a lower recurrence rate.

Ethics

Informed Consent: Written informed consent was obtained.

Peer-review: Externally and internally peer-reviewed.

Authorship Contributions

Concept: S.E., Design: S.E., Data Collection or Processing: S.E., N.A., Analysis or Interpretation: S.E., N.A., Literature Search: S.E., Writing: S.E.

Conflict of Interest: No conflict of interest was declared by the authors.

Financial Disclosure: The authors declared that this study received no financial support.

References

1. Petrich A, Cho SI, Billett H. Primary cardiac lymphoma: an analysis of presentation, treatment, and outcome patterns. *Cancer* 2011;117:581-589.
2. Coulier B, Colin GC, Tourmous H, Floris N, Van Eeckhout P, Scavée C. Imaging features of primary cardiac lymphoma. *Diagn Interv Imaging* 2018;99:115-117.
3. Cheson BD. PET/CT in lymphoma: current overview and future directions. *Semin Nucl Med* 2018;48:76-81.
4. Kikuchi Y, Oyama-Manabe N, Manabe O, Naya M, Ito YM, Hatanaka KC, Tsutsui H, Terae S, Tamaki N, Shirato H. Imaging characteristics of cardiac dominant diffuse large B-cell lymphoma demonstrated with MDCT and PET/CT. *Eur J Nucl Med Mol Imaging* 2013;40:1337-1344.
5. Kaida H, Kumode T, Kimura M, Ishii K. 18F-FDG PET/CT finding of primary cardiac lymphoma. *Clin Nucl Med* 2020;45:319-321.
6. Castelli JB, Alexandre L, Futuro G, Scanavacca M, Soares Júnior J. Primary cardiac lymphoma detected by 18F-FDG PET scan: a case report. *J Nucl Cardiol* 2011;18:974-977.