



Ultrasound-guided versus blind subacromial corticosteroid and local anesthetic injection in the treatment of subacromial impingement syndrome: A randomized study of efficacy

Najibeh Akbari, MD¹ , Selin Ozen, MBBS BSc¹ , Huma Bölük Şenlikçi, MD¹ ,
Murat Haberal, MD² , Nuri Çetin, MD¹ 

¹Department of Physical and Rehabilitation Medicine, Başkent University Faculty of Medicine, Ankara, Turkey

²Department of Radiology, Başkent University Faculty of Medicine, Ankara, Turkey

Shoulder pain is an important cause of musculoskeletal pain with studies naming shoulder pain as the third most common musculoskeletal complaint in orthopedic practice.^[1] Subacromial impingement syndrome (SIS) accounts for up to 74% of all complaints of shoulder pain.^[2] Subacromial impingement syndrome can result in pain, functional loss, and disability and has a negative impact on activities of daily living and ability to work.^[3] Subacromial impingement syndrome develops as a result of suprahumeral structures becoming squeezed between the anteroinferior surface of the acromion and the coracoacromial arcus resulting in functional compromise of the compressed subacromial structures: the rotator cuff, long head of the biceps tendons, and the bursae.^[4,5]

Glucocorticoid injections used in the treatment of SIS improve functionality and compliance to physical therapy.^[6] In clinical practice, physicians often use a combination of corticosteroid and local anesthetics (LAs) in local soft tissue injections.^[7] Shoulder injections are either performed “blindly” using anatomical

ABSTRACT

Objectives: This study aims to compare the effects of ultrasound (US)-guided and blind subacromial corticosteroid and local anesthetic (LA) injection in the treatment of subacromial impingement syndrome (SIS) on shoulder pain, range of motion (ROM), and functionality.

Patients and methods: The prospective study was conducted between 01 February 2017 and 31 May 2017. A total of 29 patients with clinical findings and magnetic resonance imaging (MRI) consistent with SIS were randomized into two groups: 14 patients received US-guided subacromial corticosteroid and LA injection and 15 patients received a blind subacromial corticosteroid and LA injection. Patients were evaluated before and one month after treatment. One patient was lost to follow up. The primary outcome measure was a visual analog scale (VAS) for shoulder pain. Secondary outcomes were active shoulder ROM in flexion and abduction, the Disabilities of the Arm, Shoulder, and Hand (DASH) questionnaire and the modified Constant-Murley Score (CMS).

Results: Twenty eight patients (11 males, 17 females; mean age 39.5 in the US guided group and 42.5 in the blind group; range 20 to 64 years in both groups) completed the study. There was a significant improvement in VAS for shoulder pain, active ROM, DASH questionnaire score and modified CMS in both groups four weeks after treatment ($p < 0.05$). There was no between-group difference in VAS, ROM or DASH questionnaire scores. Following treatment, the modified CMS in the US-guided injection group was higher than in the blind injection group ($p = 0.02$). However, when the mean change in modified CMS in the US-guided injection group was compared to that of the blind injection group, the difference was insignificant ($p = 0.23$).

Conclusion: Both US-guided and blind subacromial steroid injection improve shoulder pain, ROM, and functionality in SIS; one treatment option was not found to be superior to the other. Therefore, blind injection can be performed in clinical settings where US is not available. Equally, blind injection can also be performed in patients who have a definite diagnosis of SIS based on clinical and MRI findings.

Keywords: Injection, shoulder impingement syndrome, steroids, ultrasound.

Received: August 22, 2019

Accepted: October 22, 2019

Published online: March 02, 2020

Correspondence: Selin Ozen, MD, Başkent Üniversitesi Tıp Fakültesi Fiziksel Tıp ve Rehabilitasyon Anabilim Dalı, 06490 Bahçelievler, Ankara, Türkiye.

E-mail: selinhassan@hotmail.com

Doi: 10.5606/ehc.2020.71056

Citation: Akbari N, Ozen S, Bölük Şenlikçi H, Haberal M, Çetin N. Ultrasound-guided versus blind subacromial corticosteroid and local anesthetic injection in the treatment of subacromial impingement syndrome: A randomized study of efficacy. Jt Dis Relat Surg 2020;31(1):115-122.

landmarks to guide needle placement or using image guidance, such as ultrasonography. Inevitably, the question of the most efficacious method of injection in the treatment of SIS arises. Traditionally, the blind posterolateral approach is widely preferred. However, the belief that guaranteed correct positioning of the needle and drug administration results in improved clinical recovery in SIS has resulted in increased use of ultrasound (US)-guided subacromial injections.

Even though the literature discusses the positive aspects of US-guided shoulder joint injections in SIS,^[8] there are studies which have disproved its superiority to blind injection.^[9-11] Despite this, to date, there is no concrete guidance on best clinical practice and it is unclear whether or not US-guided subacromial injection improves patient-relevant outcomes in SIS.

The null hypothesis of this study was that there would be no difference in shoulder pain, range of motion (ROM), and functional outcome measures in those receiving US-guided subacromial corticosteroid injection when compared to those receiving blind injection in the treatment of SIS. Therefore, in this study, we aimed to compare the effects of US-guided and blind subacromial corticosteroid and LA injection in the treatment of SIS on shoulder pain, ROM, and functionality.

PATIENTS AND METHODS

This prospective randomized study was conducted at Baskent University Faculty of Medicine, Physical Medicine and Rehabilitation (PMR) Department Outpatient clinic between 01 February 2017 and 31 May 2017. Forty-two patients presenting to the aforementioned Faculty of Medicine with shoulder pain were screened by a PMR specialist for study enrollment. Patients with (i) a history of posterolateral shoulder pain for more than three months which increased on shoulder abduction; (ii) painful restriction of active flexion and/or abduction of the shoulder with more restriction on passive ROM; (iii) a positive Hawkins-Kennedy impingement sign;^[12] and (iv) magnetic resonance imaging (MRI) consistent with SIS (rotator cuff impingement) were included in the study. Magnetic resonance imaging criteria for SIS included: signal intensity changes in tendons suggestive of tendinosis, acromial spur indentation without microstructural changes of rotator cuff muscles and tendons and disappearance of the subacromial fat in coronal plane T1 weighted images.^[13] Exclusion criteria included (i) a history of inflammatory arthritis; (ii) erythema/swelling of the shoulder joint; (iii) neurological deficit of the upper extremities; (iv) shoulder dislocation;

(v) presence of partial/full thickness rotator cuff tear, bursitis, calcific tendinitis, or labral tears on MRI; (vi) significant chronic disease; (vii) a history of or current malignancy; (viii) shoulder trauma occurring within the past three months; (ix) SIS treatment within the past three months; (x) physical therapy of the ipsilateral shoulder within the past six months; (xi) non-consent to subacromial injection; (xii) cases in which surgical intervention was deemed to be the appropriate treatment of choice; (xiii) cervical disc/suspicion of a cervical disc pathology; or (xiv) pregnancy and breastfeeding.

Twenty-nine patients were included in the study and randomized into two groups using the Random Allocation Software version 1.0 (developed by -M. Saghaei, MD., Department of Anesthesia, Isfahan University of Medical Sciences, Isfahan, Iran).^[14,15] The randomization process was conducted by a junior doctor of the PMR department who had no other involvement in the study. One group received blind and the other received US-guided subacromial corticosteroid injection to the SIS shoulder. Patients were advised to take only simple analgesics (paracetamol) for shoulder pain for the duration of the study when necessary and adherence to this rule was checked at the four week post injection follow-up. The patients were not given physical therapy or a home exercise program or advice regarding activity modification for the duration of the study. The study protocol was approved by the Baskent University Institutional Review Board and Ethics Committee (decision number KA16/350, date 26.01.2017). A written informed consent was obtained from each patient. The study was conducted in accordance with the principles of the Declaration of Helsinki.

All US-guided subacromial corticosteroid injections were performed by a radiologist with 10 years of experience in musculoskeletal US working in the Radiology Department of Baskent University Faculty of Medicine. US imaging of the shoulder was obtained using the 2014 model Siemens Acuson S2000 (Siemens Healthcare, Erlangen, Germany) and a 9 MHz linear probe. The patient was seated and the shoulder was internally rotated with the ipsilateral hand positioned on the hip in the modified Crass position. Methylprednisolone acetate 40 mg in 1 mL and procaine 2% 4 mL were prepared in a 5 mL syringe. The anterolateral aspect of the shoulder was cleaned using 10% povidone iodine solution. The US probe was placed on the anterolateral aspect of the shoulder and the subacromial bursa was visualized. A 21-gauge needle was used to enter the anteromedial aspect of the shoulder under continuous US guidance.

Once the bevel of the needle was visualized in the subacromial bursa, the solution was injected.

The blind subacromial injection was performed in the PMR Outpatient Department of Baskent University Faculty of Medicine by a single physiatrist with more than 10 years of experience in the field. The injection was performed using a standard posterolateral approach and an aseptic technique.^[16] The patient was seated upright with the arms resting comfortably at the side. The distal, lateral, and posterior edges of the acromion were palpated and the needle was inserted just inferiorly to the posterolateral edge of the acromion and directed towards the opposite nipple. Aspiration was performed to ensure that the needle was not in a blood vessel prior to administration of the drug. Methylprednisolone acetate 40 mg in 1 mL and procaine 2% 4 mL were injected slowly using a 21-gauge needle 1 cm into the subacromial space.

All patients were screened and assessed for study participation by a single PMR specialist prior to the procedure and at four weeks post-injection. This PMR specialist was blinded to the method of injection applied and had no involvement in the injection procedure. Many studies on the effects of corticosteroid injection in the treatment of SIS have shown that a decrease in shoulder pain and an increase in ROM and function are observed three-four weeks following subacromial injection.^[17] Therefore, post-injection fourth week was considered a suitable time for patient evaluation.

On evaluation of the patients, clinical and demographic information including sex, age, and affected shoulder were recorded. The primary outcome measure of the study was shoulder pain as measured by a visual analog scale (VAS) from 0-10 cm marked in 1 cm increments where 0 cm represents no pain and 10 cm the most severe pain imaginable. Secondary outcomes included goniometric active shoulder flexion and abduction ROM measurements, the Disabilities of the Arm, Shoulder, and Hand (DASH) questionnaire, and the modified Constant-Murley score (CMS).

The DASH is a self-administered region-specific questionnaire developed as an outcome measure of upper-extremity symptoms and disability.^[18] The DASH consists of a 30-item Likert scale scored from 1 to 5. Twenty-one of the items are based on the difficulty in performing various physical activities due to arm, shoulder, or hand problems where a score of 1 signifies no difficulty and a score of 5 signifies an inability to perform the function. Five items question

the severity of pain, activity-related pain, tingling, weakness, and stiffness symptoms where a score of 1 signifies the absence of the symptom and 5 signifies extreme severity of the symptom. The final four items question the impact of arm, shoulder, and hand problems on social activities, work, sleep, and self-image. A score of 1 signifies no impact and 5 severe impact. The total score of all the items are then used to calculate a DASH questionnaire score ranging from 0 (no disability) to 100 (most severe disability). In this study, the Turkish version of the DASH was used.^[19]

The modified CMS protocol entails both a subjective and objective evaluation of functionality in patients with shoulder disorders including an evaluation of pain (15 points), activities of daily living (20 points), movement of the shoulder (40 points), and strength (25 points).^[20] A total score out of 100 is obtained; the higher the score the better the patient's functionality. In this study, the Turkish version of the modified CMS was used.^[21]

Statistical analysis

The power analysis was performed based on the mean and standard deviation of the Constant score variables as previously used by Ucuncu et al.^[22] The Pass 11 NCSS (LLC, Kaysville, Utah, USA) statistical program was used. According to the power analysis calculation, in order to obtain a power of 95% with a 5% type I error, each group would require at least 14 participants.

All data were analyzed using the International Business Machines Statistical Package for the Social Sciences (IBM SPSS) version 22.0 software (IBM Corp., Armonk, NY, USA). The normal distribution of the variables was evaluated visually using histograms and probability graphs, and analytically using the Kolmogorov-Smirnov and Shapiro-Wilk tests. Due to the non-normal distribution of the data, descriptive analyses were presented using median (minimum-maximum) values. The Mann-Whitney U test was used for intergroup comparison of the qualitative variables. Within group pre- and post-treatment values were analyzed using the Wilcoxon test. Dichotomous demographic data were evaluated using the chi-square test. P values <0.05 were considered statistically significant.

RESULTS

Fourteen of the 29 patients included in the study received US-guided subacromial corticosteroid injection. The remaining 15 patients received blind subacromial corticosteroid injection. One

TABLE I
Baseline characteristics of patients

	US-guided subacromial injection (n=14)				Blind subacromial injection (n=14)				p
	n	%	Median	Min-Max	n	%	Median	Min-Max	
Age (year)			39.5	20-64			42.5	20-64	0.21
Sex									0.69
Male	6	42.9			5	35.7			
Female	8	57.1			9	64.3			
Affected shoulder right	6	42.9			8	57.1			0.45
VAS for pain (cm)									0.60
Pre-injection			9	4-10			8.5	4-10	
Active shoulder flexion ROM°									0.38
Pre-injection			150	80- 170			140	70-165	
Active shoulder abduction ROM°									0.57
Pre-injection			150	80-170			130	70-160	
DASH score									0.54
Pre-injection			110	45-145			117	62-141	
Constant-Murley score									0.67
Pre-injection			39	19-73			37	13-80	

US: Ultrasound; Min: Minimum; Max: Maximum; VAS: Visual analog scale; ROM: Range of motion; DASH: Disabilities of the Arm, Shoulder, and Hand.

patient from the blind injection group was lost to follow-up, thus a total of 28 patients completed the study. A flowchart of the recruitment and follow-up of participants is depicted in Figure 1. The mean age of the study participants was 39.5 years (range, 20 to 64 years) in the US-guided injection group and 42.5 years (range, 20 to 64 years) in the blind injection group (p=0.21). The right shoulder

was affected in six patients (42.9%) in the US-guided injection group and in eight patients (57.1%) in the blind injection group. Baseline characteristics of both groups are given in Table I.

Pre- and post-injection fourth week VAS, shoulder ROM, DASH questionnaire score, and modified CMS in the US-guided injection and blind injection groups can be seen in Table II. Four weeks after treatment,

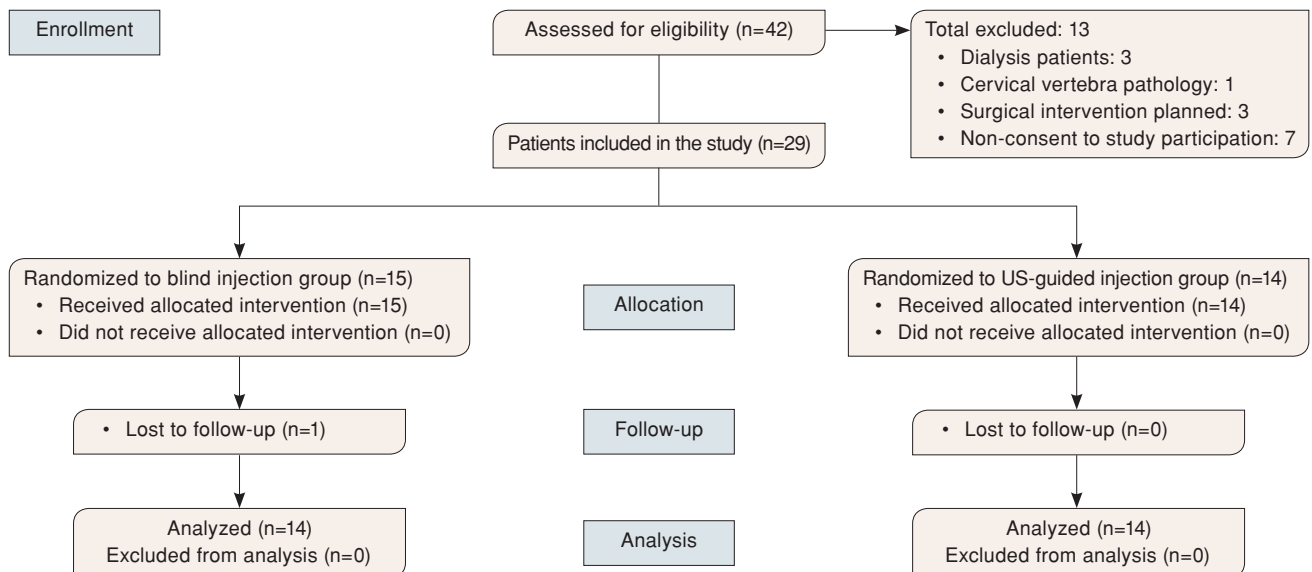


FIGURE 1. Design and flow of participants through trial following CONSolidated Standards of Reporting Trials 2010 guidelines.

TABLE II
Results of pre- and post-injection fourth week outcome measures in both treatment groups

	US-guided subacromial injection (n=14)		Blind subacromial injection (n=14)		p
	Median	Min-Max	Median	Min-Max	
VAS for pain (cm)			8.5	4-10	
Pre-injection	9	4-10			0.60
4 weeks post-injection	1	1-7	2	1-7	0.67
p		0.001		0.001	
Δ VAS for pain	6.5	2-9	6.5	2-8	0.54
Active shoulder flexion ROM°					
Pre-injection	150	80-170	140	70-165	0.38
4 weeks post-injection	170	140-180	180	130-180	0.31
p		0.001		0.001	
Δ Active shoulder flexion ROM	30	10-90	35	10-90	0.54
Active shoulder abduction ROM°					
Pre-injection	150	80-170	130	70-160	0.57
4 weeks post-injection	180	135-180	170	140-180	0.67
p		0.001		0.001	
Δ active shoulder abduction ROM	30	10-90	40	20-90	0.48
DASH score					
Pre-injection	110	45-145	117	62-141	0.54
4 weeks post-injection	35	30-86	51	31-83	0.06
p		0.001		0.001	
Δ DASH score	64.5	15-107	64	30-87	0.95
Constant-Murley score					
Pre-injection	39	19-73	37	13-80	0.67
4 weeks post-injection	95	49-100	85	53-97	0.02
p		0.001		0.001	
Δ Constant-Murley score	56	18-63	38.5	16-79	0.23

US: Ultrasound; Min: Minimum; Max: Maximum; VAS: Visual analog scale; ROM: range of motion; ASH: Disabilities of the Arm, Shoulder, and Hand; Δ Mean change.

there was a significant reduction in VAS for shoulder pain ($p=0.001$), an increase in active shoulder flexion ($p=0.001$) and abduction ($p=0.001$), and a reduction in DASH questionnaire score ($p=0.001$) in the US-guided injection group. There was also a significant reduction in VAS for pain ($p=0.001$), an increase in active shoulder flexion ($p=0.001$) and abduction ($p=0.001$), and a reduction in DASH questionnaire score ($p=0.001$) in the blind injection group. There was no between-group difference prior to, or four weeks post-treatment.

Modified CMS significantly improved in both groups four weeks after treatment ($p<0.05$). Even though there was a significantly higher modified CMS in the US-guided injection group compared to the blind injection group four weeks post-treatment ($p=0.02$), there was no significant difference in the

mean change in modified CMS between the two groups ($p=0.23$). No side effects of treatment were seen at the time of injection or at the one-month follow-up.

DISCUSSION

The aim of this study was to compare the outcomes of blind versus US-guided subacromial corticosteroid and LA injection in the treatment of SIS. Shoulder pain, ROM, and functionality significantly improved in both groups ($p<0.01$).^[23] A between-group difference was only found in the four-week post-injection modified CMS; those who received US-guided injection had a higher score ($p=0.02$).

Similar findings were present in a randomized double blind trial study by Cole et al.^[24] comparing blind versus US-guided shoulder joint corticosteroid

injection in SIS; in this study, a reduction in VAS for shoulder pain with overhead activities and an improvement in American Shoulder and Elbow Surgeons score for pain and ADL were present in both groups with no between-group difference. Similar findings were also present in a study by Dogu et al.^[11] and a systematic review by Bloom et al.^[10] A more recent systematic review and meta-analysis by Aly et al.^[25] showed that US-guided injections were more accurate for all shoulder girdle injections (biceps tendon sheath, acromioclavicular and glenohumeral joint) when compared to landmark-guided injection, with the exception of subacromial space injections. Even so, based on the three subacromial injection studies included in this review, the US groups did have a significantly greater reduction in pain and improvement in function at six weeks post-injection.

A large systematic review of the literature by Wu et al.^[26] which included seven studies and 445 cases of shoulder pain also showed that US-guided injection resulted in significantly greater improvement in VAS for shoulder pain when compared to blind injection. In addition, in two of the studies included in this review, improvement in the Shoulder Disability Questionnaire was also found to be greater in the US-guided groups. The between-group difference in favor of US-guided injection in some of these studies may have occurred due to the difference in experience between those applying the injection, the difference in pre-injection clinical severity of the shoulder pain between the groups, and the placebo effect of US.

In a study by Rutten et al.,^[27] 20 SIS patients were randomized into blind and US-guided injection groups and a mixture of LA, steroid, and radiocontrast was injected into the subacromial bursa. Correct anatomical administration of the mixture was then verified using MRI in all patients both in the blind and US-guided injection group. This may suggest that experience of the clinician performing the US-guided/blind injection is a more important factor affecting correct injection site when compared to the chosen technique. In our study, imaging was not obtained post-procedure to verify correct anatomical location of the drug in the blind injection group; however, the significant clinical improvement in both blind and US-guided injection groups suggests that the steroid reached the desired anatomical area.

Although rare, occurrence of tendon rupture post-steroid injection has been reported in the literature.^[22] Other side effects include pain

and erythema of the shoulder. No side effects of treatment were seen in this study. The small sample size, experienced nature of the clinicians performing the injections, and the exclusion criteria may have reduced the risk of complications. Naturally, those with a diagnosis of inflammatory arthritis or common causes of shoulder pain were excluded from the study as these could act as confounding factors when interpreting the results; the positive effects of intraarticular steroid injection on reducing pain and stiffness in inflammatory arthritides are well known.^[28] Equally, those with other causes of shoulder pain, such as rotator cuff tears, shoulder dislocation, neurological deficits of the arms, a recent history of shoulder trauma or cervical disc pathology were also excluded as these pathologies contribute to the level of pain, shoulder ROM, and function independent of SIS and thus would also affect the findings. Patients with erythema/swelling of the shoulder joint were excluded as both are causes of shoulder pain and loss of function in their own right.^[28] Even though the results are limited, the beneficial effects of physical therapy modalities and exercise in the treatment of SIS have been shown.^[29,30] Therefore, those with a recent history of physical therapy to the ipsilateral shoulder were also excluded.

The main strengths of this study: (i) the blind and US-guided subacromial injections were performed by a PMR specialist and radiologist, respectively, with over ten years of experience in this field; (ii) the randomized nature of the study; (iii) the post-treatment follow-up of four weeks after the procedure; (iv) use of the standardized Turkish versions of both the DASH and modified CMS questionnaires to determine shoulder function; (v) use of two questionnaires to assess shoulder function; and (vi) the acceptance of both the DASH questionnaire and modified CMS as valid measures of shoulder pathology by the American Academy of Orthopedic Surgeons.^[31]

Limitations of this study include (i) the relatively small sample size; (ii) the lack of long-term follow-up results; and (iii) the lack of landmark guidance to determine the correct anatomical location of steroid.

In conclusion, the findings of this study show that both blind and US-guided subacromial steroid injection improve shoulder pain, ROM, and functionality in SIS; one treatment option was not found to be superior to the other. Therefore, blind injection can be performed with similar clinical outcomes to US-guided injection in clinical settings where US is still not available. Equally, blind injection

can also be performed in patients who have a definite diagnosis of SIS based on clinical and MRI findings.

Declaration of conflicting interests

The authors declared no conflicts of interest with respect to the authorship and/or publication of this article.

Funding

This study was supported by the Baskent University Research Fund.

REFERENCES

1. Urwin M, Symmons D, Allison T, Brammah T, Busby H, Roxby M, et al. Estimating the burden of musculoskeletal disorders in the community: the comparative prevalence of symptoms at different anatomical sites, and the relation to social deprivation. *Ann Rheum Dis* 1998;57:649-55.
2. Ostör AJ, Richards CA, Prevost AT, Speed CA, Hazleman BL. Diagnosis and relation to general health of shoulder disorders presenting to primary care. *Rheumatology (Oxford)* 2005;44:800-5.
3. Michener LA, McClure PW, Karduna AR. Anatomical and biomechanical mechanisms of subacromial impingement syndrome. *Clin Biomech (Bristol, Avon)* 2003;18:369-79.
4. Fu FH, Harner CD, Klein AH. Shoulder impingement syndrome. A critical review. *Clin Orthop Relat Res* 1991;269:162-73.
5. van der Windt DA, Koes BW, de Jong BA, Bouter LM. Shoulder disorders in general practice: incidence, patient characteristics, and management. *Ann Rheum Dis* 1995;54:959-64.
6. Karthikeyan S, Kwong HT, Upadhyay PK, Parsons N, Drew SJ, Griffin D. A double-blind randomised controlled study comparing subacromial injection of tenoxicam or methylprednisolone in patients with subacromial impingement. *J Bone Joint Surg [Br]* 2010;92:77-82.
7. Boonard M, Sumanont S, Arirachakaran A, Apiwatanakul P, Boonrod A, Kanchanatawan W, et al. Short-term outcomes of subacromial injection of combined corticosteroid with low-volume compared to high-volume local anesthetic for rotator cuff impingement syndrome: a randomized controlled non-inferiority trial. *Eur J Orthop Surg Traumatol* 2018;28:1079-87.
8. Soh E, Li W, Ong KO, Chen W, Bautista D. Image-guided versus blind corticosteroid injections in adults with shoulder pain: a systematic review. *BMC Musculoskelet Disord* 2011;12:137.
9. Cole BF, Peters KS, Hackett L, Murrell GA. Ultrasound-guided versus blind subacromial corticosteroid injections for subacromial impingement syndrome: a randomized, double-blind clinical trial. *Am J Sports Med* 2016;44:702-7.
10. Bloom JE, Rischin A, Johnston RV, Buchbinder R. Image-guided versus blind glucocorticoid injection for shoulder pain. *Cochrane Database Syst Rev* 2012;(8):CD009147.
11. Dogu B, Yucel SD, Sag SY, Bankaoglu M, Kuran B. Blind or ultrasound-guided corticosteroid injections and short-term response in subacromial impingement syndrome: a randomized, double-blind, prospective study. *Am J Phys Med Rehabil* 2012;91:658-65.
12. Hawkins RJ, Kennedy JC. Impingement syndrome in athletes. *Am J Sports Med* 1980;8:151-8.
13. Garving C, Jakob S, Bauer I, Nadjar R, Brunner UH. Impingement syndrome of the shoulder. *Dtsch Arztebl Int* 2017;114:765-76.
14. Saghaei M. Random allocation software for parallel group randomized trials. *BMC Med Res Methodol* 2004;4:26.
15. Random Allocation Software [Internet]. Tripod: Saghaei M; 2004. Tripod. Cited 2019 Jun 24]. Available at: <http://mahmoodsaghaei.tripod.com/Softwares/randalloc.html>
16. Tallia AF, Cardone DA. Diagnostic and therapeutic injection of the shoulder region. *Am Fam Physician* 2003;67:1271-8.
17. Burger M, Africa C, Droomer K, Norman A, Pheiffe C, Gericke A, et al. Effect of corticosteroid injections versus physiotherapy on pain, shoulder range of motion and shoulder function in patients with subacromial impingement syndrome: A systematic review and meta-analysis. *S Afr J Physiother* 2016;72:318.
18. Hudak PL, Amadio PC, Bombardier C. Development of an upper extremity outcome measure: the DASH (disabilities of the arm, shoulder and hand) [corrected]. The Upper Extremity Collaborative Group (UECG). *Am J Ind Med* 1996;29:602-8.
19. Düger T, Edibe Y, Öksüz Ç, Yörükan S, Bilgütay BS. Kol, omuz ve el sorunları (Disabilities of the Arm, Shoulder and Hand-DASH) anketi Türkçe uyarlamasının güvenilirliği ve geçerliliği. *Fiz Rehabil.* 2006;17:99-107.
20. Ban I, Troelsen A, Christiansen DH, Svendsen SW, Kristensen MT. Standardised test protocol (Constant Score) for evaluation of functionality in patients with shoulder disorders. *Dan Med J* 2013;60:A4608.
21. Çelik D. Turkish version of the modified Constant-Murley score and standardized test protocol: reliability and validity. *Acta Orthop Traumatol Turc* 2016;50:69-75.
22. Ucuncu F, Capkin E, Karkucak M, Ozden G, Cakirbay H, Tosun M, et al. A comparison of the effectiveness of landmark-guided injections and ultrasonography guided injections for shoulder pain. *Clin J Pain* 2009;25:786-9.
23. Atik OŞ. Is there something new and interesting in my article? *Eklemler Hastalıkları Cerrahisi* 2019;30:69.
24. Cole BF, Peters KS, Hackett L, Murrell GA. Ultrasound-guided versus blind subacromial corticosteroid injections for subacromial impingement syndrome: a randomized, double-blind clinical trial. *Am J Sports Med* 2016;44:702-7.
25. Aly AR, Rajasekaran S, Ashworth N. Ultrasound-guided shoulder girdle injections are more accurate and more effective than landmark-guided injections: a systematic review and meta-analysis. *Br J Sports Med* 2015;49:1042-9.
26. Wu T, Song HX, Dong Y, Li JH. Ultrasound-guided versus blind subacromial-subdeltoid bursa injection in adults with shoulder pain: A systematic review and meta-analysis. *Semin Arthritis Rheum* 2015;45:374-8.
27. Rutten MJ, Maresch BJ, Jager GJ, de Waal Malefijt MC. Injection of the subacromial-subdeltoid bursa: blind or ultrasound-guided? *Acta Orthop* 2007;78:254-7.
28. Habib GS, Saliba W, Nashashibi M. Local effects of intra-articular corticosteroids. *Clin Rheumatol* 2010;29:347-56.
29. Senbursa G, Baltacı G, Atay A. Comparison of conservative treatment with and without manual physical therapy for patients with shoulder impingement syndrome: a prospective, randomized clinical trial. *Knee Surg Sports Traumatol Arthrosc* 2007;15:915-21.
30. Santamato A, Solfrizzi V, Panza F, Tondi G, Frisardi V, Leggin BG, et al. Short-term effects of high-intensity

- laser therapy versus ultrasound therapy in the treatment of people with subacromial impingement syndrome: a randomized clinical trial. *Phys Ther* 2009;89:643-52.
31. Pedowitz RA, Yamaguchi K, Ahmad CS, Burks RT, Flatow EL, Green A, et al. American Academy of Orthopaedic Surgeons Clinical Practice Guideline on: optimizing the management of rotator cuff problems. *J Bone Joint Surg [Am]* 2012;94:163-7.