



# Effect of the Bioadhesive, BioGlue, on Impaired Colonic Anastomose Healing in Rats

Yahya Ekici, Eda Yilmaz Akcay, Gokhan Moray

*General Surgery Department, Baskent University, Ankara, Turkey*

Colonic anastomotic leakage is still a problem in general surgery practice. We sought to investigate the effect of a new tissue adhesive, BioGlue, on the healing of normal and impaired colonic anastomoses. Sixty-four rats were randomized into 4 groups. In all animals, a 1-cm segment of the left colon was resected, and an end-to-end sutured anastomosis was created. Animals were then divided into 2 groups: normal and impaired anastomosis. These 2 groups were further subdivided into 2 additional groups: animals that received BioGlue and those that did not. All rats received intraperitoneal injections of either 0.9% NaCl or 5-fluorouracil (5-FU). Anastomotic evaluation was done 7 days after surgery. Macroscopic healing, mechanical strength, and histopathologic healing parameters were evaluated. Leakage of the anastomosis was significantly higher in rats in the impaired group compared with those in the BioGlue groups ( $P = 0.043$ ). The adhesion formation score was significantly higher in rats in the impaired anastomosis group compared with the other groups. Bursting pressures were significantly lower in the impaired anastomosis group than in the other ones ( $P = 0.001$ ). Neoangiogenesis and fibroblast activity were different among the groups ( $P = 0.001$ ). Inflammatory cell infiltration and collagen deposition did not differ among the groups ( $P = 0.07$ ). Immediate postoperative intraperitoneal administration of 5-FU after colonic anastomosis inhibits intestinal wound healing. Covering colon anastomoses with BioGlue after suturing conferred beneficial effect on healing.

*Key words:* Wound healing – Colon anastomosis – BioGlue – 5-Fluorouracil

Colonic resection and anastomoses are among the most frequently performed procedures in general surgery. Anastomotic dehiscence and subsequent leakage remain significant complications that can lead to death, sepsis, and the need for more surgery and a stoma.<sup>1–3</sup> Moreover, there are several short- and long-term sequelae associated with anastomotic dehiscence and leakage including im-

---

Corresponding author: Yahya Ekici, MD, Başkent Üniversitesi, Hastanesi poliklinik binası 5, Sokak No:48 Kat:1, Bahçelievler, 06490 Ankara, Turkey.

Tel.: 90 312 2152629; Fax: 90 312 2234909; E-mail: dryahyaekici@gmail.com

paired bowel function, anastomotic strictures, and decreased survival rates in patients with cancer.<sup>4</sup>

It is well known that administering antineoplastic drugs such as 5-fluorouracil (5-FU) immediately after surgery can adversely affect the healing process of colonic anastomoses.<sup>5-7</sup> Several techniques and devices, such as hand-sutured anastomoses and stapling devices, have been successfully used to make colonic anastomoses. Other experimental techniques that have been investigated for bowel anastomoses include sutureless biofragmentable rings, laser welding, and tissue adhesives. All of these techniques are designed to be safe and easy, even in the presence of impaired anastomosis healing.<sup>8-10</sup>

BioGlue (CryoLife International Inc, Kennesaw, Georgia) is a new bioadhesive that has been experimentally tested *in vitro* and *in vivo*.<sup>11-14</sup> It is commonly used in vascular, cardiopulmonary, urologic, and neurosurgical procedures.<sup>15-19</sup>

In this study, we investigate the effect of BioGlue on healing anastomosis of the colon in a rat model of experimentally impaired and normal colon anastomoses. To the best of our knowledge, this is the first study to evaluate the effects of this new adhesive in the healing of impaired anastomoses of the colon.

## Materials and Methods

The Research Board and Ethics Committee of Baskent University approved the study protocol. Sixty-four male Wistar albino rats weighing 260 to 350 g were used. The animals were acclimatized to their new surroundings for 1 week before the procedures. They were housed under 12-hour light-dark cycles in cages with no more than 3 animals per cage. They were fed standard rat chow and had access to food and water *ad libitum*.

The animals were separated into 4 groups: In the normal anastomosis group (Control), just a colonic resection and anastomosis were performed on the descending colon. In the normal anastomosis BioGlue group (Bio), BioGlue was applied to the anastomosis site after a colonic resection and anastomosis. The other 2 animal groups were treated similarly except for the creation of impaired anastomoses. These 2 groups were called the impaired anastomosis group (IM) and the impaired anastomosis plus BioGlue group (IM-Bio). All the animals were killed 7 days after surgery to investigate the healing of the anastomoses.

### *Anastomotic technique*

Animals were anesthetized with a combination of 5 mg/kg xylazine (Rompun, Bayer, Istanbul, Turkey) and 30 mg/kg ketamine hydrochloride (Ketalar, Parke-Davis, Istanbul, Turkey) administered intraperitoneally. Sterile instruments were used for surgery. After a 4-cm midline incision, the left colon was mobilized and a 5-mm segment of the colon was resected. The free ends of the colon were then anastomosed using interrupted, inverting 7-0 polypropylene sutures (Prolene, Ethicon, Kirkton, Scotland) 1 mm apart. In all the animals, after suturing the anastomosis, the fascia and the skin were closed separately with three 3-0 silk (Mersilk, Ethicon) sutures. All the operations were performed by the same surgeon.

After closing the midline incision, animals in the IM group received intraperitoneal 5-FU. From the day of the operation until the day they were killed, the animals in groups Control (C) and Bio received intraperitoneal injections of 3 mL normal saline once daily. The animals in the IM and IM-Bio groups received intraperitoneal injections of 5-FU at a dosage of 20 mg/kg body weight from the day of the operation until the day they were killed.

### *Application of BioGlue*

The BioGlue was prepared according to the manufacturer's directions. The BioGlue was applied to the suture line using the supplied rigid applicator tip, minimizing the exposure of the colon surface to the BioGlue. Before applying the glue, all tissues in the abdomen were protected with wet gauze. To ensure the circumferential application of the tissue adhesive, the colon was first rotated 90° counterclockwise and then 90° clockwise for posterior application. According to the manufacturer's instructions, to protect the tissue from the toxic effects of the BioGlue, the initial triggered material must be discarded because of the likelihood of increased glutaraldehyde release.

### *Assessment of anastomosis*

To assess the anastomoses, the animals in all groups were killed 7 days after surgery. For gross assessment, after relaparotomy, the abdomen and the anastomoses were evaluated for abscess and adhesion formation. Peritonitis was recorded as present or absent.

Adhesion formation was recorded in a blind manner according to the scale of van der Ham *et al* as follows: 0, no adhesions; 1, minimal adhesions

Table 1 Dehiscence of anastomose

Group	Number	Dehiscence	Percentage
C	16	1	6.2
IM	16	5	31.2
Bio	16	0	0
IM-Bio	16	0	0

Bio, anastomose + BioGlue; C, normal anastomose; IM, anastomose + 5-fluorouracil; IM-Bio, anastomose + 5-fluorouracil + BioGlue.

(*i.e.*, mainly between the omentum and the anastomotic site); 2, moderate adhesions (*i.e.*, between the omentum and the anastomotic site and between the site and a loop of small bowel or abdominal wall); and 3, severe and extensive adhesions (*i.e.*, between the anastomotic site and several loops of small bowel and the abdominal wall).<sup>20</sup> Abscess formation was recorded as present or absent.

Intestinal obstruction was recorded as being present when the diameter of the segment proximal to the anastomosis was 2 times the diameter of the segment distal to the anastomosis. A 4-cm segment of the colon including the anastomosis at the midportion was gently dissected free of the surrounding tissues. The tissues that adhered to the anastomosis too tightly were not pushed away. The lumen of the colon was cleaned of the fecal content by gentle flushing with saline and not pushed away.

To assess the mechanical strength of the anastomosis, a suture was placed to close 1 end of the excised segment. The free end of the colon was then catheterized with a polyurethane tube (2-mm outer diameter), and a stay suture was tied over to prevent the leakage of air. The other end of the catheter was connected to an infusion pump and to a mercury manometer through a Y tube. The colon segment was then placed in a container filled with normal saline, and air was pumped through at a rate of 5 mL/min. The reading at which the pressure declined suddenly or at which bubbles were seen was recorded as the bursting pressure. After measuring the bursting pressure, the colon segment was divided along its long axis. A 5-mm ring of tissue including the anastomosis was excised and was stored in 10% formaldehyde for later assessment of the histopathologic features.

For histopathologic assessment, the tissues that had been fixed in 10% formaldehyde were stained with hematoxylin and eosin and were evaluated at  $\times 20$  to  $\times 200$  magnification under the light microscope. The anastomoses were graded histologically in a blind fashion, using the 0 to 4 Ehrlich and Hunt

numeric scale as modified by Reddy *et al*.<sup>21</sup> and Phillips *et al*.<sup>22</sup> Inflammatory cell infiltration (white blood cell count), fibroblast activity, blood vessel neodevelopment (neovascularization), and collagen deposition were graded from 0 to 4 as follows: 0 = no evidence, 1 = occasional evidence, 2 = light scattering, 3 = abundant evidence, and 4 = confluent cells or fibers.

#### Statistical analysis

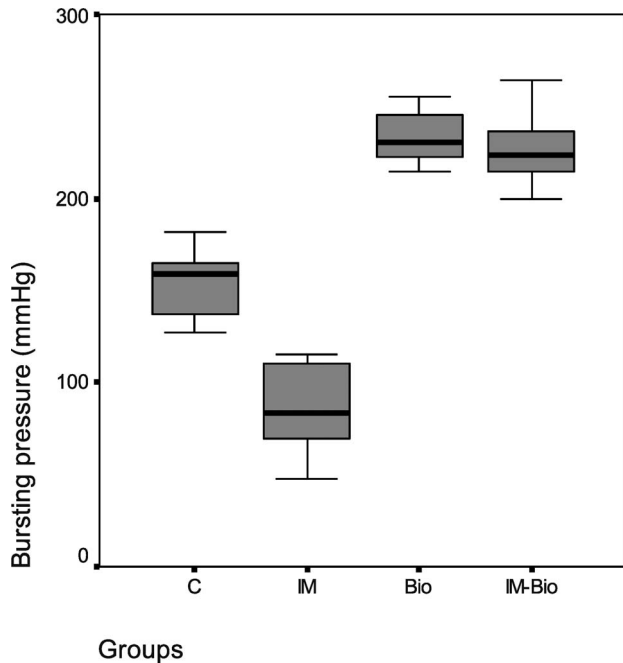
The results were analyzed by the  $\chi^2$  test and Kruskal-Wallis test, whereas pairwise differences were compared using the Mann-Whitney *U* test. A *P* value of less than 0.05 was accepted as statistically significant.

#### Results

All animals recovered from surgery. They were killed at a designated time, and there were no deaths during the experiment. One rat from the control group (6%) and 5 rats (31%) from the IM group developed anastomotic dehiscence. The leakage rates of the anastomosis differed significantly among the groups (Table 1). The dehiscence rate was significantly higher in the IM group compared with the Bio and IM-Bio groups, in which no dehiscence was observed ( $P = 0.043$  for both comparisons). The differences between the C group and no-dehiscence group were not statistically significant. Seven days after the surgery, a wound infection developed in 1 rat in the IM group, 1 rat in the IM-Bio group, and 1 rat in the Bio group ( $P = 0.496$ ). Intra-abdominal abscess was detected in 2 rats in the IM group ( $P = 0.103$ ).

The adhesion formation score was higher in the IM group (2.3) compared with the other groups ( $P = 0.014$ ). The difference was not statistically significant among the other groups.

The mean  $\pm$  SD bursting pressure values of groups C, IM, Bio, and IM-Bio were  $154.5 \pm 17.9$ ,  $85.8 \pm 22.9$ ,  $233.1 \pm 13$ , and  $226.4 \pm 15.4$  ( $P = 0.001$ ; Fig. 1), respectively. The bursting pressures of the colons in rats with anastomotic dehiscence were not added to the statistical calculation. The calculations for groups C and IM were done using the remaining 15 and 11 bursting pressure values, respectively. After a pairwise comparison using the Mann-Whitney *U* test, the mean colonic bursting pressure was found to be significantly lower in the IM group than in the other groups. Specifically, the bursting pressures were similar in the Bio and IM-Bio groups



**Fig. 1** Bursting pressure measurements of the anastomosis. C, normal anastomose; IM, anastomose + 5-fluorouracil; Bio, anastomose + BioGlue; IM-Bio, anastomose + 5-fluorouracil + Bioglue.

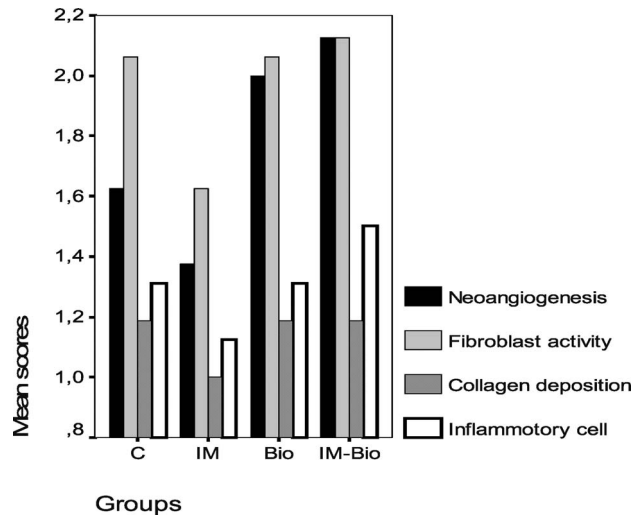
( $P = 0.7$ ). Control group bursting pressure was significantly different than Bio groups ( $P = 0.001$ ; Fig. 1).

The wound healing process was evaluated by neoangiogenesis, fibroblast activity, inflammatory cell infiltration, and collagen deposition scores (Fig. 2).

Neoangiogenesis and fibroblast activity scores were different among the groups (C: 1.6–2; IM: 1.3–1.6; Bio: 2–2.1; and IM-Bio: 2–2.1; respectively). The Bio and IM-Bio groups had markedly high angiogenesis and fibroblast activity compared with the other groups. Inflammatory cell infiltration and collagen deposition scores did not represent any significant difference among the groups (comparison of the groups  $P = 0.2$  and  $P = 0.4$ , respectively).

## Discussion

Leakage of colonic anastomoses is a potentially devastating surgical complication. Several factors including bowel preparation before surgery, surgical technique, nutritional status, and intervening pathological conditions have been identified as significant factors influencing the healing of colonic anastomoses. The prevalence of anastomotic leakage varies from 1% to 39%, but clinically significant leaks occur



**Fig. 2** Histologic evaluation of groups. C, normal anastomose; IM, anastomose + 5-fluorouracil; Bio, anastomose + BioGlue; IM-Bio, anastomose + 5-fluorouracil + Bioglue.

more accurately in 3% to 6% of patients depending on the definition and the type of the resection performed.<sup>23</sup> Anastomotic leakage may lead to increased morbidity, mortality, prolonged hospital stay, and extra cost. For these reasons, several types of glue have been used to secure an anastomosis.

BioGlue surgical adhesive is a mixture of purified bovine serum albumin (45%) and glutaraldehyde (10%) that is commonly used in vascular and cardiopulmonary repair surgery, tissue adherence, and strengthening<sup>16</sup> It is easy to prepare and apply and begins to bond within 20 to 30 seconds, reaching its maximum bonding capability in 2 to 3 minutes.<sup>16</sup>

It is well known that antimetabolites such as 5-FU impair colonic healing by reducing local accumulation of leucocytes, macrophages, and fibroblasts. Decreased leucocytes in the wound with reduced production of local cytokines and growth factors may lead to anastomotic failure. 5-FU administered immediately after an operation also has a negative impact on fibroblast proliferation and collagen synthesis, which can result in anastomotic leakage, decreased mechanical strength, and delayed anastomotic healing. According to the literature, the vast majority of previous studies have shown that the healing of colonic anastomosis has been impaired by the immediate postoperative intraperitoneal administration of 5-FU.<sup>24–26</sup> The dosage of 5-FU used in our study, which is based on the results of similar experimental studies,<sup>24</sup> has been shown to retard the healing of colon anastomosis.

The current study was in accordance with previous studies; we too found that early postoperative intraperitoneal 5-FU administration impaired the healing of colon anastomosis. Specifically, in the IM group, the anastomotic dehiscence rate was 31.5% and was significantly increased compared with the other groups. In addition, our study showed that covering the colon anastomoses with BioGlue after suturing prevented the anastomosis from leaking. Using BioGlue after suturing the anastomoses creates a physical barrier preventing the anastomosis from leaking during the early postoperative period.

Because the anastomoses leaked in the IM group, adhesion formation in this group also increased compared with the other ones. This finding has been observed in previous studies as well.<sup>5,7</sup> Intraperitoneal 5-FU administration changes the balance of the fibrinolytic system, which is one of the basic factors affecting the formation of peritoneal adhesions.<sup>27</sup> In addition, intra-abdominal infection causes abdominal inflammation, peritoneal damage, and disrupts fibrinolysis resulting in abdominal adhesions.<sup>28-30</sup> This study demonstrates that covering colon anastomoses with BioGlue prevents anastomosis leakage; however, BioGlue does not have a significant effect on adhesion formation.

To evaluate the strength of colon anastomoses in the early wound healing period, we measured the bursting pressures. The bursting pressures of the anastomoses in the rats of the IM group were significantly lower than those in the other groups. Furthermore, applying BioGlue to a normal anastomosis increased the anastomotic bursting pressure. It seems that covering the anastomosis with BioGlue prevented anastomotic dehiscence and strengthened it. There was no clear evidence about the toxic effect of glutaraldehyde contained in the glue on anastomoses.

Inflammation plays an important role in the wound healing process. This process was assessed by neoangiogenesis, fibroblast proliferation, inflammatory cell infiltration, and collagen deposition. In this study, histologic evaluation of the colonic anastomoses showed a marked failure in healing in the IM group compared with the other groups as demonstrated by the fact that neoangiogenesis and fibroblast proliferation were significantly retarded. Formaldehyde used in high concentrations (37%) in the gelatin-resorcinol-formaldehyde glue seems to have a toxic effect on the vascular wall.<sup>31,32</sup> BioGlue is a surgical adhesive that contains only 10% glutaraldehyde. The results of various investigations have shown the toxic potential of BioGlue on

different tissue types.<sup>33-36</sup> The toxic effect of the BioGlue on phrenic nerve and on cardiac conduction tissues has been reported.<sup>37</sup> The toxicity of BioGlue increases when the glue is in contact with incisional tissue surfaces, especially those of the lung and the liver; however, this effect decreases when the glue is administered to the outer layer and vascular tissues. The structure of vascular tissue is different from that of lung and liver tissues.<sup>13</sup> The glue is used for tissue apposition and may be used superficially rather than for primary closure. Long-term follow-up of the glue's use in aortic tissues has shown that it causes severe active inflammation and massive foreign body reaction.<sup>38</sup>

No long-term follow-up data on the effect of BioGlue on colonic tissues are available. No foreign body giant cells or glaucomatous tissues were found in our study during early healing of the wound. In the late phase of healing, however, it may be detrimental, probably due to the ongoing inflammatory reaction.

In conclusion, early postoperative intraperitoneal administration of 5-FU retards the healing of colon anastomoses. Covering anastomoses with BioGlue prevents the anastomoses from leaking and the adverse effects of 5-FU. BioGlue is advantageous in the experimentally normal and impaired colonic anastomoses according to this study. Further investigations are needed to evaluate the early and late effects of BioGlue on colonic anastomotic healing in experimental settings and in clinical practice.

## References

1. Alves A, Panis Y, Pocard M, Regimbeau JM, Valleur P. Management of anastomotic leakage after nondiverted large bowel resection. *J Am Coll Surg* 1999;**189**(6):554-559
2. Soeters PB, de Zoete JP, Dejong CH, Williams NS, Baeten CG. Colorectal surgery and anastomotic leakage. *Dig Surg* 2002;**19**(2):150-155
3. Platell C, Papadimitriou JM, Hall JC. The influence of lavage on peritonitis. *J Am Coll Surg* 2000;**191**(6):672-680
4. Walker KG, Bell SW, Rickard MJ, Mehanna D, Dent OF, Chapuis PH. Anastomotic leakage is predictive of diminished survival after potentially curative resection for colorectal cancer. *Ann Surg* 2004;**240**(2):255-259
5. Kanellos I, Kavouni A, Zaraboukas T, Odisseos C, Galovatsea K, Dadoukis I. Influence of intraperitoneal 5-fluorouracil plus folinic acid on the healing of colonic anastomoses in rats. *Eur Surg Res* 1996;**28**(5):374-379
6. Weiber S, Graf W, Glimelius B, Jiborn H, Pählman L, Zederfeldt B. The effect of 5-fluorouracil on wound healing

- and collagen synthesis in left colon anastomoses. An experimental study in the rat. *Eur Surg Res* 1994;**26**(3):173–178
7. Kanellos I, Odisseos C, Zaraboukas T, Kavouni A, Galovatsea K, Dadoukis I. Colonic healing after early intraperitoneal administration of 5-fluorouracil and interferon in rats. *Int J Colorectal Dis* 1997;**12**(1):45–48
  8. Corman ML, Prager ED, Hardy TG Jr, Bubrick MP. Comparison of the Valtrac biofragmentable anastomosis ring with conventional suture and stapled anastomosis in colon surgery. Results of a prospective, randomized clinical trial. *Dis Colon Rectum* 1989;**32**(3):183–187
  9. Friend PJ, Scott R, Everett WG, Scott IH. Stapling or suturing for anastomoses of the left side of the large intestine. *Surg Gynecol Obstet* 1990;**171**(5):373–376
  10. Curley SA, Allison DC, Smith DE, Doberneck RC. Analysis of techniques and results in 347 consecutive colon anastomoses. *Am J Surg* 1988;**155**(4):597–601
  11. Hruby G, Marruffo F, Durak E, Collins S, Herron A, Landman J. Comparison of BioGlue reinforced and standard running sutured vesicourethral anastomoses. *Urology* 2006;**68**(6):1355–1359
  12. Van Belleghem Y, Forsyth RG, Narine K, Moerman A, Taeymans Y, Van Nooten GJ. Bovine glue (BioGlue) is catabolized by enzymatic reaction in the vascular dog model. *Ann Thorac Surg* 2004;**77**(6):2177–2181; discussion 2181
  13. Fürst W, Banerjee A. Release of glutaraldehyde from an albumin-glutaraldehyde tissue adhesive causes significant in vitro and in vivo toxicity. *Ann Thorac Surg* 2005;**79**(5):1522–1528; discussion 1529
  14. Stylli SS, Kumar A, Gonzales M, Kaye AH. The biocompatibility of BioGlue with the cerebral cortex: a pilot study. *J Clin Neurosci* 2004;**11**(6):631–635
  15. Raanani E, Latter DA, Errett LE, Bonneau DB, Leclerc Y, Salasidis GC. Use of “BioGlue” in aortic surgical repair. *Ann Thorac Surg* 2001;**72**(2):638–640
  16. Coselli JS, Bavaria JE, Fehrenbacher J, Stowe CL, Macheers SK, Gundry SR. Prospective randomized study of a protein-based tissue adhesive used as a hemostatic and structural adjunct in cardiac and vascular anastomotic repair procedures. *J Am Coll Surg* 2003;**197**(2):243–252; discussion 252–253
  17. Tansley P, Al-Mulhim F, Lim E, Ladas G, Goldstraw P. A prospective, randomized, controlled trial of the effectiveness of BioGlue in treating alveolar air leaks. *J Thorac Cardiovasc Surg* 2006;**132**(1):105–112
  18. Passage J, Tam R, Windsor M, O'Brien M. Bioglue: a review of the use of this new surgical adhesive in thoracic surgery. *ANZ J Surg* 2005;**75**(5):315–318
  19. Hidas G, Kastin A, Mullerad M, Shental J, Moskovitz B, Nativ O. Sutureless nephron-sparing surgery: use of albumin glutaraldehyde tissue adhesive (BioGlue). *Urology* 2006;**67**(4):697–700; discussion 700
  20. van der Ham AC, Kort WJ, Weijma IM, van den Ingh HF, Jeekel H. Effect of antibiotics in fibrin sealant on healing colonic anastomoses in the rat. *Br J Surg* 1992;**79**(6):525–528
  21. Reddy GK, Enwemeka CS. A simplified method for the analysis of hydroxyproline in biological tissues. *Clin Biochem* 1996;**29**(3):225–229
  22. Phillips JD, Kim CS, Fonkalsrud EW, Zeng H, Dindar H. Effects of chronic corticosteroids and vitamin A on the healing of intestinal anastomoses. *Am J Surg* 1992;**163**(1):71–77
  23. Chambers WM, Mortensen NJ. Postoperative leakage and abscess formation after colorectal surgery. *Best Pract Res Clin Gastroenterol* 2004;**18**(5):865–880
  24. Kanellos I, Kavouni A, Zaraboukas T, Odisseos C, Galovatsea K, Dadoukis I. Influence of intraperitoneal 5-fluorouracil plus folinic acid on the healing of colonic anastomoses in rats. *Eur Surg Res* 1996;**28**(5):374–379
  25. Kanellos I, Kazantzidou D, Evangelou I, Galovatsea K, Zaraboukas T, Dadoukis I. Healing of colonic anastomoses after immediate and delayed administration of 5-fluorouracil plus folinic acid. *Eur Surg Res* 1998;**30**:312–317
  26. Hillan K, Nordlinger B, Ballet F, Puts JP, Infante R. The healing of colonic anastomoses after early intraperitoneal chemotherapy: an experimental study in rats. *J Surg Res* 1988;**44**(2):166–171
  27. el-Malt M, Ceelen W, Van den Broecke C, Cuvelier C, Van Belle S, de Hemptinne B. Influence of neo-adjuvant chemotherapy with 5-fluorouracil on colonic anastomotic healing: experimental study in rats. *Acta Chir Belg* 2003;**103**(3):309–314
  28. Kucukozkan T, Ersoy B, Uygur D, Gundogdu C. Prevention of adhesions by sodium chromoglycate, dexamethasone, saline and aprotinin after pelvic surgery. *ANZ J Surg* 2004;**74**(12):1111–1115
  29. van Goor H, de Graaf JS, Grond J, Sluiter WJ, van der Meer J, Bom VJ. Fibrinolytic activity in the abdominal cavity of rats with faecal peritonitis. *Br J Surg* 1994;**81**(7):1046–1049
  30. van Goor H, Bom VJ, van der Meer J, Sluiter WJ, Bleichrodt RP. Coagulation and fibrinolytic responses of human peritoneal fluid and plasma to bacterial peritonitis. *Br J Surg* 1996;**83**(8):1133–1135
  31. Jahnsen S, Graf W, Rikner G, Gerdin B. Anastomotic breaking strength and healing of anastomoses in rat intestine with and without chronic radiation damage. *Eur J Surg* 1995;**161**(6):425–430
  32. Kiyama T, Tajiri T, Tokunaga A, Yoshiyuki T, Barbul A. Tacrolimus enhances colon anastomotic healing in rats. *Wound Repair Regen* 2002;**10**(5):308–313
  33. Kazui T, Washiyama N, Bashar AH, Terada H, Suzuki K, Yamashita K. Role of biologic glue repair of proximal aortic dissection in the development of early and midterm

- redissection of the aortic root. *Ann Thorac Surg* 2001;**72**(2): 509–514
34. LeMaire SA, Schmittling ZC, Coselli JS, Undar A, Deady BA, Clubb FJ Jr. BioGlue surgical adhesive impairs aortic growth and causes anastomotic strictures. *Ann Thorac Surg* 2002;**73**(5): 1500–1505; discussion 1506
35. Erasmi AW, Sievers HH, Wolschläger C. Inflammatory response after BioGlue application. *Ann Thorac Surg* 2002; **73**(3):1025–1026
36. Downing SW. What are the risks of using biologic glues? *Ann Thorac Surg* 2003;**75**(3):1063; author reply 1063–1064
37. Lemaire SA, Ochoa LN, Conklin LD, Schmittling ZC, Undar A, Clubb FJ Jr. Nerve and conduction tissue injury caused by contact with BioGlue. *J Surg Res* 2007;**143**(2):286–293
38. Erasmi AW, Sievers HH, Wolschläger C. Inflammatory response after BioGlue application. *Ann Thorac Surg* 2002; **73**(3):1025–1026