



Inflammatory Myofibroblastic Tumor of the Prostate

Prostatın İnflamatuar Myofibroblastik Tümörü

Inflammatory Myofibroblastic Tumor

Nazım Emrah Koçer¹, Nebil Bal¹, Ümit Gül², Hakan Aydın³

¹Başkent Üniversitesi Adana Uygulama ve Araştırma Merkezi Patoloji bölümü, Adana,

²Başkent Üniversitesi Adana Uygulama ve Araştırma Merkezi Üroloji bölümü, Adana,

³Başkent Üniversitesi Ankara Uygulama ve Araştırma Merkezi Patoloji bölümü, Ankara, Türkiye

Olgu sunumu 17. Ulusal Patoloji Kongresi, 8-13 Eylül 2007 İstanbul'da yazılı poster olarak sunulmuştur

Özet

Prostatın inflamatuvar myofibroblastik tümörleri (İMT), sarkomlar ve iğsi hücreli karsinomları klinik ve histopatolojik olarak taklit edebilen nadir lezyonlardır. Burada sunulan olgu, normal prostat spesifik antijen düzeyleri ve kronik yakınmaları olan, tıbbi tedaviye yanıtız infravezikal tıkanma bulguları nedeni ile suprapubik prostatektomi uygulanan 63 yaşında bir hastadır. Eksizyon materyalinin histopatolojik incelenmesi fokal nükleer pleomorfizm, hiperkromazi gösteren, mononükleer iltihabi infiltrasyon ve miksoid değişiklikler içeren, düzgün sınırlı, iğsi hücreli bir lezyonu ortaya koydu. Mitoz nadirdi. İmmunohistokimyasal çalışmada düz kas aktini ve vimentin pozitif, anaplastik lenfoma kinaz -1 fokal pozitif, S-100 ve pansitokeratin negatif. Lezyon inflamatuvar myofibroblastik tumor olarak tanı aldı. İMT'nin prostatın malign iğsi hücreli lezyonlarından ayrımı gereksiz ileri tedavi işlemlerinin önüne geçilmesi için şarttır.

Anahtar Kelimeler

İnflamatuar Myofibroblastik Tümör; Prostat; Psödosarkomatöz; Fibromiksoid; Psödötümör

Abstract

Inflammatory myofibroblastic tumors (IMT) of the prostate are very rare lesions that may mimic sarcomas and spindle carcinomas both clinically and histopathologically. The case presented here is a 63-year-old patient, with normal prostate specific antigen levels and a chronic history of complaints, who underwent to suprapubic prostatectomy due to the infravesical obstruction symptoms that are resistant to medical therapy. Histopathological examination of the excision material revealed a well demarcated spindle cell lesion with focal nuclear polymorphism, hyperchromasia, mononuclear inflammatory infiltration and myxoid areas. Mitosis was rare. Immunohistochemically smooth muscle actin and vimentin were positive, anaplastic lymphoma kinase-1 was focal positive, S-100 and pancytokeratin were negative. The lesion was diagnosed as an inflammatory pseudotumor. Differential diagnosis of the IMT from malignant spindle cell tumors of the prostate is crucial to prevent overtreatment.

Keywords

Inflammatory Myofibroblastic Tumor; Prostate; Pseudosarcomatous; Fibromyxoid; Pseudotumor

DOI: 10.4328/JCAM.1759

Received: 25.03.2013 Accepted: 24.04.2013 Printed: 01.04.2016 J Clin Anal Med 2016;7(suppl 2): 124-6

Corresponding Author: Nazım Emrah Koçer, Başkent Üniversitesi Adana Uygulama ve Araştırma Merkezi Patoloji bölümü, Dadaloglu Mah. 39 Sok. No:6 01250, Yüreğir, Adana, Türkiye. T.: +905052730578 F.: +90 3223271276 E-Mail: nemrahkocer@yahoo.com

Introduction

Stromal lesions of the prostate are rare and consisted of a number of benign and malignant lesions that closely resemble each other [1,2]. The differential diagnosis, which is crucial for appropriate treatment, may be challenging. Inflammatory myofibroblastic tumor of the prostate (IMT; synonym: pseudosarcomatous spectrum fibromyxoid tumor of the prostate, inflammatory pseudotumor of the prostate) is one of these rare lesions and stands in the benign side of the stromal lesions.

Case Report

A 63-year-old male patient has admitted to the department of urology with difficulty in starting urine flow and pollakiuria for 2 years. Despite the 6 months of 5 alpha reductase (Finasterid 5mg) and alpha blocker (Tamsulosin HCL 0.4mg) medication, the symptoms persisted. Prostate specific antigen (PSA) was 1.22 ng/ml, and prostate volume was measured as 186cc in ultrasound. In urethrocystoscopy prostatic urethra was longer than normal (7cm) and prostate median lobe and lateral lobes were narrowing the urethra. Qmax, volume and residue in uroflow, performed without Foley catheter, were 12ml/sec, 75cc and 197 cc respectively. Bladder capacity, compliance, and sensitivity were normal in filling cystometry. There was no detrusor hyperactivity. Pressure flow study showed high pressure-low flow. Digital rectal examination finding was compatible with a 1.5(+) adenoma.

The patient had no history of a previous operation or instrumentation.

Since the patient was not an appropriate candidate for transurethral resection, suprapubic prostatectomy was performed with a clinical presumptive diagnosis of benign prostatic hyperplasia.

Macroscopically the resection material was composed of two separate tissues (originally a single mass resected in two portions by the surgeon because of its size) with smooth surface, gray-white in color. One of the pieces was 9x4x4cm and the other was 7x5x4cm, total weight: 141gr. The cut surfaces were solid, gray-white in color and had a fibrillary appearance. Extensive sampling was done.

Microscopically the well demarcated lesion that was composed of spindle cells forming long, transecting bundles, was pushing, but not infiltrating the normal prostate tissue. Focal nuclear hyperchromasia and pleomorphism were observed. Mitosis was rare. There was no necrosis or atypical mitotic figures. There were foci of mononuclear inflammatory response, including plasma cells, and myxoid degeneration (Figure 1). Vimentin, smooth muscle actin were positive, anaplastic lymphoma kinase -1 (ALK-1) was focal positive, S-100 and pancytokeratin were negative in immunohistochemical study. ALK positivity was confirmed with fleurocein in-situ hybridization (FISH) with DAKO split signal FISH probe (Figure 2).

The case was diagnosed as inflammatory myofibroblastic tumor. The patient is under follow up, for 5 years and no recurrence occurred.

Discussion

Inflammatory myofibroblastic tumors are rare lesions that can be seen in a variety of organs (e.g. lungs, heart, liver, vagina,

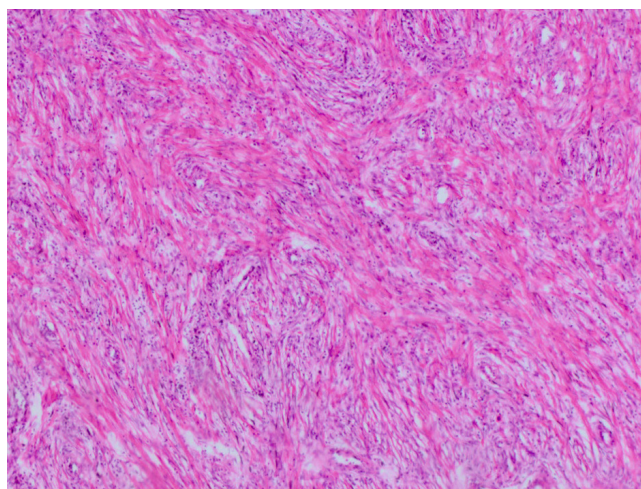


Figure 1. Photomicrograph reveals transecting spindle cell bundles intermixed with mononuclear inflammatory infiltrate (HE x100)

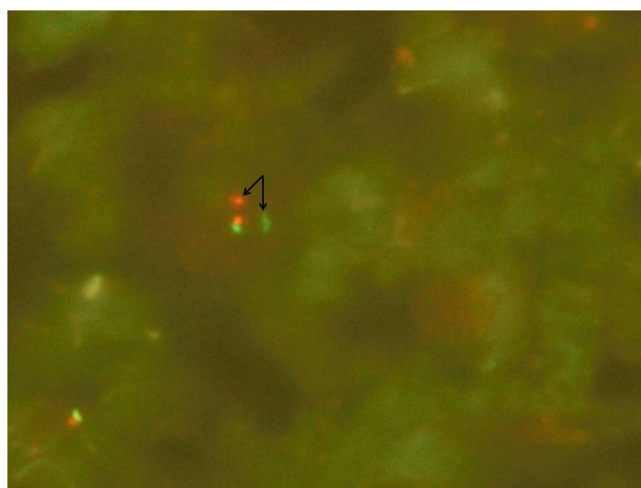


Figure 2. Signal splitting in FISH. Note one green and one red signal splitted from each other by a distance more than two signal diameters (arrows) (ALK FISH x1000)

kidneys) [2, 3]. The etiopathogenesis is uncertain. The term “inflammatory pseudotumor” was first used by Umiker and Ivenson in 1954 for describing 4 cases in lung [2]. Compared with the respiratory system the term “inflammatory pseudotumor” is relatively new in genitourinary tract. First “reactive pseudosarcomatous response” in genitourinary tract was described in bladder in 1980 [4], and the first IMT in prostate was described 4 years later by Hafiz et al [5].

IMTs are spindle cell lesions that are believed to be originate from the myofibroblastic cells [6]. They may mimic malignant lesions both clinically and microscopically. In clinic, IMTs may show rapid grow and high PSA levels. Microscopically they may be confused with sarcomas and spindled carcinomas, which will lead to cystoprostatectomy and pelvic lymph node dissection. In our case the PSA levels were not suggestive of malignancy and the clinical symptoms of the patient were existing nearly for two years, without a rapid increase. The size of our lesion is larger than the previously reported IMTs of prostate [1, 7]. This slow pace of growth may explain the relatively larger size of the lesion. If the lesion showed rapid growth and caused more dramatic symptoms, the patient would have admitted to the hospital earlier and probably the lesion would be excised in an earlier phase. In microscopic examination there was focal nuclear pleomorphism and hyperchromasia. Mitosis was rare

and necrosis was absent. In sarcomas and spindle carcinomas, nuclear pleomorphism and hyperchromasia are more prominent with a high mitotic rate and invasive pattern. Foci of necrosis may also be present.

Postoperative spindle cell nodule (PSCN), and IMT were thought to be different entities, but now they are believed to be reflecting the same lesion with some minor differences, particularly in patient history. PSCN develops after an instrumentation or operation, and tends to be smaller than IMT [1, 6]. Our patient had no history of a previous operation or instrumentation.

Embryonal, fibroblastic, and smooth muscle nodules are the stromal nodules of benign prostatic hyperplasia (BPH) [1]. They are all well demarcated nodules and may contain pleomorphic spindle cells and hyperchromatic pleomorphic nuclei [8], like IMT. All BPH nodules are positive for S-100 [1]. In our case S-100 was negative. Although one may speculate that it may be possible that some IMT nodules were being reported as BPH nodules in the past, and the real incidence of IMT may be higher than the current data, after nearly 30 years of its first description, there is still a small number of case reports in the literature regarding prostatic IMTs.

Immunohistochemical ALK-1 positivity may be seen in genitourinary tract, most commonly in bladder, IMTs. In a study by Montgomery et al, FISH ALK results and immunohistochemical ALK results were showed to be compatible [7]. The ALK positivity suggests that IMTs of genitourinary tract are true neoplastic processes rather than reactive ones. ALK positivity may not be a predictor of recurrence [7].

IMTs of prostate are rare lesions and their distinction from sarcomas and spindle cell carcinomas is crucial to prevent an overtreatment. Most IMTs of prostate are treated with transurethral resection, an interventional therapy that aims to resolve the symptoms rather than a total resection of the mass. Since IMTs are true neoplastic processes, close follow up of the patients with IMT diagnosis may be important.

Competing interests

The authors declare that they have no competing interests.

References

1. Hulpap B. Non-epithelial tumor-like lesions of the prostate: a never ending diagnostic problem. *Virchows Arch* 2002;441(3):231-7.
2. Patnana M, Sevrakov AB, Elsayes KM, Viswanathan C, Lubner M, Menias CO. Inflammatory pseudotumor: the great mimicker. *Am J Roentgenol* 2012;198(3):W217-27 doi: 10.2214/AJR.11.7288.
3. Atis G, Gurbuz C, Kiremit MC, Guner B, Zemheri E, Caskurlu T. Pseudosarcomatous fibromyxoid tumor of the prostate. *ScientificWorldJournal* 2011;11:1027-30. doi: 10.1100/tsw.2011.87.
4. Roth JA. Reactive pseudosarcomatous response in urinary bladder. *Urology* 1980;16(6):635-7.
5. Hafiz MA, Toker C, Sutula M. An atypical fibromyxoid tumor of the prostate. *Cancer* 1984;54(11):2500-4.
6. Bjerregaard JJ, Langkilde NC, Lundbeck F, Marcussen N. Pseudosarcomatous fibromyxoid tumor of the prostate. *Scand J Urol Nephrol* 2003;37(1):85-87.
7. Montgomery EA, Shuster DD, Burkhart AL, Esteban JM, Signigroli A, Elwood L, et al. Inflammatory myofibroblastic tumors of the urinary tract: A clinicopathologic study of 46 cases, including a malignant example of inflammatory fibrosarcoma and a subset associated with high-grade urothelial carcinoma. *Am J Surg Pathol* 2006; 30(12):1502-12.
8. Young RH, Scrigley JR, Amin MD, Ulbright TH, Cubilla. Tumors of the prostate gland, seminal vesicles, male urethra, and penis. *Atlas of Tumor Pathology, Fascicle 28*. AFIP Washington; 2000. p.257.

How to cite this article:

Koçer NE, Bal N, Gül Ü, Aydın H. Inflammatory Myofibroblastic Tumor of the Prostate. *J Clin Anal Med* 2016;7(suppl 2): 124-6.