



Consensus and Diversity in the Management of Varicocele for Male Infertility: Results of a Global Practice Survey and Comparison with Guidelines and Recommendations

Rupin Shah¹, Ashok Agarwal², Parviz Kavoussi³, Amarnath Rambhatla⁴, Ramadan Saleh⁵, Rossella Cannarella⁶, Ahmed M. Harraz^{7,8,9}, Florence Boitrelle^{10,11}, Shinnosuke Kuroda², Taha Abo-Elmagd Abdel-Meguid Hamoda^{12,13}, Armand Zini¹⁴, Edmund Ko¹⁵, Gokhan Calik¹⁶, Tuncay Toprak¹⁷, Hussein Kandil¹⁸, Murat Gül¹⁹, Mustafa Emre Bakırcıoğlu²⁰, Neel Parekh²¹, Giorgio Ivan Russo²², Nicholas Tadros²³, Ates Kadioglu²⁴, Mohamed Arafa^{2,25,26}, Eric Chung²⁷, Osvaldo Rajmil²⁸, Fotios Dimitriadis²⁹, Vineet Malhotra³⁰, Gianmaria Salvio³¹, Ralf Henkel^{32,33}, Tan V. Le^{34,35}, Emrullah Sogutdelen³⁶, Sarah Vij²¹, Abdullah Alarbid⁸, Ahmet Gudeloglu³⁷, Akira Tsujimura³⁸, Aldo E. Calogero⁶, Amr El Meliegy³⁹, Andrea Crafa⁶, Arif Kalkanli⁴⁰, Aykut Baser⁴¹, Berk Hazir⁴², Carlo Giuliani⁴³, Chak-Lam Cho⁴⁴, Christopher C.K. Ho⁴⁵, Ciro Salzano⁴⁶, Daniel Suslik Zylbersztejn⁴⁷, Dung Mai Ba Tien³⁴, Edoardo Pescatori⁴⁸, Edson Borges⁴⁹, Ege Can Serefoglu⁵⁰, Emine Saïs-Hamza^{10,11}, Eric Huyghe⁵¹, Erman Ceyhan⁵², Ettore Caroppo⁵³, Fabrizio Castiglioni⁵⁴, Fahmi Bahar⁵⁵, Fatih Gokalp⁵⁶, Francesco Lombardo⁵⁷, Franco Gadda⁵⁸, Gede Wiry Kusuma Duarsa⁵⁹, Germar-Michael Pinggera⁶⁰, Gian Maria Busetto⁶¹, Giancarlo Balercia³¹, Gianmartin Cito⁶², Gideon Blecher^{63,64}, Giorgio Franco⁶⁵, Giovanni Liguori⁶⁶, Haitham Elbardisi^{25,67}, Hakan Keskin³⁷, Haocheng Lin⁶⁸, Hisanori Taniguchi⁶⁹, Hyun Jun Park^{70,71}, Imad Ziouziou⁷², Jean de la Rosette⁷³, Jim Hotaling⁷⁴, Jonathan Ramsay⁷⁵, Juan Manuel Corral Molina⁷⁶, Ka Lun Lo⁷⁷, Kadir Bocu⁷⁸, Kareim Khalafalla^{25,79}, Kasonde Bowe⁸⁰, Keisuke Okada⁸¹, Koichi Nagao⁸², Koji Chiba⁸¹, Lukman Hakim⁸³, Konstantinos Makarounis⁸⁴, Marah Hehemann⁸⁵, Marcelo Rodriguez Peña⁸⁶, Marco Falcone⁸⁷, Marion Bendayan^{10,11}, Marlon Martinez⁸⁸, Massimiliano Timpano⁸⁷, Mesut Altan⁸⁹, Mikkel Fode^{90,91}, Mohamed S. Al-Marhoon⁹², Mohammad Ali Sadighi Gilani⁹³, Mohammad Ayodhia Soebadi⁹⁴, Nazim Gherabi⁹⁵, Nikolaos Sofikitis⁹⁶, Oğuzhan Kahraman⁵², Ponco Birowo⁹⁷, Priyank Kothari⁹⁸, Puneet Sindhvani⁹⁹, Qaisar Javed¹⁰⁰, Rafael F. Ambar^{101,102}, Raghavender Kosgi¹⁰³, Ramy Abou Ghayda¹⁰⁴, Ricky Adriansjah¹⁰⁵, Rosita Angela Condorelli⁶, Sandro La Vignera⁶, Sava Micic¹⁰⁶, Shannon Hee Kyung Kim^{107,108}, Shinichiro Fukuhara¹⁰⁹, Sun Tae Ahn¹¹⁰, Taymour Mostafa³⁹, Teng Aik Ong¹¹¹, Teppei Takeshima¹¹², Toshiyasu Amano¹¹³, Trenton Barrett¹¹⁴, Umut Arslan¹⁷, Vilvpathy Senguttuvan Karthikeyan¹¹⁵, Widi Atmoko¹⁰³, Yasushi Yumura¹¹², Yiming Yuan¹¹⁶, Yuki Kato¹¹⁷, Davor Jezek¹¹⁸, Bryan Kwun-Chung Cheng¹¹⁹, Georgios Hatzichristodoulou¹²⁰, Jun Dy¹²¹, Eduard Ruiz Castañé¹²², Ahmed I. El-Sakka¹²³

Received: Mar 8, 2022 **Revised:** Mar 15, 2022 **Accepted:** Mar 20, 2022 **Published online** Jun 13, 2022

Correspondence to: Ashok Agarwal <https://orcid.org/0000-0003-0585-1026>

Andrology Center and American Center for Reproductive Medicine, Cleveland Clinic, Mail Code X-11, 10681 Carnegie Avenue, Cleveland, OH 44195, USA.

Tel: +1-216-444-9485. **Fax:** +1-216-445-6049. **E-mail:** agarwaa@ccf.org. **Website:** www.Clevelandclinic.org/ReproductiveResearchCenter

Quang Nguyen^{124,125}, Selcuk Sarikaya¹²⁶, Luca Boeri⁵⁸, Ronny Tan^{127,128}, Mohamad A. Moussa^{129,130}, Ahmed El-Assmy⁷, Hamed Alali¹³¹, Naif Alhathal¹³², Yasser Osman⁷, Dragoljub Perovic¹³³, Hesamoddin Sajadi⁹⁸, Hamed Akhavadegan¹³⁴, Miroslav Vučinić¹³⁵, Said Kattan¹³², Mohamed S. Kattan¹³², Nasser Mogharabian¹³⁶, Nguyen Ho Vinh Phuoc³⁴, Kay Seong Ngoo¹³⁷, Mohammad H. Alkandari¹³⁸, Shaheed Alsuhailani¹³⁹, Ioannis Sokolakis¹²⁰, Mehdi Babaei¹⁴⁰, Mak Siu King⁷⁷, Thorsten Diemer¹⁴¹, Marcelo M. Gava^{101,102}, Raphael Henrique¹⁴², Rodrigo Spinola e Silva^{101,102}, Gustavo Marquesine Paul¹⁴³, Tiago Cesar Mierzwa¹⁴⁴, Sidney Glina¹⁰¹, Kashif Siddiqi¹⁴⁵, Han Wu¹⁴⁶, Jana Wurzacher¹⁴⁷, Ala'a Farkouh², Hwancheol Son¹⁴⁸, Suks Minhas¹⁴⁹, Joe Lee¹⁵⁰, Nikko Magsanoc¹⁵¹, Paolo Capogrosso¹⁵², German Jose Albano⁸⁸, Sheena E. M. Lewis¹⁵³, Channa N. Jayasena^{154,155}, Juan G. Alvarez¹⁵⁶, Colin Teo¹⁵⁷, Ryan P. Smith¹⁵⁸, Jo Ben M. Chua¹⁵⁹, Christian Fuglesang S. Jensen¹⁶⁰, Sijo Parekattil¹⁶¹, Renata Finelli², Damayanthi Durairajanayagam¹⁶², Keshab Kumar Karna², Abdelkareem Ahmed⁹, Don Evenson¹⁶³, Yukihiko Umemoto¹⁶⁴, Ana Puigvert¹⁶⁵, Gökhan Çeker^{166,167}, Giovanni M Colpi¹⁶⁸, and on behalf of the Global Andrology Forum*

¹Division of Andrology, Department of Urology, Lilavati Hospital and Research Centre, Mumbai, India, ²American Center for Reproductive Medicine, Cleveland Clinic, Cleveland, OH, USA, ³Austin Fertility & Reproductive Medicine/Westlake IVF, TX, USA, ⁴Department of Urology, Vattikuti Urology Institute, Henry Ford Health System, Detroit, MI, USA, ⁵Department of Dermatology, Venereology and Andrology, Faculty of Medicine, Sohag University, Sohag, Egypt, ⁶Department of Clinical and Experimental Medicine, University of Catania, Catania, Italy, ⁷Mansoura University Urology and Nephrology Center, Mansoura, Egypt, ⁸Department of Surgery, Urology Unit, Farwaniya Hospital, Farwaniya, Kuwait, ⁹Department of Urology, Sabah Al Ahmad Urology Center, Kuwait City, Kuwait, ¹⁰Department of Reproductive Biology, Fertility Preservation, Andrology, CECOS, Poissy Hospital, Poissy, France, ¹¹Department of Biology, Reproduction, Epigenetics, Environment and Development, Paris Saclay University, UVSQ, INRAE, BREED, Jouy-en-Josas, France, ¹²Department of Urology, King Abdulaziz University, Jeddah, Saudi Arabia, ¹³Department of Urology, Faculty of Medicine, Minia University, Minia, Egypt, ¹⁴Division of Urology, Department of Surgery, McGill University, Montreal, QC, Canada, ¹⁵Department of Urology, Loma Linda University Health, Loma Linda, CA, USA, ¹⁶Department of Urology, Faculty of Medicine, Istanbul Medipol University, Istanbul, Turkey, ¹⁷Department of Urology, Fatih Sultan Mehmet Training and Research Hospital, University of Health Sciences, Istanbul, Turkey, ¹⁸Fakih IVF Fertility Center, Abu Dhabi, UAE, ¹⁹Department of Urology, Selcuk University School of Medicine, Konya, Turkey, ²⁰SENSART Clinic, Istanbul, Turkey, ²¹Department of Urology, Glickman Urological and Kidney Institute, Cleveland Clinic, Cleveland, OH, USA, ²²Urology Section, University of Catania, Catania, Italy, ²³Division of Urology, Southern Illinois University School of Medicine, Springfield, IL, USA, ²⁴Section of Andrology, Department of Urology, Istanbul University, Istanbul Faculty of Medicine, Istanbul, Turkey, ²⁵Department of Urology, Hamad Medical Corporation, Doha, Qatar, ²⁶Department of Urology, Weill Cornell Medical-Qatar, Doha, Qatar, ²⁷Department of Urology, Princess Alexandra Hospital, University of Queensland, Brisbane, Australia, ²⁸Department of Andrology, Fundacio Puigvert, Barcelona, Spain, ²⁹Department of Urology, Aristotle University of Thessaloniki, Thessaloniki, Greece, ³⁰SCM Clinic and Hospital, New Delhi, India, ³¹Department of Endocrinology, Polytechnic University of Marche, Ancona, Italy, ³²Department of Metabolism, Digestion and Reproduction, Imperial College London, London, UK, ³³Department of Medical Bioscience, University of the Western Cape, Bellville, South Africa, ³⁴Department of Andrology, Binh Dan Hospital, Ho Chi Minh City, Vietnam, ³⁵Department of Urology and Andrology, Pham Ngoc Thach University of Medicine, Ho Chi Minh City, Vietnam, ³⁶Department of Urology, Bolu Abant Izzet Baysal University, Bolu, Turkey, ³⁷Department of Urology, Faculty of Medicine, Hacettepe University, Ankara, Turkey, ³⁸Department of Urology, Juntendo University Urayasu Hospital, Chiba, Japan, ³⁹Department of Andrology, Sexology and STIs, Faculty of Medicine, Cairo University, Cairo, Egypt, ⁴⁰Department of Urology, Taksim Education and Research Hospital, Istanbul, Turkey, ⁴¹Department of Urology, Faculty of Medicine, Bandırma Onyedi Eylül University, Balıkesir, Turkey, ⁴²Reproductive medicine, Clinical Research Centre, Lund University, Malmö, Sweden, ⁴³Department of Urology, Polytechnic University of Marche Region, Ancona, Italy, ⁴⁴S. H. Ho Urology Centre, Department of Surgery, The Chinese University of Hong Kong, Hong Kong, China, ⁴⁵Department of Urology, Universiti Teknologi Mara (UiTM) Specialist Centre, Selangor, Malaysia, ⁴⁶PO San Giovanni Bosco, ASL Napoli 1 Centro, Napoli, Italy, ⁴⁷Fleury Group and Hospital Israelita Albert Einstein, São Paulo, Brazil, ⁴⁸Andrology and Reproductive Medicine Unit, Gynepro Medical, Bologna, Italy, ⁴⁹Fertility Medical Group, São Paulo, Brazil, ⁵⁰Department of Urology, Biruni University School of Medicine, Istanbul, Turkey, ⁵¹Department of Urology and Andrology, University Hospital of Toulouse, France, ⁵²Department of Urology, School of Medicine, Baskent University, Konya, Turkey, ⁵³Asl Bari, PTA "F Jaia", Reproductive and IVF unit, Andrology Outpatients Clinic, Asl Bari, Conversano (Ba), Italy, ⁵⁴Andrology Unit, ART Center - San Carlo Clinic, Paderno Dugnano, Milan, Italy, ⁵⁵Andrology Section, Siloam Sriwijaya Hospital, Palembang, Indonesia, ⁵⁶Department of Urology, Hatay Mustafa Kemal University, Antakya, Turkey, ⁵⁷Laboratory of Seminology—Sperm Bank "Loredana Gandini", Department of Experimental Medicine, University of Rome "Sapienza", Rome, Italy, ⁵⁸Department of Urology, IRCCS Fondazione Ca Granda Ospedale Maggiore Policlinico, Milan, Italy, ⁵⁹Department of Urology, School of Medicine, Udayana University, Denpasar, Indonesia, ⁶⁰Department of Urology, Innsbruck Medical University, Innsbruck, Austria, ⁶¹Department of Urology and Organ Transplantation, University of Foggia, Ospedali Riuniti di Foggia, Foggia, Italy, ⁶²Department of Urology, University of Florence, Florence, Italy, ⁶³Department of Surgery, School of Clinical Sciences, Monash University, Melbourne, Australia, ⁶⁴Department of Urology, The Alfred Hospital, Melbourne, Australia, ⁶⁵Department of Urology, Policlinico Umberto I, Sapienza University of Rome, Rome, Italy, ⁶⁶Department of Urology, University of Trieste, Trieste, Italy, ⁶⁷Department of Urology, Weill

Cornell Medicine-Qatar, Doha, Qatar, ⁶⁸Department of Urology, Peking University Third Hospital, Peking University, Beijing, China, ⁶⁹Department of Urology and Andrology, Kansai Medical University, Hirakata, Osaka, Japan, ⁷⁰Department of Urology, Pusan National University School of Medicine, Busan, Korea, ⁷¹Medical Research Institute of Pusan National University Hospital, Busan, Korea, ⁷²Department of Urology, College of medicine and pharmacy, Ibn Zohr University, Agadir, Morocco, ⁷³Department of urology, Faculty of Medicine, Istanbul Medipol Mega University Hospital, Istanbul, Turkey, ⁷⁴Department of Surgery (Urology), University of Utah, Salt Lake City, UT, USA, ⁷⁵Department of Andrology, Hammersmith Hospital, Imperial, London, UK, ⁷⁶Servicio de Urología, Hospital Clínico de Barcelona, Barcelona, Spain, ⁷⁷Division of Urology, Department of Surgery, The Chinese University of Hong Kong, Hong Kong, China, ⁷⁸Department of Urology, Silopi State Hospital, Sirtak, Turkey, ⁷⁹Department of Urology, University of Illinois, Chicago, IL, USA, ⁸⁰Department of Urology, School of Medicine and Health Sciences, University of Lusaka, Lusaka, Zambia, ⁸¹Department of Urology, Kobe University Graduate School of Medicine, Kobe, Japan, ⁸²Department of Urology, Toho University Faculty of Medicine, Tokyo, Japan, ⁸³Department of Urology, Universitas Airlangga/Rumah Sakit Universitas Airlangga Teaching Hospital, Surabaya, Indonesia, ⁸⁴Department of Urology and Andrology, Locust Medicus, Athens, Greece, ⁸⁵Department of Urology, University of Washington, Seattle, WA, USA, ⁸⁶Instituto de Ginecología y Fertilidad (IFER), Universidad de Buenos Aires, Buenos Aires, Argentina, ⁸⁷Department of Urology, Molinette Hospital, A.O.U. Città della Salute e della Scienza, University of Turin, Torino, Italy, ⁸⁸Section of Urology, Department of Surgery, University of Santo Tomas Hospital, Manila, Philippines, ⁸⁹Department of Urology, Hacettepe University, Ankara, Turkey, ⁹⁰Department of Urology, Herlev and Gentofte University Hospital, Copenhagen, Denmark, ⁹¹Department of Clinical Medicine, University of Copenhagen, Copenhagen, Denmark, ⁹²Department of Surgery, Urology Division, Sultan Qaboos University, Muscat, Oman, ⁹³Department of Andrology, Reproductive Biomedicine Research Center, Royan Institute for Reproductive Biomedicine, ACECR, Tehran, Iran, ⁹⁴Department of Urology, Faculty of Medicine, Universitas Airlangga, Surabaya, Indonesia, ⁹⁵Andrology Committee of the Algerian Association of Urology, Algiers, Algeria, ⁹⁶Department of Urology, Ioannina University School of Medicine, Ioannina, Greece, ⁹⁷Department of Urology, Cipto Mangunkusumo General Hospital, Faculty of Medicine, Universitas Indonesia, Jakarta, Indonesia, ⁹⁸B.Y.L Nair Ch Hospital, Mumbai, India, ⁹⁹Department of Urology, University of Toledo College of Medicine and Life Sciences, Toledo, OH, USA, ¹⁰⁰Department of Urology, Al - Ahlia Hospital Abu Dhabi UAE, Abu Dhabi, UAE, ¹⁰¹Department of Urology, Centro Universitario em Saude do ABC, Santo André, Brazil, ¹⁰²Andrology Group at Ideia Fertil Institute of Human Reproduction, Santo André, Brazil, ¹⁰³Department of Urology and Andrology, AIG Hospitals, Hyderabad, Telangana, India, ¹⁰⁴Urology Institute, University Hospitals, Case Western Reserve University, Cleveland, OH, USA, ¹⁰⁵Department of Urology, Faculty of Medicine Universitas Padjadjaran, Hasan Sadikin General Hospital, Bandung, Indonesia, ¹⁰⁶Department of Andrology, Uromedica Polyclinic, Belgrade, Serbia, ¹⁰⁷IVF Australia, Sydney, New South Wales, Australia, ¹⁰⁸Macquarie School of Medicine, Macquarie University, Sydney, New South Wales, Australia, ¹⁰⁹Department of Urology, Graduate School of Medicine, Osaka University, Osaka, Japan, ¹¹⁰Department of Urology, Korea University College of Medicine, Seoul, Korea, ¹¹¹Department of Surgery, Faculty of Medicine, University of Malaya, Kuala Lumpur, Malaysia, ¹¹²Department of Urology, Reproduction Center, Yokohama City University Medical Center, Yokohama, Kanagawa, Japan, ¹¹³Department of Urology, Nagano Red Cross Hospital, Nagano, Japan, ¹¹⁴Perth Urology Clinic, Perth, WA, Australia, ¹¹⁵Andrology Unit, Department of Urology, Apollo Hospitals, Greaves Road, Chennai, India, ¹¹⁶Andrology Center & Urology Department, Peking University First Hospital, Peking University, Beijing, China, ¹¹⁷Department of Integrative Cancer Therapy and Urology, Kanazawa University Graduate School of Medical Science, Kanazawa, Japan, ¹¹⁸Department for Transfusion Medicine and Transplantation Biology, Reproductive Tissue Bank, University of Zagreb, School of Medicine, University Hospital Zagreb, Zagreb, Croatia, ¹¹⁹Department of Surgery, United Christian Hospital, Hong Kong, China, ¹²⁰Department of Urology, Martha-Maria Hospital Nuremberg, Nuremberg, Germany, ¹²¹Stone and Prostate Treatment Services/Pelvic Floor Center and Anorectal Diseases, St. Luke's Medical Center, Quezon City, Metro Manila, Philippines, ¹²²Department of Andrology, Fundació Puigvert, Universitat Autònoma de Barcelona, Barcelona, Spain, ¹²³Department of Urology, Faculty of Medicine, Suez Canal University, Ismailia, Egypt, ¹²⁴Center for Andrology and Sexual Medicine, Viet Duc University Hospital, Hanoi, Vietnam, ¹²⁵Department of Urology, Andrology and Sexual Medicine, University of Medicine and Pharmacy, Vietnam National University, Hanoi, Vietnam, ¹²⁶Department of Urology, Gülhane Research and Training Hospital, University of Health Sciences, Ankara, Turkey, ¹²⁷Advanced Urology Associates, Singapore, ¹²⁸Mount Elizabeth Hospital, Singapore, ¹²⁹Department of Urology, Lebanese University, Beirut, Lebanon, ¹³⁰Department of Urology, Al Zahraa Hospital, UMC, Lebanon, ¹³¹King Fahad Specialist Hospital, Dammam, Saudi Arabia, ¹³²King Faisal Specialist Hospital and Research Center, Riyadh, Saudi Arabia, ¹³³Urology and Andrology Center, CODRA Hospital, University of Montenegro, Podgorica, Montenegro, ¹³⁴Department of Urology, Sina Hospital, Tehran University of Medical Sciences, Tehran, Iran, ¹³⁵Department of Urology, Užice General Hospital, Zlatibor, Serbia, ¹³⁶Sexual Health and Fertility Research Center, Shahroud University of Medical Sciences, Shahroud, Iran, ¹³⁷Urology Unit, Department of Surgery, Hospital Angkatan Tentera Tuanku Mizan, Kuala Lumpur, Malaysia, ¹³⁸Department of Urology, Mubarak Al-Kabeer Teaching Hospital, Kuwait University, Jabriya, Kuwait, ¹³⁹Department of Medicine, Imam Abdulrahman Bin Faisal University, Dammam, Saudi Arabia, ¹⁴⁰Department of Andrology, Shariati Medical Center, Tehran University of Medical Sciences, Tehran, Iran, ¹⁴¹Department of Urology, Pediatric Urology and Andrology, Justus-Liebig-University Giessen (GER), University Hospital Giessen and Marburg GmbH, Campus Giessen, Giessen, Germany, ¹⁴²Santa Casa de Ribeirão Preto, Ribeirão Preto, Brazil, ¹⁴³Department of Urology, Hospital de Clínicas of the Federal University of Paraná, Curitiba, Brazil, ¹⁴⁴Androlab, Fertility Clinic, Curitiba, Brazil, ¹⁴⁵Department of Urology, Cleveland Clinic, Abu Dhabi, UAE, ¹⁴⁶Department of Andrology, PKU 3rd Hospital Reproductive Medicine Center, Beijing, China, ¹⁴⁷Department of Urology, University Hospital Innsbruck, Innsbruck, Austria, ¹⁴⁸Department of Urology, SMG-SNU Boramae Medical Center, Seoul, Korea, ¹⁴⁹Division of Surgery, Department of Surgery and Cancer, Imperial College London, London, UK, ¹⁵⁰Department of Urology, National University Hospital, Singapore, ¹⁵¹Department of Surgery, University of the Philippines College of Medicine, Manila, Philippines, ¹⁵²Department of Urology, University of Insubria, Varese, Italy, ¹⁵³Examenlab Ltd., Northern Ireland, UK, ¹⁵⁴Department of Reproductive Endocrinology and Andrology, Imperial College London, London, UK, ¹⁵⁵Department of Andrology, Hammersmith & St. Mary's Hospitals, London, UK, ¹⁵⁶Department of Andrology, Centro ANDROGEN, La Coruña, Spain, ¹⁵⁷Department of Urology, Gleneagles Hospital, Singapore, ¹⁵⁸Department of Urology, University of Virginia School of Medicine, Virginia, USA, ¹⁵⁹Department of Urology, East Avenue Medical Center, Quezon City, Philippines,

¹⁶⁰Department of Urology, Copenhagen University Hospital - Herlev and Gentofte Hospital, Herlev, Denmark, ¹⁶¹Avant Concierge Urology & University of Central Florida, Winter Garden, FL, USA, ¹⁶²Department of Physiology, Faculty of Medicine, Universiti Teknologi MARA, Sungai Buloh Campus, Selangor, Malaysia, ¹⁶³SCSA Diagnostics, Brookings, SD, USA, ¹⁶⁴Department of Nephro-Urology, Nagoya City West Medical Center, Nagoya, Japan, ¹⁶⁵Urological and Human Reproduction Unit, Quiron Hospital, Barcelona, Spain, ¹⁶⁶Department of Urology, Başakşehir Çam and Sakura City Hospital, Istanbul, Turkey, ¹⁶⁷Department of Embryology and Histology, Zonguldak Bülent Ecevit University Institute of Health Sciences, Zonguldak, Turkey, ¹⁶⁸Next Fertility Procrea, Lugano, Switzerland, *Members of the Global Andrology Forum are listed in the Acknowledgements

Purpose: Varicocele is a common problem among infertile men. Varicocele repair (VR) is frequently performed to improve semen parameters and the chances of pregnancy. However, there is a lack of consensus about the diagnosis, indications for VR and its outcomes. The aim of this study was to explore global practice patterns on the management of varicocele in the context of male infertility.

Materials and Methods: Sixty practicing urologists/andrologists from 23 countries contributed 382 multiple-choice-questions pertaining to varicocele management. These were condensed into an online questionnaire that was forwarded to clinicians involved in male infertility management through direct invitation. The results were analyzed for disagreement and agreement in practice patterns and, compared with the latest guidelines of international professional societies (American Urological Association [AUA], American Society for Reproductive Medicine [ASRM], and European Association of Urology [EAU]), and with evidence emerging from recent systematic reviews and meta-analyses. Additionally, an expert opinion on each topic was provided based on the consensus of 16 experts in the field.

Results: The questionnaire was answered by 574 clinicians from 59 countries. The majority of respondents were urologists/uro-andrologists. A wide diversity of opinion was seen in every aspect of varicocele diagnosis, indications for repair, choice of technique, management of sub-clinical varicocele and the role of VR in azoospermia. A significant proportion of the responses were at odds with the recommendations of AUA, ASRM, and EAU. A large number of clinical situations were identified where no guidelines are available.

Conclusions: This study is the largest global survey performed to date on the clinical management of varicocele for male infertility. It demonstrates: 1) a wide disagreement in the approach to varicocele management, 2) large gaps in the clinical practice guidelines from professional societies, and 3) the need for further studies on several aspects of varicocele management in infertile men.

Keywords: Consensus; Disease management; Male infertility; Survey; Varicocele

This is an Open Access article distributed under the terms of the Creative Commons Attribution Non-Commercial License (<http://creativecommons.org/licenses/by-nc/4.0>) which permits unrestricted non-commercial use, distribution, and reproduction in any medium, provided the original work is properly cited.

INTRODUCTION

Varicocele, defined as an abnormal enlargement and tortuosity of veins in the pampiniform plexus, is the most common correctable cause of male infertility [1]. Varicocele affects nearly 15% of the general male population and is diagnosed in 19% to 41% of primary male infertility and 80% of secondary male infertility cases [2]. An epidemiological study from six European countries, involving 7,035 male subjects from the general population, indicated the presence of clinical varicocele (grades I–III) in 15.7% of the population, with more than 50% of the men having a variable degree of semen quality deterioration [3]. Despite the lack of history of infertility in the latter study, impaired semen quality was present even in low grades of varicocele

and it was more pronounced in those men with grade III varicoceles. This is keeping with an earlier study from the World Health Organization (WHO) which reported the prevalence of varicocele among infertile patients with normal and abnormal semen parameters as 11.7% and 25.4%, respectively [4].

Using bibliometric analytics, Baskaran et al. reported that the number of publications on male infertility and varicocele demonstrated an increasing trend from 1988 to 2018 [5]. A more recent scientometric study on human varicocele research showed that between the years 1988 and 2020, there were four times more original articles published on surgical approaches compared to non-surgical options [6]. However, despite all these studies, the practical management of varicocele for fertility and non-fertility related indications is not clearly

established and many areas of controversy still remain.

Current challenges in the management of subfertile men with varicocele include determining the true benefit of varicocele repair (VR) on pregnancy and live birth rates [7]. The improvement in sperm parameters and reduction in seminal reactive oxygen species (ROS) or sperm DNA fragmentation (SDF) after VR is highly variable and may depend on various factors such as grade of varicocele, age of patient, testes size, pre-treatment sperm parameters and hormone levels. Moreover, the role of VR in the management of infertile men with varicocele and azoospermia or in those with subclinical varicocele remains controversial. Additionally, there is no consensus as to the management of infertile men with varicocele recurrence. As a result, considerable variation and controversy is expected in the worldwide practice patterns of varicocele management for different clinical situations.

The aim of this study was to use a comprehensive online survey to determine the attitudes and practice patterns of clinicians worldwide in the management of varicocele in infertile men, thus identifying divergence and concurrence in global practice patterns, and to compare these with the latest international (American Urological Association/American Society for Reproductive Medicine [AUA/ASRM], European Association of Urology [EAU]) practice guidelines, and with evidence from systematic reviews and recent meta-analyses. Finally, in order to provide further clarity in each area of varicocele evaluation and management, an "Expert Opinion" has been provided based on the consensus of 16 highly-experienced experts from around the globe.

MATERIALS AND METHODS

1. Survey design and participants

One hundred and eight urologists/andrologists from 34 countries were invited to submit multiple-choice questions (MCQs) on varicocele-related clinical topics that they considered most important or controversial and relevant to their practice. A total of 382 questions were received from 60 practicing urologists/andrologists from 23 countries. A team of 9 experienced urologists/andrologists* (RS, PK, AR, NP, EK, NT, MEB, HK, TM) made multiple revisions to merge related or duplicate questions, remove ambiguity, and create a list of questions that were most representative of clinical dilemmas in actual practice.

Questionnaire revisions yielded a final list of 55 MCQs (Supplement File 1), which covered important aspects related to varicocele demographics and diagnosis, indications for VR, technical aspects of VR, and fertility-related outcomes. Eight of the 55 questions addressed VR for indications other than fertility and are not discussed in this paper. An additional 8 questions documented the participants' demographic data.

This questionnaire was made available online from July 23, 2021 to August 20, 2021 *via* a secured tool (SelectSurvey) created by the Cleveland Clinic's Information Technology Department. The initial invitation to take the survey was sent to 200 urologists/andrologists who were part of a global group initiated by the American Center of Reproductive Medicine with the purpose of discussing clinical and research topics related to varicocele. In turn, they forwarded the invitation to their colleagues involved in the care of infertile men through direct communication. The following societies distributed the questionnaire link to their members: Arab Association of Urology, Asia Pacific Society of Sexual Medicine, Association Francaise d'Urologie, Brazilian Association of Assisted Reproduction, Brazilian Society of Urology, Egyptian Society of Andrology, European Association of Urology, Indonesian Urological Association, Indonesian Society of Andrological Urology, Iranian Urological Association, Middle East Society for Sexual Medicine, Sociedad Argentina de Andrologia, Société d'Andrologie de Langue Française, Société Internationale d'Urologie, Spanish Association of Andrology, Sexual and Reproductive Medicine, Turkish Association of Urology, and Urological Society of Australia and New Zealand. Practitioners were informed about the nature and objective of the survey and requested to volunteer to fill out the online questionnaire. The questionnaire was provided in the English language and used standard medical terms. Participants were allowed to omit some questions and could review their answers at the end of the survey before final submission.

2. Statistical analysis

The survey responses were downloaded and saved as comma-separated (CSV) files from the SelectSurvey tool. Duplicate responses were excluded from the analysis. Summary statistics were calculated using MedCalc Statistical Software (version 19.0.5; MedCalc Software, Ostend, Belgium). Since some respondents skipped

some questions, and some questions allowed multiple answers, each response was reported as a percentage of the number of respondents for that question. Subgroup analyses were performed using the chi-square test. A p-value of <0.05 was considered statistically significant.

3. International guidelines and other recommendations

The latest guidelines from the EAU [8,9] and the AUA/ASRM [10-12] were selected as references since these have been recently updated and are widely referred to. The clinical practices of the survey respondents were compared to these guidelines. Additionally, recent systematic reviews and meta-analyses, and other relevant studies, were referred to for clarification on the diverse practices and opinions expressed by the survey respondents.

4. Expert opinion

Since many of the controversial topics were not addressed by the guidelines, sixteen highly-experienced clinicians[†] (GMC, AZ, AK, MG, AR, PK, TH, EK, GR, HK, MA, TT, EB, OR, GC, AH) from around the world were invited to comment on each section. Their comments were condensed into an “Expert Opinion” that was representative of the opinion of most experts (75% consensus) and would provide practical guidance to clinicians. The alternative opinions are also presented in addition to the consensus opinion when there was a significant difference of opinion amongst the expert panel.

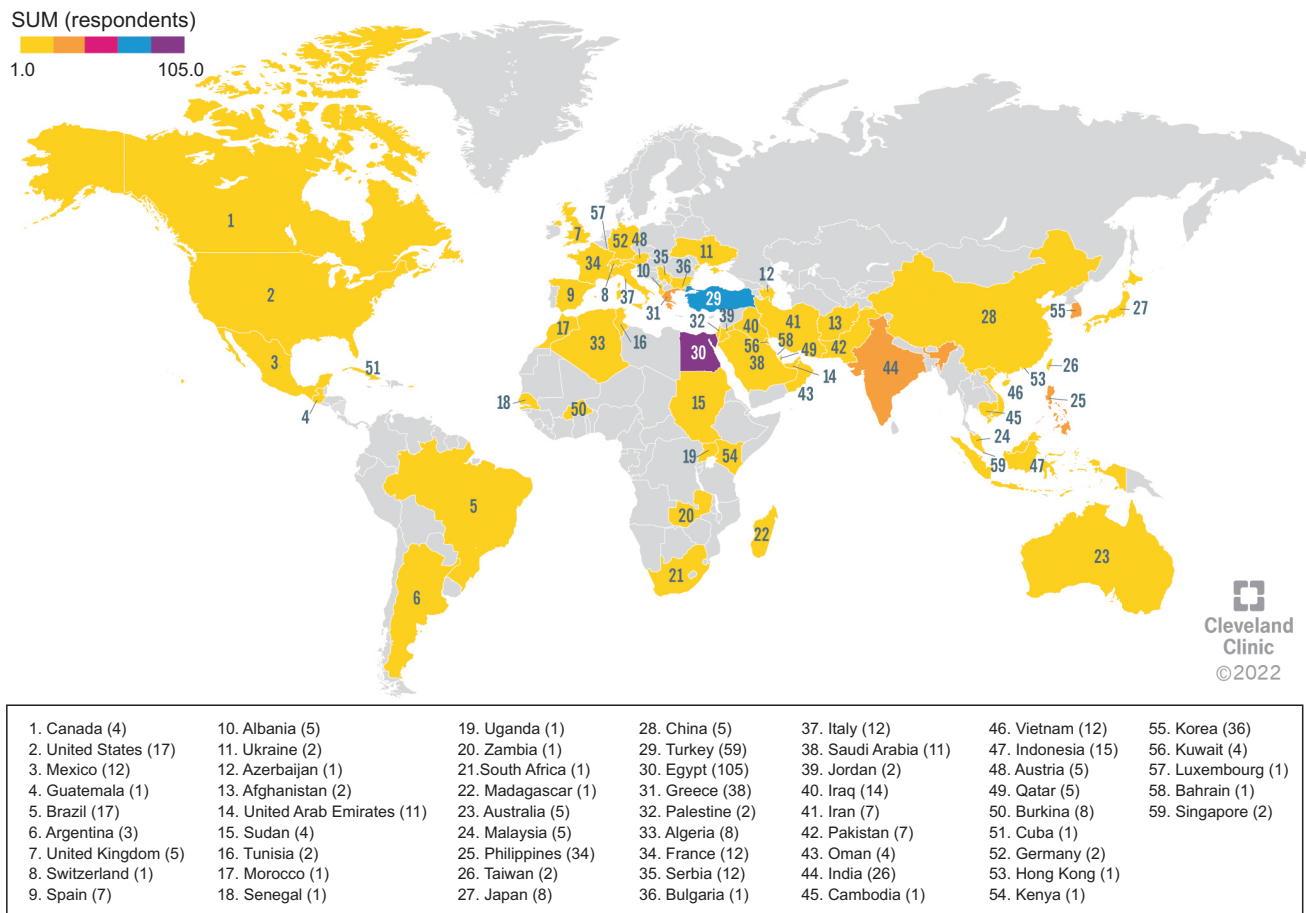


Fig. 1. Geographical distribution of respondents. The number of respondents is shown in brackets after the name of each country. The violet color indicates the country with the greatest number of respondents (n=105), the blue color are those with a lower number (n=59), the orange color are those with a further reduction in the number of respondents (from 26 to 38), and the yellow color are the countries with the lowest number of respondents (from 1 to 17).

RESULTS AND DISCUSSION

1. Demographics of survey participants

The total number of responses received at the end of the survey was 841. After excluding duplicates and partial responses, a total of 574 responses from 59 countries were considered for analysis (Fig. 1, Supplement File 2).

Geographical distribution of the respondents included Asia (n=277, 48.3%), Europe (n=103, 17.9%), South America (n=34, 5.9%), Africa (n=134, 23.3%), North America (n=21, 3.7%), and Australia (n=5, 0.9%).

The majority of the respondents' age were between 35 and 44 years (n=184, 32.1%) and 45–54 years (n=146, 25.4%), followed by 25–34 years (n=108, 18.8%), 55–64 years (n=94, 16.4%), and over 65 years (n=42, 7.3%).

The respondents were equally divided between general urologists (n=227, 39.5%) and urologists with a special interest in male infertility (n=226, 39.4%). Primary practice was andrology in 15.9% (n=91) and “other” in 4.9% (n=28). Approximately half (n=277, 48.3%) of the respondents had training in clinical andrology. The respondents had a wide range of experience: <5 years, 24.6%; 5 to 10 years, 21.9%; 11 to 20 years, 22.8%; and >20 years, 30.7%.

The respondents' frequency of performing VR was also very varied (Fig. 2)

The majority of respondents indicated that they agreed in varying degrees with the premise of this survey that “the results of varicocele treatment for male infertility are controversial” (Fig. 3).

Q7. “How many varicocele operations (embolization or surgery) do you perform in a year? (Pre-COVID)”

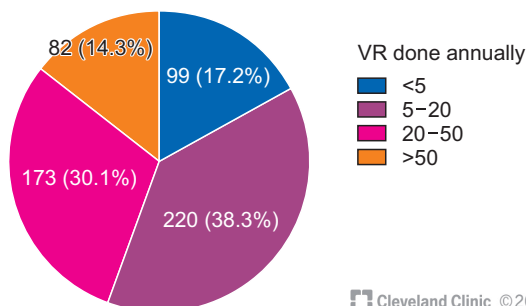


Fig. 2. Number of varicocele repairs (VRs) done annually by the respondents.

2. Diagnosis of varicocele

1) Method of diagnosis of varicocele

(1) Survey results

Majority of respondents (70.4%; 404/574) based their diagnosis of varicocele on a combination of clinical findings and confirmation by duplex Doppler ultrasound (US) whereas 18.6% (107/574) based their diagnosis on physical examination alone. However, 9.9% (57/574) used imaging alone to diagnose a varicocele, and a few used clinical findings combined with thermography or venography.

(2) Guidelines

The AUA/ASRM guidelines (statement-21) state that “routine use of ultrasonography to investigate presumed varicocele is to be discouraged” and recommend that varicocele should be diagnosed based on physical examination alone, with sonography being done only if the physical examination is difficult.

The EAU guidelines (10.3.6.1.2) also state that the “management of varicocele is still mainly based on a physical examination”, but they also suggest the use of US when “palpation is unreliable” or when recurrence or persistence is suspected due to lack of improvement in semen parameters after VR. They also state that “definitive evidence of reflux and venous diameter may be utilised in the decision to treat”.

(3) Discussion

While 18.6% of respondents rely solely on physical examination to establish diagnosis of varicocele, the majority routinely confirm their diagnosis with US

Q8. “What is your level of agreement with the statement ‘the results of varicocele treatment for male infertility are controversial’?”

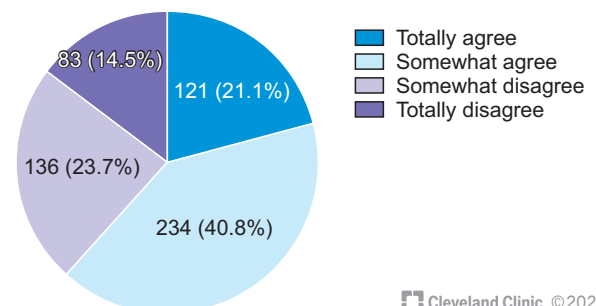


Fig. 3. Degree of agreement of the respondents with the premise of the survey.

even though this is not indicated by the guidelines. Possible reasons for this widespread use of US to confirm a clinically diagnosed varicocele are discussed in the section below (2.1.4).

Interestingly, 10% of the surveyed clinicians still establish a diagnosis of varicocele based on US alone. This is contrary to the guidelines' recommendations that state that US is not indicated if there is no palpable clinical varicocele, since subclinical varicocele should not be corrected.

(4) Expert opinion

Given the absence of evidence supporting the correction of subclinical varicoceles, the diagnosis of varicocele should be based primarily on physical examination and not on imaging alone. Routine US imaging to look for a varicocele in every man with subfertility, irrespective of physical findings, is not warranted.

US is useful when local examination is difficult (*e.g.*, tight scrotum or thick spermatic cord), and may also be used to confirm clinical recurrence, or to confirm the diagnosis when clinical findings are equivocal (the experts were divided on this: some recommended US to confirm a clinical diagnosis of grade I varicocele, while others felt the diagnosis should be purely clinical). Some experts recommended US to assess the grade of reflux in a clinical varicocele and considered this in their decision to recommend VR. US was also recommended by some experts for objective documentation prior to VR, for insurance re-imburement and in case of a legal issue.

2) Ultrasound parameters for the diagnosis of varicocele

(1) Survey results

Although the diagnosis of varicocele is based on clinical examination, many clinicians still use US examination for confirmation. About one-third of the respondents do not do US studies themselves. Of the 391 who responded, 56.0% (219 respondents) reported using 3 mm venous diameter for diagnosing varicocele, while 29.4% used 2.5 mm and 11.3% used 2 mm vein diameter as the diagnostic cut-off. A cut-off of >4 mm was used by 3.3%. Sub-group analysis showed that physicians who received specific training in male infertility, or who had more than 10 years experience, were more likely to perform US examinations themselves, and use

3 mm vein diameter as the diagnostic cut-off.

(2) Guidelines

The AUA/ASRM guidelines (statement 21) specify the presence of multiple veins with a diameter >3 mm and reversal of blood flow during Valsalva for US diagnosis of varicocele, but do not make any other technical recommendations.

The EAU (10.4.3.2) has adopted the recommendations of the European Society of Urogenital Radiology Scrotal and Penile Imaging Working Group [13]. Varicocele diagnosis is based on a venous diameter of 3 mm or more of the largest vein measured at any location in the upright position during a Valsalva maneuver and with venous reflux of duration >2 seconds.

(3) Discussion

Since US is widely used to confirm a diagnosis of varicocele, it is important to have a consensus of what venous diameter parameters constitute a US diagnosis of varicocele. However, the size of the veins required to diagnose varicoceles differs in the literature. This variation may be caused by different evaluation positions (supine or upright position), examination either at rest or with Valsalva maneuver, or different measurement sites (relative to the testis or the spermatic cord).

The 3 mm venous diameter threshold during the Valsalva maneuver is widely accepted in the scientific literature for the diagnosis of varicocele [14,15]. However, there is considerable variation in practice with 40.6% of respondents diagnosing varicocele even when vein diameters are less than 3 mm. They are supported by some studies that have validated the diagnostic utility of smaller vein diameters. Karami et al [16] found 2.65 mm as the threshold to differentiate patients with clinical varicocele from normal subjects with high sensitivity and specificity. However, there are no studies that support 2 mm as the cut-off value, which was used by 11.2% of the respondents. The presence of continuous reflux in the spermatic vein has also been suggested as a useful Doppler finding that predicts improvement after VR [17].

(4) Expert opinion

The considerable divergence in the US diagnosis of varicocele needs to be avoided to ensure uniformity of diagnosis and management. Current evidence favors the adoption of the EAU recommendations for the

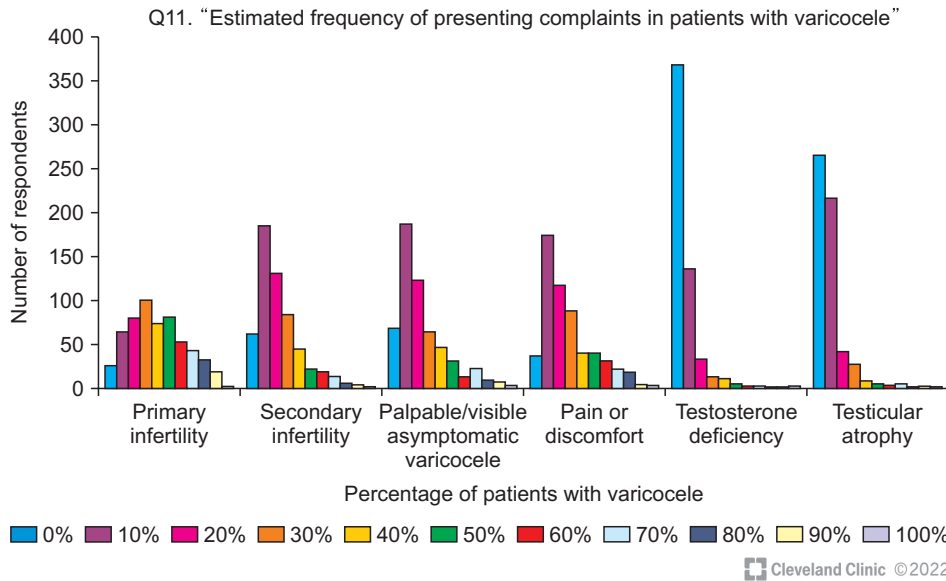


Fig. 4. Estimated percentage of patients presenting with common symptoms related to varicocele.

US diagnosis of varicocele as mentioned above. When US evaluation is indicated to diagnose a varicocele, it should be performed in the upright position, during Valsalva, at a fixed location on the cord and with measurement of venous reflux.

Improper use of the US and lack of consensus on the threshold values used to diagnose clinical varicocele could result in over-diagnosis of early varicoceles and would lead to unnecessary surgeries and/or confusion about outcomes after treatment of 'grade-I' varicoceles.

3. Incidence and symptoms of varicocele

1) Survey results

The estimated frequency of presenting symptoms in men (adult and adolescent) with varicocele is presented in Fig. 4.

Primary infertility was reported as the commonest presenting symptom of varicocele. In response to a question on their estimate of what proportion of men with oligoasthenoteratozoospermia (OAT) had a clinical varicocele, there is a wide divergence in the respondents' estimates. Thus, while 13.9% of respondents reported an estimated incidence of <10%, a slightly larger percentage (18.8%) reported that >50% of their infertile men had varicoceles. The remaining clinicians were also equally divided between a prevalence of 10%–25% (33.1%) and 25%–50% (34.1%).

2) Guidelines

The EAU guidelines (10.4.3.3.1) quote a prevalence of

varicocele in almost 15% of the normal male population, in 25% of men with abnormal semen analysis, and in 35%–40% of men presenting with infertility.

3) Discussion

The marked variation in estimated prevalence of varicocele reported by the survey participants suggests a lack of uniformity in the criteria and methods of establishing a diagnosis of varicocele. This may, in turn, be the reason for significant outcome differences reported by various studies.

4) Expert opinion

There is a need for more studies on the prevalence of varicocele in fertile and infertile men using well-defined criteria. Clinical examination is the mainstay of diagnosis but it is subjective, resulting in varying estimates of varicocele prevalence. A combination of clinical findings and strictly defined US criteria may help to ensure uniformity in varicocele diagnosis.

4. Indications for varicocele repair

The various clinical scenarios in which the respondents would advise VR are listed in Table 1.

1) Oligoasthenoteratozoospermia

(1) Survey results

Semen analysis was the most common laboratory test used to evaluate the impact of a clinical varicocele on fertility (n=559, 97.4%), followed by reproductive

Table 1. Indications for varicocele repair in men with infertility

Q17. "What are your indications for varicocele repair in an infertile couple?" (you can choose multiple options)			
Answer	No. of responses	Percentage of respondents	
Infertility with clinical varicocele, abnormal semen analysis, and normal female partner <35 years old	526	91.6	
Infertility with clinical varicocele, and abnormal semen analysis or elevated SDF, irrespective of female partner status	220	38.3	
Infertility with clinical varicocele, normal semen analysis, normal female partner, but elevated SDF	199	34.7	
Clinical varicocele with normal semen analysis, normal SDF, but ipsilateral testicular atrophy	179	31.2	
Infertility with clinical varicocele, normal semen analysis, normal SDF, normal female partner, but failed IUI/IVF	105	18.3	
Infertility with clinical varicocele, normal semen analysis, normal female partner, but elevated OS	94	16.4	
Large asymptomatic, varicocele with normal semen analysis, and normal testicular size	79	13.8	
I do not recommend varicolectomy. I rather prefer to proceed with other treatments (IUI/IVF/ICSI)	7	1.2	
Total number of respondents	574		

ICSI: intracytoplasmic sperm injection, IUI: intrauterine insemination, IVF: *in vitro* fertilization, OS: oxidative stress, SDF: sperm DNA fragmentation.

Q18. "In a couple with primary infertility, clinical varicocele, moderate OAT, and female partner <35 years old with a normal fertility evaluation, what would be your first choice for treatment?"

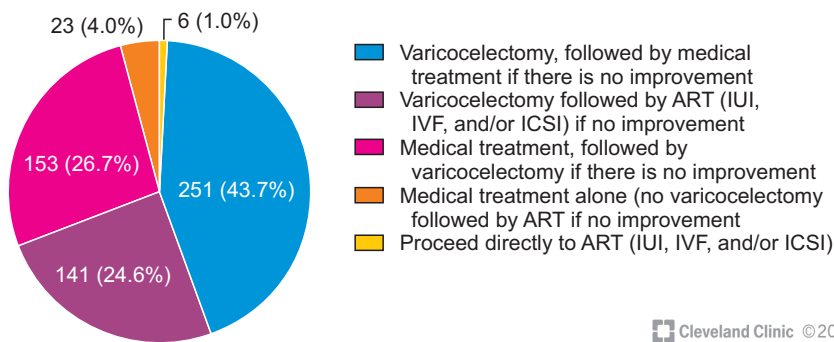


Fig. 5. Therapeutic decisions on the management of a couple with primary infertility and clinical varicocele. OAT: oligoasthenoteratozoospermia, ART: assisted reproductive technology, IUI: intrauterine insemination, IVF: *in vitro* fertilization, ICSI: intracytoplasmic sperm injection.

Cleveland Clinic ©2022

hormonal assay (n=303, 52.8%), SDF (n=150, 26.1%), and oxidative stress (OS) testing (n=38, 6.6%).

When treating a couple with primary infertility, and moderate OAT with a clinical varicocele, 68.3% of the respondents stated that they would directly proceed with VR as the first line of treatment, and then follow-up with medical therapy or assisted reproductive technology (ART) if there was no improvement. 26.7% would first attempt medical therapy before proceeding for VR and 1.0% would proceed to ART without VR (Fig. 5).

This variability in the approach to timing of VR was also reflected in the number of semen analyses the clinicians requested before proceeding for VR. When the first semen analysis was abnormal and a varicocele

was detected, 11% of clinicians would advise surgery right away, and 50.3% would advise surgery if another report within a month showed OAT. However, 28% would wait 3 months before doing another semen test and then advise surgery if OAT persisted, while only 10.6% stated that they would consider multiple semen reports before advising surgery.

This trend towards early surgery is also reflected in the time to surgery once the diagnosis and recommendation for VR are made, with 60.5% (328/542) of respondents stating that most of their patients underwent VR within 3 months of diagnosis.

When a couple has secondary infertility, 12.0% of respondents stated that their decision would be affected by the female partner's age, but the majority (58.5%)

Q19. "In a couple with secondary infertility, clinical varicocele, moderate OAT, and female partner with a normal fertility evaluation, what would be your first choice for treatment?"

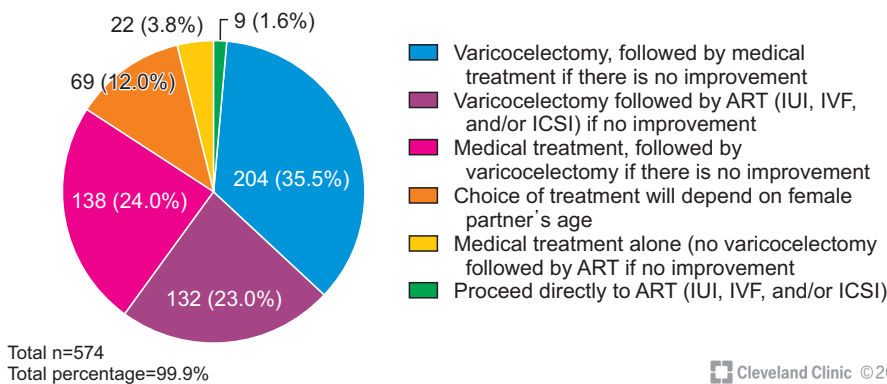


Fig. 6. Therapeutic decisions on the management of a couple with secondary infertility and clinical varicocele. OAT: oligoasthenoteratozoospermia, ART: assisted reproductive technology, IUI: intrauterine insemination, IVF: *in vitro* fertilization, ICSI: intracytoplasmic sperm injection.

still recommended VR as the first step; only 1.6% suggested proceeding directly to ART (Fig. 6).

The severity of OAT was not a deterrent to advising surgery. Responding to a case scenario of severe OAT (<1 mill/mL) associated with grade 2 or 3 varicocele, 73.3% said they would advise VR as the first line of treatment and 17.9% would consider VR if intracytoplasmic sperm injection (ICSI) had failed.

(2) Guidelines

The AUA/ASRM guidelines (statement 25) recommend VR if there is infertility and palpable varicocele associated with "abnormal semen parameters, except for azoospermic men." The older AUA/ASRM guidelines (2012) [18] also recommend VR in men with abnormal semen analysis even if they are not currently attempting conception. The EAU guidelines (10.4.3.3.2) state that VR results in significant improvement in abnormal semen parameters including in some men with non-obstructive azoospermia (NOA), and recommend VR in men with OAT, and also suggests that couples with "otherwise unexplained subfertility" may also benefit from VR.

(3) Discussion

The latest Cochrane review [7] states that VR for men with OAT may improve pregnancy rates but it is uncertain whether live birth rates increase. Despite this opinion, the majority of respondents favored VR before proceeding to ART, and recommended VR as the first step in treatment, in accordance with the guidelines. A different opinion may have been expressed if the survey population had comprised IVF specialists.

However, one-third of the respondents felt that there

was no need to rush into VR and that patients may benefit from an initial trial with medical management before considering surgery. This is in concordance with a recent meta-analysis which suggested that while antioxidants (AOX) did not improve pregnancy rates in men who had VR, AOX may be of benefit in men with unoperated varicoceles [19]. Giving a couple time to conceive naturally without rushing into VR, especially if they are young, is supported by a study that showed similar pregnancy rates between conservative and surgical approaches when the duration of infertility was short, but greater chances of pregnancy after VR if the couple has been infertile for more than 2 years [20].

Thus, there is no consensus or guidelines on the timing of VR. Some clinicians feel that once a varicocele is detected it should be corrected quickly to prevent further deterioration. Others adopt a more conservative approach before advising VR [21].

(4) Expert opinion

VR is a useful procedure for the treatment of men with OAT and this is reflected in global practice patterns and the EAU/AUA/ASRM guidelines.

Considering the natural variations in semen parameters, the possibility of fertility despite the presence of an untreated varicocele, and the uncertainty about VR outcomes, it is reasonable to not rush into VR if the couple is young and the duration of infertility is short (1–2 years). However, other than this, VR can be recommended as the first step when there is OAT and a clinical varicocele, after proper counseling about the likelihood of benefit after VR (see section 7.2).

The role and duration of conservative management in couples with varicocele needs further critical evalu-

ation as this may help identify couples that can be managed medically (avoiding unnecessary VR) from those that are better managed by early VR.

2) Isolated asthenozoospermia

(1) Survey results

VR for men with isolated asthenozoospermia was routinely advised by 63% of the respondents, while 22% would advise it in selected cases.

(2) Guidelines

The EAU and AUA/ASRM guidelines do not specifically mention whether varicocele surgery is indicated in men with isolated asthenozoospermia, though the previous AUA/ASRM guidelines [18] stated “one or more parameters” should be abnormal.

(3) Discussion

“Isolated asthenozoospermia” includes a very diverse group of patients. A man with normal sperm count but only 2% motility has a different etiology and prognosis from a man with normal sperm count and 30% motility. A man with low normal sperm count and asthenozoospermia may represent a different pathology from that of a man with high sperm counts and asthenozoospermia.

It is clear that varicoceles can have a negative impact on sperm motility and total motile sperm count (TMSC), and that TMSC can improve significantly after VR [22]. However, there are only a few retrospective studies on the role of VR in isolated asthenozoospermia and they report mixed outcomes [23-25]. They also fail to distinguish between the various sub-groups as discussed above. Thus, there is limited evidence favoring VR in men with isolated asthenozoospermia. However, the high endorsement by the survey respondents for VR in men with isolated asthenozoospermia suggests that, despite lack of reported evidence, the respondents may be seeing a benefit in these patients.

(4) Expert opinion

Further studies are needed to assess the utility of VR in isolated asthenozoospermia. A distinction should be made between different severity and etiologies of asthenozoospermia. Until then, based on the survey respondents' practices, a guarded recommendation can be made for VR in these cases.

3) Isolated teratozoospermia

(1) Survey results

VR for men with isolated teratozoospermia was routinely advised by 41.1% of the respondents, and another 30.3% would do so in selected cases.

(2) Guidelines

The EAU and AUA guidelines do not specifically mention whether VR is indicated in men with isolated teratozoospermia.

(3) Discussion

Teratozoospermia has become a contentious issue. While earlier studies often attributed significant predictive value to morphology [26], recently there has been criticism that the criteria have become too strict resulting in an excessive diagnosis of teratozoospermia and loss of clinical predictive value [27,28]. Hence, the willingness of the majority of respondents to offer VR for isolated teratozoospermia is surprising.

Very few papers address the benefit of VR in men with isolated teratozoospermia and these studies report mixed results. While a study by Cakiroglu et al [24] demonstrated no improvement in sperm morphology after VR in men with otherwise normal sperm counts, other retrospective studies demonstrated an improvement in sperm morphology [29] as well as pregnancy rates [30] after VR. This improvement was most likely seen with cases of immature spermatozoa and spermatozoa with head abnormalities [31].

(4) Expert opinion

There is little evidence to support VR for men with isolated teratozoospermia. However, since the majority of respondents have indicated that they would suggest VR for this indication, there is a need for further studies so that clear recommendations can be made. Monomorphic teratozoospermia (macrozoospermia and globozoospermia) has a genetic basis [32] and VR is not indicated for these cases.

4) Isolated severe necrozoospermia

(1) Survey results

VR for men with isolated severe necrozoospermia was routinely recommended by 42.5% of the respondents, while another 27.4% did so in selected cases.

(2) Guidelines

The EAU and AUA guidelines do not specifically mention whether varicocele surgery is indicated in men with isolated necrozoospermia.

(3) Discussion

The etiology of necrozoospermia is frequently unclear but varicocele has been hypothesized as a possible cause [33]. However, no published studies have evaluated the direct role of VR to improve isolated necrozoospermia.

(4) Expert opinion

There is no evidence to support VR for this indication. Yet, the majority of clinicians have indicated that they would proceed with treatment. Hence, those who perform VR in men with isolated severe necrozoospermia should document and publish their results so that evidence-based recommendations can be made in the future.

5) Isolated increased sperm DNA fragmentation or oxidative stress

(1) Survey results

Among the survey respondents, 34.7% (199/574) indicated of survey respondents indicated that they would consider VR if SDF was increased even if conventional semen parameters were normal (Table 1), and 16.4% (94/574) of respondents would advise VR if the OS markers alone were elevated while 18.3% (105/574) would advise VR even with normal semen parameters

and normal SDF if multiple attempts at intrauterine insemination/*in vitro* fertilization (IUI/IVF) had failed.

(2) Guidelines

AUA/ASRM guidelines (statement 19) state that “there are no well-controlled studies that VR will reduce risk of recurrent pregnancy loss in men with elevated SDF”.

EAU guidelines (10.4.3.3.4) state that there is “increasing evidence” that VR may improve SDF and ART outcomes and recommends VR for men with raised SDF and failed ART (failure of embryogenesis or implantation, or recurrent pregnancy loss) “after extensive counseling”. They make a weak recommendation for VR in men with increased SDF and otherwise unexplained infertility (10.4.3.5), but also state, “the dilemma is whether varicocele treatment is indicated in men with raised DNA fragmentation and normal semen parameters”.

(3) Discussion

SDF has emerged as an important measure of sperm function and a predictor of reproductive outcomes [34]. VR is associated with an improvement in SDF, including both single-strand and double-strand DNA fragmentation, as well as seminal OS [35], and two recent meta-analyses calculated a mean reduction in SDF after VR of 7.23% [36] and 6.14% [37] respectively.

Men with varicoceles frequently have higher rates of SDF and elevated OS even when a semen analysis shows normal semen parameters [38-41]. In a small, controlled trial, Fathi et al [42] reported decreased SDF

Table 2. Varicocele repair prior to IVF

Q23. “If a man has OAT and clinical varicocele and the couple is willing to undergo IVF, what do you recommend?” (you can choose multiple options)		
Answer	No. of responses	Percentage of respondents
Recommend varicocele repair before considering IVF	360	62.7
Correct varicocele if IVF fails	131	22.8
Recommend varicocele repair before IVF, only if SDF is high	102	17.8
Proceed directly with IVF	102	17.8
Depends on the female age	230	40.1
Depends on the severity of the varicocele	132	23.0
Depends on the duration of infertility	83	14.5
Depends on the male age	72	12.5
Total number of respondents	574	

IVF: *in vitro* fertilization, OAT: oligoasthenoteratozoospermia, SDF: sperm DNA fragmentation.

(9% reduction) and higher pregnancy rates in normozoospermia men with high SDF (>25% by sperm chromatin dispersion assay) after VR.

(4) Expert opinion

There is evidence to support VR in men with isolated high SDF. VR may be recommended for such men if other measures to reduce SDF have failed, especially if there is a history of failed ART. Further research is needed to elucidate whether the improvement in SDF and OS after VR in men with a normal semen analysis translates to an increase in natural or ART pregnancy rates.

6) Varicocele repair prior to assisted reproductive technology

(1) Survey results

Interestingly, in a couple planning to undergo IVF, where the man has OAT and varicocele, 62.7% (360/574) of respondents would recommend VR before proceeding to IVF. Some respondents would decide based on the age of the female partner or duration of infertility (Table 2). Another 17.8% (102/574) would recommend VR prior to IVF only if SDF was elevated.

(2) Guidelines

The current AUA/ASRM guidelines do not comment on whether VR prior to IVF will improve pregnancy rates, though they do list VR as an option before IVF when SDF is raised and there is a history of recurrent pregnancy loss (statement 19). However, older AUA/ASRM guidelines [18] state that “VR usually is not indicated as the primary treatment for couples when

IVF is necessary”.

The EAU guidelines state that VR may improve ART outcomes in men with OAT (10.4.3.3.2) and also suggest a role for VR before ART when there is elevated SDF (see discussion above in section 4.5.2).

(3) Discussion

Correcting a varicocele before proceeding for IVF-ICSI is a controversial topic, and many ART centres take no cognizance of a varicocele. However, the majority of survey respondents felt that a varicocele should be corrected before ART. Support for VR before ART comes from a meta-analysis by Esteves et al [43] who reported increased clinical pregnancies and birth rate in 3 of 4 reviewed studies, and from a meta-analysis by Kirby et al [44] who reported that VR improved the ART live birth rate in men with oligospermia (odds ratio [OR], 1.699). Thus, some couples may benefit from having VR before ART. Since VR is a minor procedure compared to the time and expense involved in ART, it may be argued that VR should be done for whatever benefit it may confer.

(4) Expert opinion

Recommending VR to all men prior to ART is a delicate decision since it will delay the ART procedure by 3 to 6 months for an unpredictable benefit. There is a need to identify which subgroups of men with clinical varicoceles will have an improvement in the ART outcomes after prior VR. Until such evidence is available, the decision to perform VR before ART should be individualized based on other variables like varicocele grade, SDF levels, history of prior failure, duration of infertility, female partner’s age, etc., and after a thor-

Table 3. Clinical situations where varicocele repair is not advised

Q25. “In a man with a clinical varicocele, OAT and infertility, when are you likely to NOT advise varicocele repair?” (you can choose multiple options)			
Answer	No. of responses	Percentage of respondents	
Grade of varicocele is mild (grade 1)	242	42.2	
FSH above normal	161	28.0	
Female age >35 years	159	27.7	
Small testes (<10 mL)	149	26.0	
Will usually advise surgery despite any of the above	145	25.3	
Male age >40 years	105	18.3	
Severe OAT (<1 mill/mL)	99	17.2	
Total number of respondents	574		

FSH: follicle stimulating hormone, OAT: oligoasthenoteratozoospermia.

ough discussion with the couple.

When ART is being done for an older woman, and her male partner has OAT with varicocele, some experts suggest that the option of performing both ART and VR can be considered. ART success rate per cycle is low in older women [45], and the possibility of achieving a spontaneous pregnancy if the semen quality improves after VR can never be excluded a priori.

7) When not to recommend varicocele repair

(1) Survey results

Participants listed several clinical situations in which they would not recommend VR (Table 3).

(2) Guidelines

The AUA/ASRM guidelines recommend against VR for non-palpable varicoceles (statement 26) and also when IVF is indicated due to a female factor (2012 guidelines). The EAU guidelines (10.4.3.3.2) do not recommend VR in men with normal semen analysis and those with a sub-clinical varicocele. However, no exclusions based on any of the other factors are specified.

(3) Discussion

Since a significant proportion of men will not benefit from VR, it is important to individualize the recommendation for VR, based on favorable and unfavorable prognostic factors.

However, there is considerable variation in the clinical factors that the surveyed physicians take into consideration when deciding that VR is unlikely to succeed in a given case. Interestingly, one-fourth of respondents indicated that they would take any chance and would advise surgery despite negative prognostic factors.

The partner's age was considered important by 27.7% of the respondents who suggested that if the female partner's age is >35 years, then they would not want to delay ART and hence would not recommend VR. The AUA/ASRM guidelines (statement 1) state that "maternal age is the strongest predictor of fertility outcome". Therefore, the need for haste is understandable. Similarly, male age >40 years was cited as an exclusion factor by 18.3%. However, a study by Firat and Erdemir [46] showed that age need not be an exclusion factor. The study evaluated outcomes after VR in 293 couples of different ages. TMSC was found to be sig-

nificantly increased in all groups after varicocelectomy ($p<0.05$) and though pregnancy rate after varicocelectomy was higher in group 3 (both partners <35 years old) compared with group 2 (patients ≥ 35 years old and their spouses <35 years old) and group 1 (both partners ≥ 35 years old), the differences were not significant ($p=0.133$). This suggests that even couples with both partners over 35 years of age have a reasonable chance of natural pregnancy after VR, and advanced male age is not a contraindication to VR. A similar conclusion was reached in a study by Hsiao et al [47].

The most common reason (42.2%) for not advising VR was low grade (grade I) of varicocele. Several studies have shown greater improvement and higher pregnancy rates when a higher grade of varicocele was operated. A recent meta-analysis of 20 studies by Asafu-Adjei et al [48], stratified outcomes by varicocele grade and demonstrated that improvements in sperm concentration and overall motility occurred with all grades of varicocele but it was proportional to the grade of varicocele. Thus, the mean sperm concentration improvement in men with grades I, II, II-III and III varicoceles were 5.5, 8.9, 12.7, and 16.0 million sperm/ml, respectively while the mean improvement in the percent of overall motility in men with grades I, II, II-III and III varicoceles was 9.6%, 10.6%, 10.8% and 17.7%, respectively [48].

A significant proportion of respondents listed "follicle stimulating hormone (FSH) above normal" (28% of respondents) or "testes <10 mL" (26% of respondents) as contraindications to VR. While this correlates with a common sense approach that these parameters indicate significant testicular damage and hence improvement after VR is less likely, there is little evidence in the literature to support such a belief. A study by Birowo et al [49] found improvement in sperm retrieval rates after VR in men with NOA across all levels of FSH, while another study showed a reduction in FSH after VR with a correlation between reduction in FSH and an increase in semen parameters [50]. Similarly, while studies have shown an increase in testicular volume after VR in both adolescents [51] and adults [52,53], there is no data supporting the exclusion of VR in men with small testes and OAT.

Only 17.2% of the respondents felt that VR would not benefit men with severe OAT (<1 mill/mL) and would not recommend VR for this group. While several studies have documented the benefit of VR in men with

severe OAT (<5 mill/mL) [54,55], few studies address the possibility of benefit from VR in case of extreme OAT (<1 mill/mL). In a study of 102 men with severe OAT (<5 mill/mL), Enatsu et al [56] reported that 41.1% of men had significant improvement after surgery, but the chances of improvement were greater in men with initial counts of 2–5 mill/mL as compared to those with <2 mill/mL. A study by Dada et al [57] emphasized the need for genetic testing prior to VR in men with extreme OAT.

(4) Expert opinion

There are no robust contra-indications to VR. However, men with very poor baseline sperm parameters (e.g., extreme OAT) and small (grade I) varicoceles are less likely to experience a clinically significant improvement in sperm parameters after VR.

Moreover, couples with advanced maternal age or poor ovarian reserve should be cognizant of the time delay associated with a VR and the unfavorable impact of maternal age on spontaneous pregnancy rates. These couples should consider opting for ART without delay but may consider VR as a simultaneous procedure to improve semen quality for future attempts.

8) Predictors of a successful outcome (pregnancy) after varicocele repair

(1) Survey results

When asked to identify which factors could predict a successful outcome in terms of natural pregnancy after VR, the majority identified higher grade of varicocele, higher pre-operative motile sperm count, larger tes-

ticular volume, lower FSH, and bilaterality of the varicocele as key predictors of a higher chance of benefit (Table 4).

(2) Guidelines

The AUA/ASRM guidelines state that “maternal age is the strongest predictor of fertility outcome” (statement 1) but do not identify any patient or varicocele-related characteristics that predict a greater chance of benefit from VR. The EAU guidelines do mention that a higher grade of varicocele is associated with greater improvement (10.4.3.3.2) and this should be considered while counseling a patient.

(3) Discussion

The female partner’s age is the most important predictor of pregnancy. However, this question focused on factors that would predict maximum improvement in semen parameters and thus improve pregnancy rates.

In a systematic review of parameters that would predict favorable outcomes after VR, Samplaski and Jarvi [58] reported that the best predictor of improved semen parameters, as well as of natural and ART pregnancy rates, were higher pre-operative semen parameters, and that the greatest improvements were seen in men with larger varicoceles. There was some evidence that higher testosterone, larger testes, and younger age were associated with better outcomes. Predictive normograms have also been described [59]. Kamal et al [60] also reported that natural pregnancy rates after VR were much higher if the initial sperm count was >5 mill/mL. If US Doppler study has been carried out, then the presence of continuous reflux predicts a higher chance

Table 4. Predictors of pregnancy after varicocele repair

Q 36: “In your experience, which of the following pre surgery parameters predict varicocele repair success in terms of pregnancy?” (you can choose multiple options)		
Answer	No. of responses	Percentage of respondents
Higher grade of varicocele	355	68.1
Higher total motile sperm count	258	49.5
Larger testes volume	232	44.5
Higher total sperm count	214	41.1
Lower serum FSH level	181	34.7
Bilateral varicocele	176	33.8
Higher serum testosterone level	58	11.1
Other	23	4.4
Total number of respondents	521	

FSH: follicle stimulating hormone.

of improvement [17].

(4) Expert opinion

The greatest improvement in semen parameters and highest chances of natural pregnancy after VR may be expected when the female partner is young, initial semen analysis shows mild to moderate OAT, varicocele is large (grade III) and bilateral, testicular volume and serum FSH are normal, or there is secondary infertility.

5. Technical aspects of varicocele repair

1) Choice of technique, use of magnification, identification of artery

(1) Survey results

The respondents' choice of technique for VR is shown in Fig. 7.

Nearly half (43.2%) of the surgeons reported that they routinely used the operating microscope and 26.0% used magnifying loupes for performing VR. The rest listed a variety of reasons for not using magnifica-

tion (Table 5).

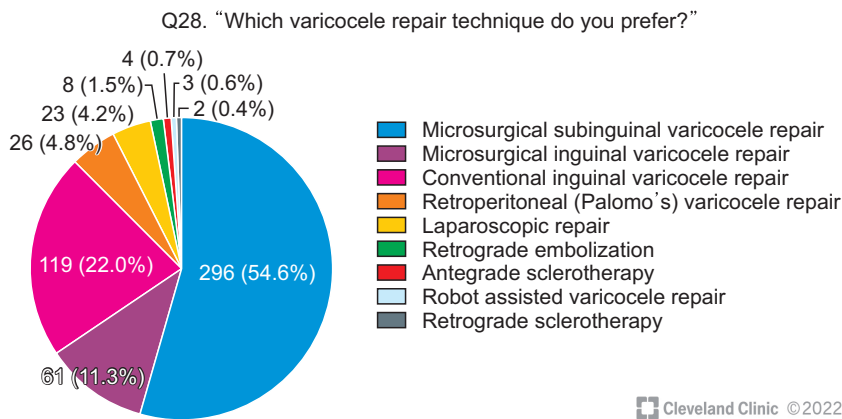
Only 13.4% used an intra-operative Doppler to identify the artery. The majority relied on visual identification using either a microscope (33.1%) or loupes (13.4%); 17.4% claimed to identify the artery without the help of magnification, while 24.4% did not identify the artery and just avoided the area of pulsations.

Only a minority of the survey responders (2.6%) preferred retrograde embolization or antegrade or retrograde sclerotherapy as a primary method for VR.

(2) Guidelines

The AUA/ASRM guidelines recommend “surgical varicocelectomy” (statement 25) and quote the highest success with subinguinal microsurgical varicocelectomy as compared to other surgical techniques.

EAU guidelines state that microsurgical varicocelectomy “is the most effective among the different varicocelectomy techniques” and has the lowest complication and recurrence rates. However, adequate support from RCTs is lacking, and “other techniques are also viable options” (10.4.3.4). Radiological techniques are mini-



Cleveland Clinic ©2022

Fig. 7. Choice of varicocele repair technique.

Table 5. Use of operating microscope for varicocele repair

Q 29: "Do you perform varicocelectomy using an operating microscope?" (you can choose multiple options)		
Answer	No. of responses	Percentage of respondents
Yes, I use it routinely	234	43.2
I use magnifying loupes	141	26.0
I don't have microscope	136	25.1
I feel comfortable with naked eye	79	14.6
I don't have microsurgical skills	61	11.3
I feel that a microscope doesn't make much difference in outcomes	38	7.0
Total number of respondents	542	

mally invasive and are widely used but have higher recurrence rates.

(3) Discussion

There are many options for surgical VR, each having its potential advantages and disadvantages. One meta-analysis found no specific VR technique to be the most effective in improving fertility [61], while another one reported the highest spontaneous pregnancy rate following sub-inguinal microsurgical VR (41%) *vs.* retroperitoneal (37%) *vs.* inguinal (26%) *vs.* laparoscopic transperitoneal (26%) *vs.* percutaneous embolization (36%) [62].

Techniques utilizing optical magnification optimize the surgeon's ability to preserve the testicular artery and lymphatic channels while ligating all veins to minimize the risk of hydrocele formation or varicocele recurrence. Preservation of the gonadal artery during VR is considered important, and techniques that facilitate this include optical magnification with an operative microscope or operating loupes, administering papaverine locally, using a micro-Doppler [63], or a combination of the above.

Almost one-fourth (24.4%) of the responders do not identify the arteries but just avoid the area of pulsations. This may lead to an increased possibility of missing surrounding veins and a higher risk of varicocele recurrence.

In this context, microsurgical VR is considered the gold standard procedure having the least postoperative complications and lowest recurrence rate [64], and was the technique used by more than half of the respondents. The microsurgical subinguinal approach has the further advantage of a short postoperative recovery compared to the inguinal approach because no muscle or fascia is incised during the procedure. However, the number of veins and arteries encountered in the subinguinal approach is more than in the inguinal approach, rendering dissection more challenging [65]. In adolescents, use of the microscope makes identification of the tiny testicular arteries easier.

Varicocele treatment by venous embolization or antegrade sclerotherapy [66] was not popular with the respondents, but this may reflect a geographical bias. Percutaneous embolization of varicoceles will result in less post-procedural pain than surgical repairs. However, interventional access to the internal spermatic veins (especially the right side) may not be possible due to

technical challenges in up to 20% of cases [67], and recurrence rates range from 4% to 27% (EAU guidelines 10.4.3.4).

(4) Expert opinion

Microsurgical subinguinal VR is the standard of care because it is associated with lower complication and recurrence rates, and possibly higher improvement in semen parameters. However, it is technically demanding and needs access to an operating microscope. Not all surgeons are trained in the technique but those who do VR regularly are strongly encouraged to acquire microsurgical skills to be able to perform subinguinal microsurgical VR. Meanwhile, surgeons should utilize the technique that they are competent in and most comfortable with.

2) Ligation of additional veins outside the spermatic cord

(1) Survey results

The majority of respondents ligate the external spermatic or cremasteric veins (always, 33.9%; often, 47.8%).

In contrast, the majority do not ligate the gubernacular veins (never, 25.3%; rarely, 29.3%). Only 15.7% always ligate the gubernacular veins while 16.1% ligate them when operating for recurrence, and 13.7% ligate if there is a grade III varicocele.

(2) Guidelines

There are no specific comments on the need to ligate cremasteric or gubernacular veins.

(3) Discussion

Ligation of the external spermatic or cremasteric veins has been popular for a long time [68], and most respondents reported ligating them during VR. On the other hand, the majority of respondents disputed the suggestion that the gubernacular veins should be ligated.

The concept of ligating the gubernacular veins was proposed by Goldstein in 1992 [69] based on earlier published studies on varicocele recurrence. In a case series of 640 men who underwent microsurgical VR with gubernacular vein ligation, he reported a low recurrence rate of 0.6%. However, there was no control group and the low recurrence rate may have been due to the microsurgical cord dissection. A subsequent paper, from

the same institution, which included a control group of men whose testes were not delivered showed similar recurrence rates and improvement in semen parameters in both groups [70]. Similarly, a controlled randomized study by Huo et al [71] found no difference in either recurrence or improvement rates, but observed that gubernacular vein ligation increased the operating time by a mean of 6 minutes and increased the incidence of scrotal edema and testicular engorgement (raising the suspicion that ligation of gubernacular veins resulted in occlusion of normal drainage channels).

On the other hand, a randomised, controlled study by Allameh et al [72] found lower recurrence, greater improvement in sperm motility, and no increase in the complications, in the group that underwent gubernacular vein ligation.

(4) Expert opinion

Ligation of the external spermatic veins is easy, adds minimal operating time, may reduce recurrence, and can be done routinely. Gubernacular vein ligation requires additional steps and a larger incision to deliver the testis. Since the benefit of this extra step is controversial, it should be deemed optional, and as suggested by the survey respondents may be omitted entirely or limited to selected cases of grade III or recurrent varicocele.

3) Unilateral versus bilateral repair

(1) Survey results

In the presence of a left clinical varicocele, 63.8% of respondents would operate the right side only if a clinical varicocele was present on the right side, while 18.8% would correct the right side even if it was subclinical. Besides, 17.4% stated that they did not perform simultaneous bilateral repair.

(2) Guidelines

While both EAU and AUA guidelines are clear that subclinical varicoceles should not be operated upon, there is no specific recommendation regarding a right-side subclinical varicocele when there is a left-sided clinical varicocele.

(3) Discussion

A recent systematic review favored bilateral VR over

unilateral VR when there are bilateral clinical varicoceles [73]. However, the choice of procedure becomes less clear when the varicocele on the right side is equivocal or subclinical.

A large meta-analysis of 4 randomized controlled trials (RCTs) with 637 cases compared outcomes following unilateral or bilateral VR in men with left-clinical and right-subclinical varicoceles [74]. The authors reported no significant difference in the increase in sperm concentration and sperm motility in the two groups but the odds ratio for spontaneous pregnancy rate was 1.73 favoring bilateral ligation. The authors concluded that bilateral ligation may be superior but more RCTs were needed.

A prospective, randomized controlled study by Sun et al [75] compared the outcomes at one year following unilateral VR (179 men) *versus* bilateral VR (179 men) in infertile men with left clinical and right subclinical varicoceles. Both groups showed improvement but the increase in sperm concentration, progressive motility, and morphology were significantly greater, and pregnancy rates were higher in the bilateral group (42.5% *vs.* 26%).

On the other hand, an earlier, smaller study on 104 men found equal improvement in semen parameters and pregnancy rates following unilateral or bilateral VR in this group of men [76].

(4) Expert opinion

When there is a bilateral clinical varicocele then VR should be performed bilaterally.

However, there is controversy in the medical literature regarding concomitant repair of a subclinical right varicocele at the time of left clinical VR, and a definitive recommendation cannot be made. Taking into consideration the general injunction against VR for a subclinical varicocele, the consensus of expert opinion recommends against VR of the right subclinical varicocele in this situation.

If the clinician is considering bilateral ligation for such a case then it should be a shared decision between the surgeon and patient with the understanding that the benefit of a bilateral procedure is uncertain, and involves extra operative time and an additional incision.

4) Sperm cryopreservation prior to varicocelectomy

(1) Survey results

Opinion was divided on the need for prior sperm cryopreservation. Overall, 32.5% of the clinicians never recommend it, while 32.5% recommend it when there is severe OAT, and 25.5% consider cryopreservation prudent when operating on a solitary testis.

(2) Guidelines

There are no recommendations on when sperm should be cryopreserved before VR.

(3) Discussion

The spermatic artery can be damaged during VR, especially when utilizing non-magnified surgical techniques, and this may further jeopardize an already impaired spermatogenesis with significant consequences if the original sperm count was already very low [75]. Further, men with severe OAT may progress naturally to azoospermia [77], and if that happens after VR, then the VR procedure may be blamed. Not all men undergoing VR will have an improvement in their semen parameters, and sometimes there may be deterioration which may even result in azoospermia in men who had extreme OAT pre-operatively [78]. Hence, it seems prudent to advise sperm cryopreservation before VR in men with extreme oligozoospermia.

Further, testicular atrophy can occur rarely after VR [79], and while this may not have much of an impact if there is a normal contralateral testicle, it would be disastrous in a man with a solitary testicle. Therefore, it would be safer to cryopreserve sperm before VR on a solitary testis.

(4) Expert opinion

Sperm cryopreservation prior to VR is not recommended as a routine procedure since the additional costs are not warranted. However, in keeping with the survey findings, it should be considered when there is a solitary testis or extreme OAT (<100,000/mL). Sperm cryopreservation may also be considered in men with varicocele who have severe OAT and progressively declining semen parameters but are delaying VR.

5) Testicular biopsy at the time of varicocele repair for oligoasthenoteratozoospermia

(1) Survey results

The vast majority (94.1%) of respondents do not perform a testicular biopsy when VR is being done for OAT.

(2) Guidelines

The guidelines do not make any recommendation for testicular biopsy when VR is done for OAT.

(3) Discussion

While it was a practice in the past to do a testicular biopsy at the time of VR for “prognostic purposes”, it is not recommended currently as there is no evidence that the biopsy results influence further management [80], and it may lead to the formation of antisperm antibodies which may affect sperm parameters later on.

(4) Expert opinion

Testicular biopsy is not indicated at the time of VR for management of OAT.

Men who are undergoing VR for infertility, and also have bilateral testicular microlithiasis, may be offered a simultaneous testicular biopsy to look for germ cell neoplasia *in situ* (GCNIS) and future risk of testicular

Table 6. Doppler ultrasound evaluation for follow-up after varicocele repair

Q 42: “Do you perform Doppler or ultrasound evaluation after varicocele repair?” (you can choose multiple options)		
Answer	No. of responses	Percentage of respondents
If physical examination suggests residual varicocele	216	41.5
If semen parameters have not improved	157	30.1
If patient is not relieved of pain	121	23.2
Never	113	21.7
In every case	77	14.8
Total number of respondents	521	

germ cell tumor (TGCT) (EAU guidelines 10.4.2.2).

6. Follow-up and recurrence after varicocele repair

1) Post varicocele repair follow-up with ultrasound or Doppler ultrasound

(1) Survey

There was considerable divergence of opinion on follow-up, with 14.8% (77/521) advising post-VR US routinely for all patients, and 21.7% (113/521) never asking for post-op US. Others advised it conditionally for reasons listed in Table 6.

(2) Guidelines

The AUA/ASRM guidelines (statement 21) recommend against routine scrotal US to look for varicocele; there is no specific recommendation about the use of US to monitor follow-up or look for recurrence.

The EAU guidelines (10.4.3.2) recommend scrotal Doppler US to look for residual/recurrent varicoceles if there is no improvement in semen parameters after VR.

(3) Discussion

Routine Doppler US follow-up after VR can act as a quality control measure, helping the clinician to confirm that there is no residual varicocele (failed VR) and that the artery is intact. However, this has several disadvantages apart from the additional cost and time spent. Often a post-VR Doppler US may detect a varicocele that is not clinically significant, and this could lead to a false diagnosis of failed surgery. In a

small study on adolescents post-VR, there was marked variation between clinical and US findings, with US reporting residual/recurrent varicocele in 12/15 cases [81]. When US detects a residual “subclinical” varicocele following VR, it could lead to unjustified patient disappointment and anxiety, and may cause a management dilemma.

Post VR Doppler US has been recommended in the EAU guidelines when there is no improvement in semen parameters and a recurrence is suspected. However, as discussed above, it is not clear whether the US detected recurrence is of significance if the clinical examination is normal. A small-study [82] reported a 60% recurrence 5 years after VR when the men were examined with Doppler US, supporting the suggestion that Doppler US may over-estimate post VR recurrence. On the other hand, often there is thickening of the spermatic cord due to thrombosed veins after VR and a Doppler US study can confirm whether there is significant reflux in the thickened cord.

(4) Expert opinion

Routine scrotal Doppler US after VR is not recommended, though some surgeons may choose to do it to monitor the technical success of their VR procedure.

Repeat US may be considered if there is no improvement in semen parameters, or non-resolution of pain, and there are findings on physical examination suggestive of residual or recurrent varicocele.

2) Post-operative complications

(1) Survey results

A number of complications of varicocele surgery

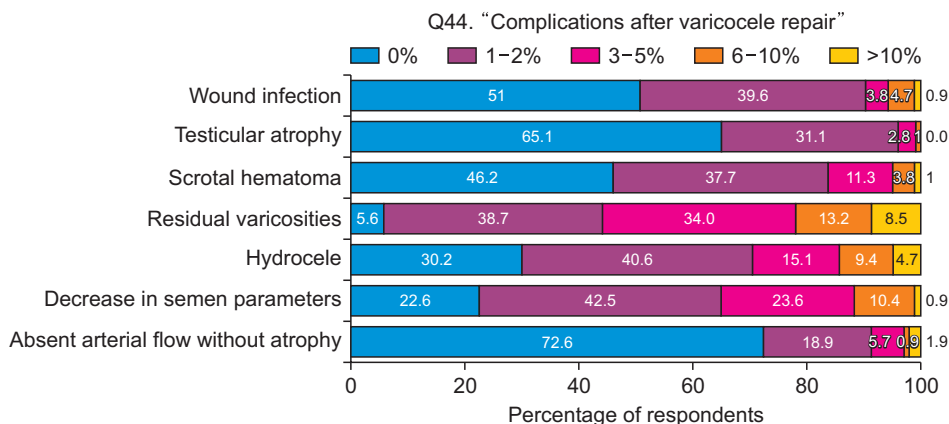


Fig. 8. Frequency of complications after varicocele repair.

were reported by the respondents but the overall incidence was less than 10% (Fig. 8).

(2) Guidelines

The recent AUA/ASRM guidelines do not comment on post-VR complications, but the 2011 guidelines warn that laparoscopic VR does have some risk of major intraperitoneal complications. The EAU guidelines (10.4.3.4) state that microsurgical varicocelectomy is the most effective with the least complications.

(3) Discussion

The most common reported complications were hydrocele and residual varicocele, both of which are minimized by the use of magnification to preserve lymphatics while ligating all tributaries of the spermatic vein.

A fall in sperm count after treatment was also reported by a fair number of surgeons. This may be due to spontaneous variation in semen parameters or may be due to an undetected damage to the testicular artery which did not result in atrophy but compromised the testicular function. This would be avoided by the use of magnification and other intra-operative measures to preserve the testicular artery during surgery.

Spermatic vein embolization would be free of surgical complications and risk of damage to the testicular artery. However, the technique demands interventional radiologic expertise, is associated with a higher failure rate, and has potential serious complications including vascular perforation, coil migration leading to renal vein thrombosis, and thrombosis of pampiniform plexus [81].

(4) Expert opinion

Subinguinal microsurgical varicocelectomy is associated with the lowest complication rate and is the gold standard for VR. However, surgeons should adhere to the technique that they are comfortable with since a poorly done microsurgical procedure will do more harm than good. Nevertheless, to minimize the complications rate, obtaining formal microsurgical training is highly advisable for surgeons who do VR regularly.

3) Recurrence after varicocele repair

(1) Survey results

The majority of respondents reported that varicocele recurrence occurred within the first year (35.1%) or be-

tween the first and second year (41%).

The main factors listed as the cause of recurrence were surgeon's experience (61%) and/or surgical approach (51.7%), indicating missed tributaries of the spermatic vein as the main cause. However, 29.8% listed cremasteric veins, and 23.2% named gubernacular veins as possible causes of recurrence.

Opinion on the management of recurrence was widely divided. While 14.6% recommended repeating VR for all recurrences, 17.1% said that they do not usually suggest treatment of a recurrent varicocele.

The remaining respondents made their decision based on the outcome of the first surgery but expressed contrasting viewpoints. While 27% would suggest a repeat procedure if there had been no improvement after the first procedure, 28.5% would suggest repeat procedure only if there had been significant improvement after the first procedure followed by a gradual decline, and an additional 12.7% agreed that they would not operate if there had been no benefit after the first surgery.

The choice of procedure also varied widely. For recurrence after a subinguinal microsurgical varicocelectomy, one-third (34.9%) of the surgeons opted for a repeat procedure at the subinguinal level while 28.4% opted to go higher (inguinal, 14.5%; Palomo, 8.7%; laparoscopic, 5.2%). Besides, 15% recommended venographic occlusion while 21.8% opted not to treat the recurrence.

(2) Guidelines

The EAU guidelines (10.4.3.4 – Table 41) state that inguinal/subinguinal microsurgical VR has the lowest recurrence rate compared to other surgical techniques, and that radiological occlusion procedures have significantly higher rates of recurrence. The guidelines (10.4.3.2) recommend Doppler US to look for recurrent varicocele if there is no improvement after VR but do not comment on the likelihood of benefit from VR for recurrent varicoceles.

(3) Discussion

There is a wide range in the incidence of recurrence reported based on surgical approach, technique, duration and method of follow-up [83]. The recurrence of a varicocele is disturbing to both the surgeon and the patient. An early recurrence is a residual varicocele that has enlarged again.

Missed tributaries of the spermatic vein are the pri-

mary cause of recurrence and therefore microsurgical VR has the lowest recurrence rate since small tributaries can be identified and ligated [84]. The role of the cremasteric and gubernacular veins is still debated. Franco et al [85] performed left iliac vein venographic studies of 73 men with primary or recurrent varicoceles and failed to demonstrate reflux from the extra-funicular veins into the pampiniform plexus. They observed that the cremasteric vein was always continent even when grossly dilated, and concluded that the cremasteric vein has a limited, if any, role in the pathogenesis of varicocele or its recurrence. However, the majority of survey respondents reported ligating the cremasteric veins (see section 5.2.1).

The diverse practices of the survey respondents would suggest that the benefit from re-operating a recurrent varicocele is unclear. However, a systematic review [83] of men undergoing VR of recurrent varicocele by surgery, retrograde embolization, or antegrade sclerotherapy reported high rates of success in treating the recurrence and highly significant improvement in semen parameters.

(4) Expert opinion

Care should be taken to ligate all tributaries of the spermatic vein to prevent a recurrence. When cremasteric veins are easily accessible (as in low approaches) they should also be ligated. Routine delivery of the testes to ligate gubernacular veins is not recommended (see section 5.2.3).

Surgery for recurrent varicocele may be advised but with a cautionary note about chances of improvement in semen quality. When the previous VR was by a high approach, then the repeat surgery should be at the sub-inguinal or inguinal level. When the primary surgery was sub-inguinal, then repeat surgery at a lower level can be done but would be significantly more difficult, and hence venographic occlusion, or an inguinal approach, could be considered.

7. Outcomes

1) Parameters of a successful outcome

(1) Survey results

In response to a question as to what the respondents considered the main parameter for determining whether the VR had a successful outcome, only a

small percentage stated that increased pregnancy rates (16.3%) or an increase in live birth rate (9.8%) should be the primary outcome measure.

About 58.7% stated that a significant improvement in semen parameters, even if it did not reach normal reference values, would be considered a successful outcome, while 15.2% would consider the VR a success only if the semen parameters improved to normal.

The majority (73.9%) asked for the first post-operative semen report at 3 months, and 19% chose to wait till 6 months, while a few asked for it earlier or later than 3–6 months.

(2) Guidelines

Both AUA/ASRM and the EAU guidelines comment on VR outcomes in terms of both semen parameters and pregnancy rates. The EAU guidelines also state that VR reduces SDF and improves OS.

(3) Discussion

While Cochrane reviews and systematic reviews on the efficacy of VR emphasize spontaneous pregnancy rates and live birth rates [7] as the important outcome measures, the majority of clinicians responding to this survey considered VR successful if semen parameters increased significantly. This may reflect the fact that pregnancy depends on many factors, both male and female, and that the role of VR is to improve one of these factors. Also, VR may help to improve ART outcomes. The counter-argument is that if the live birth rate is not changed, then the improvement brought about by VR is not of significance.

(4) Expert opinion

Patients who undergo VR benefit in terms of improvement in semen parameters and sperm function. However, the impact of this on pregnancy and live birth rates may be limited as they depend on many other factors. Thus, although the improvement in semen parameters after VR may not result in a proportionate increase in live birth rates, improvement in the semen parameters is valid as a primary outcome measure of VR. When sufficient data is available from RCTs, then live birth rates can be considered as the primary outcome measure.

Also, improvement in semen parameters may allow couples to succeed with lower levels of treatment, such as ovulation induction cycles or IUI rather than IVF.

Q38. "When you counsel patients on the chances of clinically significant improvement in semen parameters following varicocele repair, what percentage do you usually quote?"

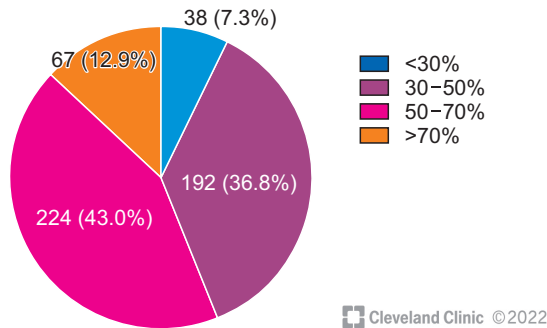


Fig. 9. Chances of clinically significant improvement in semen parameters after varicocele repair.

Thus, improved semen parameters after VR will be a useful outcome for these patients.

2) Chances of benefit after varicocele repair

(1) Survey results

When asked about how they counsel their patients about the chances of benefit from VR, the majority of clinicians quoted moderately optimistic figures with 43.0% of respondents offering a 50% to 70% chance of significant improvement in semen parameters (Fig. 9), and 59.9% clinicians advising a 30% to 50% chance of spontaneous pregnancy (Fig. 10).

(2) Guidelines

The AUA/ASRM guidelines (statement 25) quote an estimated pregnancy rate of 52% (95% confidence interval [CI], 24%–83%) after subinguinal microsurgical VR. The EAU guidelines (10.4.3.3.2) quote two meta-analyses to suggest that VR improves chances of pregnancy with a combined OR of 2.39 (95% CI, 1.56–3.66)–4.15 (95% CI, 2.31–7.45), with time to improvement up to two spermatogenic cycles and time to spontaneous pregnancy of 6 to 12 months.

(3) Discussion

Several meta-analyses have been published evaluating the benefit of VR on semen parameters and pregnancy rates, and report an improvement in semen parameters and pregnancy rates that are in agreement with the chances that are counseled by the survey respondents [86,87].

Q39. "When you counsel patients on the chances of spontaneous pregnancy following varicocele repair, what percentage do you usually quote?"

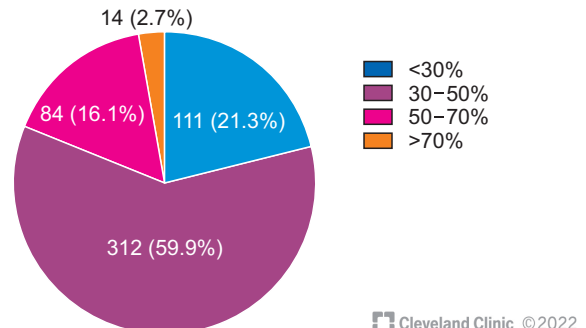


Fig. 10. Chances of spontaneous pregnancy after varicocele repair.

(4) Expert recommendation

Patients can be counseled that there is a 50%–70% chance of significant improvement in their semen parameters after VR, and a 30% to 50% chance of a natural pregnancy. However, there is also a need to better define the expected outcomes of VR and provide a more precise, individualized prognosis based on clinical findings, semen parameters, hormonal levels, prognostic biomarkers, duration of infertility, and the couple's age. A validated prognostic model would be helpful.

3) Time to maximum improvement after varicocele repair

(1) Survey results

There exists considerable variation in the expected time to maximum improvement. About 34% of clinicians opted for 3–6 months, 29.2% for 6 to 9 months, and 26.7% for 9 to 12 months. Lastly, 8.6% suggested waiting for more than 12 months.

(2) Guidelines

Both AUA/ASRM and EAU guidelines suggest that improvement should be expected within 1-2 spermatogenic cycles, that is within 3 to 6 months, and recommend semen testing every 3 months up to one year.

(3) Discussion

The expected time to maximum improvement is clinically important since lack of improvement by that time period would be an indication of failure of benefit from the procedure, and the need to proceed with ART. Waiting too long would result in unnecessary delay in

the next step.

A few studies have examined the time to maximum improvement after VR. The majority of these studies suggest that improvement in semen parameters occurs by the first 3 months after varicocelectomy with no further significant improvement seen afterward [88-90]. Machen et al [91] stratified the improvement in sperm count by time after VR and reported that 78.8% had improvement at 3 months, 16.9% at 6 months, and 4.2% beyond 6 months. When specifically evaluating men with severe oligospermia pre-operatively, with TMSC of <5 million/mL, the largest improvement may be seen between 3–6 months post-operatively [92].

(4) Expert opinion

Most of the evidence suggests that if improvement occurs it will happen in the first 3 months after surgery which corresponds with the spermatogenesis cycle. However, men with severe OAT may take up to 6 months for maximal improvement. If improvement in semen parameters has not occurred by 12 months post-operatively, then it is not likely that there will be any improvement. On the other hand, examining the semen earlier than 3 months after VR may lead to an erroneous assessment of the outcomes.

8. Subclinical varicocele

1) Survey results

The survey reveals a contradiction in the clinicians' approach to subclinical varicoceles. Earlier (section 2.1.1), most respondents have stated that they relied on physical examination to diagnose a varicocele. However, when asked how often they did US to look for a varicocele in a man with OAT, even when there was no

clinical varicocele, 26.5% answered "always", 23.9% answered "usually", and 32.5% asked for it "occasionally". Thus, only 17.1% abided by the guidelines recommendation that US is not indicated to look for a subclinical varicocele.

Along similar lines, when asked when they would repair a subclinical varicocele, only 44.7% replied "never". The remaining majority of clinicians were willing to recommend VR, even for subclinical varicoceles, for a variety of clinical indications (Table 7).

The frequency of performing VR in patients with subclinical varicocele tended to be higher among responders with up to 10 years of clinical experience as compared to those with more than 10 years of experience (212/267 [79.4%] vs. 214/307 [69.7%]; $p=0.048$). However, the difference in the proportion of responders with and without sub-specialty training in infertility that performed VR in patients with subclinical varicocele was not significant (220/297 [74.1%] vs. 206/277 [74.4%]).

On the other hand, the approach to the management of a grade I varicocele was different. When asked about the management of bilateral clinical grade I varicocele in a man with moderate OAT, half of the respondents stated that they would not recommend surgery (22.5%, never; 22.1%, rarely) and 20% would recommend surgery only occasionally (in 10%–25% cases). Only one-fourth of clinicians would routinely advise surgery in this situation (usually, 16.4%; always, 19%).

2) Guidelines

The AUA/ASRM (statement 26) and EAU (10.4.3.3.2) guidelines are unequivocal in recommending against the treatment of a subclinical varicocele.

Table 7. Varicocele repair for subclinical varicocele

Q 50: "When do you repair a bilateral subclinical varicocele?" (you can choose multiple options)		
Answer	No. of responses	Percentage of respondents
Never	230	44.7
If OAT has not improved with medical therapy	180	35.0
In all infertile men with a subclinical varicocele	106	20.6
Chronic orchalgia	80	15.6
If semen parameters are normal but SDF is elevated	73	14.2
Total number of respondents	514	

OAT: oligoasthenoteratozoospermia, SDF: sperm DNA fragmentation.

3) Discussion

There appears to be considerable confusion and diversity of opinion and practice when it comes to subclinical and grade-I clinical varicoceles.

Thus, half of the clinicians do not believe that correcting a grade-I varicocele is of benefit and usually do not recommend its repair. However, paradoxically, when faced with the frustration of having nothing to offer a man with idiopathic OAT, the majority of clinicians succumb to “clutching at straws” and ask for an US even though there is no suspicion of varicocele on examination, and would offer VR if a varicocele is detected on US.

Though there are studies claiming benefit from repair of subclinical varicoceles [93,94] the consensus, as reflected in the AUA and EAU guidelines, is that subclinical varicoceles should not be repaired, and therefore US should not be performed to look for a varicocele when there is no clinical suspicion of a varicocele.

Correlating benefit from surgery with grade of varicocele, a recent meta-analysis of 20 studies involving 2001 patients, showed that while there was a statistically significant improvement in semen parameters after VR for all grades of varicocele, the improvement

after surgery for grade-I varicoceles was small in magnitude, and clinically significant improvement was more likely when the varicocele was large (grade II-III or III) [48].

4) Expert opinion

Based on current evidence, VR for subclinical varicoceles is not recommended, and VR for grade I varicoceles may be considered after discussing the lower likelihood of significant benefit.

However, the practice patterns revealed by this survey suggest a need for a reassessment of the evidence on the utility, or otherwise, and of correcting subclinical and grade-I clinical varicoceles (since the boundary between the two is often blurred) so that clinicians are empowered to take an informed and firm stand on whether or not to treat these cases.

9. Varicocele and non-obstructive azoospermia

1) Survey results

Half of the respondents do not favour VR in men with NOA (never, 15.5%; in <10% of cases, 34.9%), and 16.3% recommend it only in 10%–25% of their azoospermic men. However, one-third of respondents believe that VR has a useful role in men with NOA with 7.5% recommending VR in 25%–50% of their patients, and 25.9% performing VR in >50% of their azoospermic men (Fig. 11).

However, there is some discrepancy in responses to a related question in which 58.6% of respondents said they would offer VR prior to microdissection testicular sperm extraction (microTESE) (Fig. 12). This is probably a reflection of the confusion that surrounds the role of VR in NOA.

The respondents were equally divided on the role of

Q52. “How often do you perform varicocelectomy in a man with a clinical varicocele and non-obstructive azoospermia?”

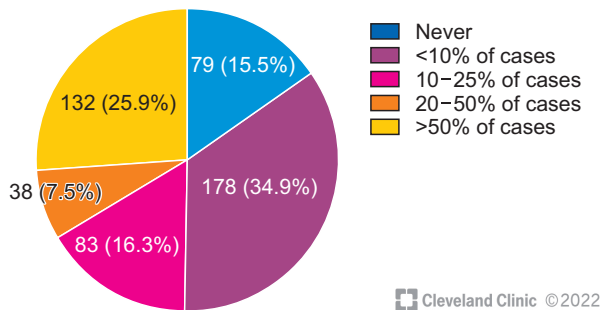


Fig. 11. Frequency of varicocele repair in a man with NOA. NOA: non-obstructive azoospermia.

Q51. “What is your approach in patients with clinical varicocele and non-obstructive azoospermia?”

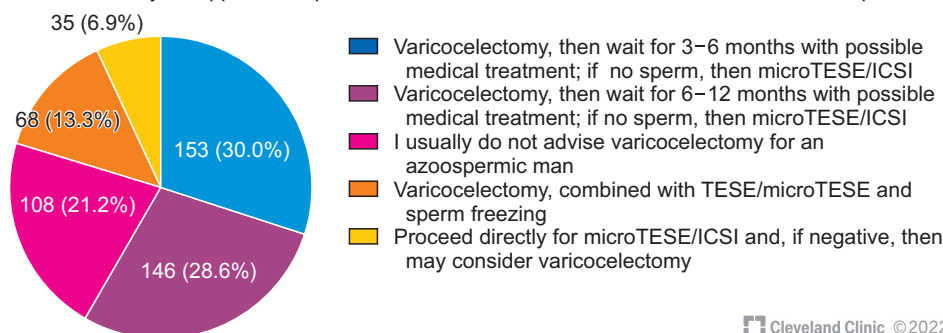


Fig. 12. Management of patients with clinical varicocele and NOA. NOA: non-obstructive azoospermia, TESE: testicular sperm extraction, ICSI: intracytoplasmic sperm injection.

Table 8. Testicular biopsy during varicocele repair for a man with non-obstructive azoospermia

Q 54: "Do you perform testicular biopsy at the time of varicocele repair for a man with non-obstructive azoospermia?" (you can choose multiple options)		
Answer	No. of responses	Percentage of respondents
Never	152	29.8
Rarely	70	13.7
In select patients	131	25.7
In most cases	108	21.2
For cryopreservation if sperm are found	104	20.4
For prognosis	46	9.0
To rule out ITGCN	32	6.3
Total number of respondents	510	

ITGCN: intratubular germ cell neoplasia.

a diagnostic testicular biopsy before VR in men with NOA to determine whether VR would be of benefit. For example, 16.9% recommend a prior biopsy in most of their cases, and 28.4% recommended it in selected cases. However, the other physicians recommended it only rarely (19.6%) or never (35.1%).

More than half the respondents perform a testicular biopsy at the time of VR in most, or selected patients, with the goal of cryopreserving sperm, establishing prognosis, and ruling out ITGCN (intratubular germ cell neoplasia) (Table 8).

2) Guidelines

AUA/ASRM guidelines (statement 27) states, "the couple should be informed of the absence of definitive evidence supporting VR prior to ART".

The EAU (10.4.3.3.3) guidelines state that VR in men with NOA may result in the appearance of sperm in the ejaculate (20.8% to 55%) and is associated with improved surgical sperm retrieval rates (OR, 2.65; 95% CI, 1.69–4.14). However, it cautions that the evidence is based on observational studies and advises that "the risks and benefits of VR must be discussed fully with the patient with NOA and a clinically significant varicocele".

3) Discussion

The controversy over the role of VR in men with NOA is reflected in the wide divergence in practices reported by the survey respondents.

Despite several meta-analyses [95-97] showing that a percentage of men with NOA ranging from 34% to 43.9% will have appearance of a few sperms in the ejaculate after correction of a clinical varicocele, the

survey reveals a reluctance on part of the majority of respondents to consider VR in men with NOA. There could be several reasons for this. Firstly, in almost all cases the sperm count achieved is very low, and ICSI is still needed [98], and sometimes the appearance of sperm is only transitory [99,100]. Further, a major criticism of these studies is that none of them are controlled and the appearance of sperm in these men may be due to spontaneous variation and not be due to the VR (AUA/ASRM guideline statement 27). A recent study showed that 23.9% of men diagnosed as azoospermia were found to have rare sperm in the ejaculate when tested with additional centrifugation and staining with nuclear fast picroindigocarmine [101].

Men with NOA are a very heterogeneous group with varying testes size, hormone levels, grades of varicocele, and presence of other etiological factors; since few studies have addressed these variables prospectively the selection of NOA patients for VR remains a matter of personal belief and choice. Also, an increasing number of genetic mutations are being identified as causes of maturation arrest [102] and VR would be unproductive in these cases.

Some support for correcting a varicocele in this group comes from studies that have shown higher sperm retrieval during microdissection TESE if the varicocele has been corrected earlier [103,104] and a meta-analysis showed a strong trend towards improved live birth rates following VR (OR, 2.208; p=0.052) [44].

Studies have shown that testicular histopathology has a predictive value in NOA with men who have late maturation arrest or hypospermatogenesis being the most likely to have sperm in the ejaculate after VR [99],

However, this survey shows that clinicians are divided in their opinion on doing a biopsy either prior to or during VR in these cases.

4) Expert opinion

There is limited and controversial evidence supporting VR in men with NOA. Hence, the decision to recommend or not recommend VR for NOA is left to the discretion of the clinician. When it is being offered (in men with large varicoceles, non-atrophied testes, no genetic or known cause for testicular failure) there should be a detailed discussion of the prognosis. If sperm appear in the ejaculate after VR, sperm cryopreservation should be considered since relapse of azoospermia has been reported [99].

At centers performing needle testis biopsy, one approach could be to take a couple of percutaneous biopsies before considering VR: one biopsy can be sent for histopathology and another to the IVF laboratory. If the histology is favorable (late arrest or hypospermatogenesis), then VR can be recommended since chances of benefit are higher; if sperm are found in the IVF laboratory then these can be cryopreserved and the couple can proceed for ICSI.

If VR is opted for without doing prior testicular biopsy, the biopsy may be done as an optional procedure at the time of VR to establish prognosis, rule out premalignant state, and to check for sperm. If sperm are found they can be cryopreserved and the couple may proceed for ICSI without delay.

There is a need for controlled studies that assess outcomes after VR in well-defined subgroups of men with NOA.

LIMITATIONS OF THIS STUDY

While this is the first global survey of this nature, it has several limitations. The survey was conducted in English and this may have restricted participation by clinicians from predominately non-English speaking regions and countries. The survey was distributed through a global group of experts experienced in varicocele management rather than to all male infertility specialists, which could have created a bias in selection or exclusion of those answering the survey. There is a preponderance of responses from some countries (Turkey, Egypt), while there is marked under-representation from some large countries (Russia, China).

Since the total number of invitations to participate in the survey is not known, we are unable to calculate the denominator to the response rate. However, 574 responses received from 59 countries provide a valid and comprehensive perspective of global practices. Though the questionnaire used is not a validated one, it was developed from 382 questions submitted by 60 uro-andrologists from 23 countries and thus is representative of global clinical concerns.

Despite these limitations, the authors feel that the survey findings address many of the important issues about the diagnosis, treatment, and expected outcomes of infertile men with varicoceles. It also raises important questions for future clinical trials to improve and standardize guidelines for the management of these patients.

CONCLUSIONS

The questionnaire used for this survey has been created from questions raised by a large, international group of clinicians, and thus reflects the real-life, practical concerns of physicians dealing with male infertility and varicocele.

The survey responses represent the opinions and practices of 574 clinicians from 59 countries and reveal a marked diversity in all aspects of varicocele management. The survey highlights several areas where there is inconclusive data and the need for more research, and also identifies numerous lacunae in the management guidelines issued by professional bodies (EAU, AUA, ASRM), which need to be addressed in future guidelines.

Besides, this survey serves the useful purpose of allowing clinicians to compare their practices with those of their peers, and against recommended guidelines and the latest research findings, and thus rethink some of their own practices and clinical protocols. This survey invites clinicians to ponder over what they know, what they do, where they go wrong, and what they should do.

Finally, professional societies can survey their membership using such questionnaires to assess the extent to which their guidelines are being followed and to identify areas of dispute or confusion where further clarifications are needed.

Conflict of Interest

The authors have nothing to disclose.

Funding

This research was supported by the American Center for Reproductive Medicine, Cleveland Clinic (Project Number: IF100066).

Acknowledgements

Authors are thankful to the artist Sarah Rolitsky, from the Cleveland Clinic's Center for Medical Art & Photography for her help with the illustrations. We would like to acknowledge all the members of Global Andrology Forum: Abderrazak Bouzouita, Abdullah Alarbid, Ahmed El-Sakka, Ahmed M. Harraz, Ahmed Shokeir, Ahmet Ascı, Ahmet Gudeloglu, Akira Tsujimura, Ala'a Farkouh, Aldo E. Calogero, Amarnath Rambhatla, Amin Bouker, Amr El Meliegy, Ana Puigvert, Andrea Crafa, Aram Adamyan, Arif Kalkanli, Armand Zini, Armen E. Avoyan, Ashok Agarwal, Ates Kadioglu, Ayad Palani, Aykut Baser, Azin Aghamajidi, Balantine Eze, Bambang Sasongko Noegroho, Basuki Purnomo, Berk Hazir, Bircan Kolbaşı Erkan, Birute Zilaitiene, Carlo Giuloni, Chak-Lam Cho, Christopher C.K. Ho, Ciro Salzano, Colin Teo, Damayanthi Durairajanayagam, Daniel Suslik Zylbersztejn, Davor Jezek, Deniz Kulaksiz, Dimitrios Kafetzis, Dong Sup Lee, Doron Stember, Dung Mai Ba Tien, Edmund Ko, Edoardo Pescatori, Edson Borges, Ege Can Serefoglu, Emine Saïs-Hamza, Emrullah Sogutdelen, Eric Chung, Eric Huyghe, Erman Ceyhan, Ettore Caroppo, Evangelini Evgeni, Fabrizio Castiglioni, Fahmi Bahar, Faisal Alhajeri, Fatih Gokalp, Federica Finocchi, Florence Boitrelle, Fotios Dimitriadis, Francesco Lombardo, Franco Gadda, Fulvio Colombo, Gede Wirya Kusuma Duarsa, George Tsangaris, Germar-Michael Pinggera, Gian Maria Busetto, Giancarlo Balercia, Gianmaria Salvio, Gianmartin Cito, Gideon Blecher, Giorgio Franco, Giorgio Ivan Russo, Giovanni Liguori, Giovanni M. Colpi, Gokhan Calik, Gökhan Çeker, Gustavo Marquesine Paul, Haitham Elbardisi, Hakan Keskin, Hamed Akhavadegan, Haocheng Lin, Hassan N Sallam, Herik Acosta, Hisanori Taniguchi, Hussein Kandil, Hyun Jun Park, Imad Ziouziou, Ioannis Sokolakis, Israel Maldonado Rosas, Jackson Kirkman-Brown, Jae Il Shin, Jean de la Rosette, Jens Sonksen, Jie Dong, Jim Hotaling, Jo Ben Chua, Joe Lee, Joel Marmar, Jonathan Ramsay, Jose Moreno- Sepulveda, Ju Tae Seo, Juan Alvarez, Juan Manuel Corral Molina, Ka Lun Lo, Kaan Aydos, Kadir Bocu, Kareim Khalafalla, Kashif Siddiqi, Kasonde Bowa, Kavindra Kumar Kesari, Kay-

Seong Ngoo, Keisuke Okada, Keshab Karna, Koichi Nagao, Koji Chiba, Konstantinos Makarounis, Landon Trost, Lawrence Jenkins, Lucia Rocco, Lukman Hakim, Mahsa Darbandi, Mara Simopoulou, Marah Hehemann, Marcelo Rodriguez Peña, Marco Alves, Marco Falcone, Marion Bendayan, Marjan Sabbaghian, Marlon Martinez, Marziyeh Tavalae, Massimiliano Timpano, Mazdak Razi, Mesut Altan, Mesut Berkan Duran, Mikkel Fode, Miroslav Vučinić, Mitsuru Nago, Mohamad Moussa, Mohamed Arafa, Mohamed Elkhoully, Mohamed Khalili, Mohamed S. Al-Marhoon, Mohammad Ali Sadighi Gilani, Mohammad Ayodhia Soebadi, Mohammad Hossein Nasr-Esfahani, Mohan S Kamath, Muhammet Rasit Ugur, Murat Gül, Mustafa Emre Bakırcıoğlu, Nam Cheol Park, Natalio Cruz, Nazim Gherabi, Neel Parekh, Nguyen Ho Vinh Phuoc, Nicholas Tadros, Nicolas Garrido, Nikolaos Sofikitis, Niloofar Sodeifi, Noora Al Khalidi, Oğuzhan Kahraman, Ohad Shoshany, Osvaldo Rajmil, Paksi Satyagraha, Panagiotos Drakopoulos, Paraskevi Vogiatzi, Parisa Dolati, Partha Das, Parviz Kavoussi, Peter Ka-Fung Chiu, Petroula A. Tsioulou, Ponco Birowo, Premal Patel, Priyank Kothari, Puneet Sindhwani, Qaisar Javed, Quang Nguyen, Rafael F. Ambar, Raghavender Kosgi, Rajender Singh, Ralf Henkel, Ramadan Saleh, Ramy Abou Ghayda, Raneen Sawaid Kaiyal, Raphael Henrique Ferreira Santos, Ricky Adriansjah, Rima Dada, Rosita Angela Condorelli, Rossella Cannarella, Rupin Shah, Sakti Brodjonegoro, Saleem Ali Banihani, Samantha Schon, Sami AlSaid, Sandro La Vignera, Sara Darbandi, Sava Micic, Selcuk Sari-kaya, Sezgin Gunes, Shannon Hee Kyung Kim, Sheena E Lewis, Sheryl Homa, Shingai Mutambirwa, Shinichiro Fukuhara, Shinnosuke Kuroda, Shubhadeep Roychoudhury, Sijo Parekatil, Siu King Mak, Sofia Ines Leonardi Diaz, Sreelatha Gopalakrishnan, Stephen Krawetz, Suks Minhas, Sun Tae Ahn, Sunil Jindal, Taha Abo-Elmagd Abdel-Meguid, Tan V Le, Taymour Mostafa, Teng Aik Ong, Teppei Takeshima, Thorsten Diemer, Tiago Cesar Mierzwa, Tomer Avidor-Reiss, Toshiyasu Amano, Trenton Barrett, Tsung Yen Lin, Tuncay Toprak, Umut Arslan, Vijay Kumar, Vilvopathy Senguttuvan Karthikeyan, Vineet Malhotra, Wael Ibrahim, Walid Kerkeni, Widi Atmoko, Wongi Woo, Yasushi Yumura, Yiming Yuan, Yoshiharu Morimoto, Yuki Kato, Yukihiro Umemoto, Yu-Sheng Cheng.

The authors are thankful to the following societies and journals for promoting this online survey through the efforts of their members, as listed below:

- 1) Arab Association of Urology (Hussein Kandil, MD, UAE)
- 2) Asia Pacific Society of Sexual Medicine (Hyun Jun Park, MD, South Korea)
- 3) Association Francaise d'Urologie (Eric Huyghe, MD, France)
- 4) Brazilian Association of Assisted Reproduction (Edson

Borges Jr, MD)

- 5) Brazilian Society of Urology (Rafael F. Ambar, MD, Brazil)
- 6) Egyptian Society of Andrology (Mohamed Arafa, MD, Qatar)
- 7) European Association of Urology (Fotios Dimitriadis, MD, Greece; Nikolaos Sofikitis, MD, PhD, Greece)
- 8) Indonesian Urological Association (Ponco Birowo, MD, PhD; Gede Wirya Kusuma Duarsa, MD, PhD; Widi Atmoko, MD)
- 9) Indonesian Society of Andrological Urology (Ricky Adriansjah, MD)
- 10) Iranian Urological Association (Mohammad Ali Sadighi Gilani, MD, Iran)
- 11) Middle East Society for Sexual Medicine (Amr El Meliegy, MD, FECSM, Egypt)
- 12) Sociedad Argentina de Andrologia (Marcelo Rodriguez Peña MD, PhD)
- 13) Société d'Andrologie de Langue Française (Florence Boitrelle, MD, France)
- 14) Société Internationale d'Urologie (Jean de la Rosette, MD PhD)
- 15) Spanish Association of Andrology, Sexual and Reproductive Medicine (Juan Manuel Corral Molina, MD, PhD, Spain; Juan Alvarez, MD, PhD, Spain)
- 16) Turkish Association of Urology (Ates Kadioglu, MD, Turkey)
- 17) Urological Society of Australia and New Zealand (Hyun Jun Park, MD, South Korea)

Author Contribution

Conceptualization: Ashok Agarwal, Rupin Shah. Data curation: Shinnosuke Kuroda, Ahmed M. Harraz. Methodology, Project administration: Ashok Agarwal. Writing – original draft: Parviz Kavoussi, Amarnath Rambhatla, Ramadan Saleh, Rossella Cannarella, Florence Boitrelle, Shinnosuke Kuroda, Taha Abo-Almagd Abdel-Meguid Hamoda, Armand Zini, Edmund Ko, Gokhan Calik, Tuncay Toprak, Hussein Kandil, Murat Gül. Writing – review & editing: All authors.

Author's Initials

*RS: Rupin Shah, PK: Parviz Kavoussi, AR: Amarnath Rambhatla, NP: Neel Parekh, EK: Edmund Ko, NT: Nicholas Tadros, MEB: Mustafa Emre Bakırcıoğlu, HK: Hussein Kandil, TM: Taymour Mostafa.

†GMC: Giovanni M. Colpi, AZ: Armand Zini, AK: Ates Kadioglu, MG: Murat Gül, AR: Amarnath Rambhatla, PK: Parviz

Kavoussi, TH: Taha Abo-Almagd Abdel-Meguid Hamoda, EK: Edmund Ko, GR: Giorgio Ivan Russo, HK: Hussein Kandil, MA: Mohamed Arafa, TT: Tuncay Toprak, MEB: Mustafa Emre Bakırcıoğlu, OR: Osvaldo Rajmil, GC: Gokhan Calik, AH: Ahmed M. Harraz.

REFERENCES

1. Su JS, Farber NJ, Vij SC. Pathophysiology and treatment options of varicocele: an overview. *Andrologia* 2021;53:e13576.
2. Alsaikhan B, Alrabeeh K, Delouya G, Zini A. Epidemiology of varicocele. *Asian J Androl* 2016;18:179-81.
3. Damsgaard J, Joensen UN, Carlsen E, Erenpreiss J, Blomberg Jensen M, Matulevicius V, et al. Varicocele is associated with impaired semen quality and reproductive hormone levels: a study of 7035 healthy young men from six European countries. *Eur Urol* 2016;70:1019-29.
4. The influence of varicocele on parameters of fertility in a large group of men presenting to infertility clinics. *World Health Organization. Fertil Steril* 1992;57:1289-93.
5. Baskaran S, Agarwal A, Leisegang K, Pushparaj PN, Panner Selvam MK, Henkel R. An in-depth bibliometric analysis and current perspective on male infertility research. *World J Mens Health* 2021;39:302-14.
6. Agarwal A, Finelli R, Durairajanayagam D, Leisegang K, Henkel R, Salvio G, et al. Comprehensive analysis of global research on human varicocele: a scientometric approach. *World J Mens Health* 2022. doi: 10.5534/wjmh.210202 [Epub].
7. Persad E, O'Loughlin CA, Kaur S, Wagner G, Matyas N, Hassler-Di Fratta MR, et al. Surgical or radiological treatment for varicoceles in subfertile men. *Cochrane Database Syst Rev* 2021;4:CD000479.
8. Salonia A, Bettocchi C, Boeri L, Capogrosso P, Carvalho J, Cilesiz NC, et al.; EAU Working Group on Male Sexual and Reproductive Health. European Association of Urology guidelines on sexual and reproductive health-2021 update: male sexual dysfunction. *Eur Urol* 2021;80:333-57.
9. Minhas S, Bettocchi C, Boeri L, Capogrosso P, Carvalho J, Cilesiz NC, et al.; EAU Working Group on Male Sexual and Reproductive Health. European Association of Urology guidelines on male sexual and reproductive health: 2021 update on male infertility. *Eur Urol* 2021;80:603-20.
10. Schlegel PN, Sigman M, Collura B, De Jonge CJ, Eisenberg ML, Lamb DJ, et al. Diagnosis and treatment of infertility in men: AUA/ASRM guideline. *Linthicum (MD): American Urology Association*; 2020.
11. Schlegel PN, Sigman M, Collura B, De Jonge CJ, Eisenberg ML, Lamb DJ, et al. Diagnosis and treatment of infertility in

- men: AUA/ASRM guideline part I. *J Urol* 2021;205:36-43.
12. Schlegel PN, Sigman M, Collura B, De Jonge CJ, Eisenberg ML, Lamb DJ, et al. Diagnosis and treatment of infertility in men: AUA/ASRM guideline part II. *J Urol* 2021;205:44-51.
 13. Freeman S, Bertolotto M, Richenberg J, Belfield J, Dogra V, Huang DY, et al.; members of the ESUR-SPIWG WG. Ultrasound evaluation of varicoceles: guidelines and recommendations of the European Society of Urogenital Radiology Scrotal and Penile Imaging Working Group (ESUR-SPIWG) for detection, classification, and grading. *Eur Radiol* 2020;30:11-25.
 14. Hoekstra T, Witt MA. The correlation of internal spermatic vein palpability with ultrasonographic diameter and reversal of venous flow. *J Urol* 1995;153:82-4.
 15. Pilatz A, Altinkilic B, Köhler E, Marconi M, Weidner W. Color Doppler ultrasound imaging in varicoceles: is the venous diameter sufficient for predicting clinical and subclinical varicocele? *World J Urol* 2011;29:645-50.
 16. Karami M, Mazdak H, Khanbabapour S, Adibi A, Nasr N. Determination of the best position and site for color Doppler ultrasonographic evaluation of the testicular vein to define the clinical grades of varicocele ultrasonographically. *Adv Biomed Res* 2014;3:17.
 17. Cavallini G, Scropo FI, Colpi GM. The clinical usefulness of a novel grading system for varicoceles using duplex Doppler ultrasound examination based on postsurgical modifications of seminal parameters. *Andrology* 2019;7:62-8.
 18. An AUA Best Practice Policy, ASRM Practice Committee Report. Report on varicocele and infertility [Internet]. Linticum (MD): American Urological Association; 2012 [Cited 2022 May 27]. Available from: <https://www.auanet.org/documents/education/clinical-guidance/Varicocele-Archive.pdf>.
 19. Pyrgidis N, Sokolakis I, Palapelas V, Tishukov M, Mykoniatis I, Symeonidis EN, et al. The effect of antioxidant supplementation on operated or non-operated varicocele-associated infertility: a systematic review and meta-analysis. *Antioxidants (Basel)* 2021;10:1067.
 20. Giagulli VA, Carbone MD. Varicocele correction for infertility: which patients to treat? *Int J Androl* 2011;34:236-41.
 21. Nieschlag E, Hertle L, Fishedick A, Abshagen K, Behre HM. Update on treatment of varicocele: counselling as effective as occlusion of the vena spermatica. *Hum Reprod* 1998;13:2147-50.
 22. Wang Q, Yu Y, Liu Y, Wang L. Outcome of varicocelectomy on different degrees of total motile sperm count: a systematic review and meta-analysis. *Syst Biol Reprod Med* 2019;65:430-6.
 23. Boman JM, Libman J, Zini A. Microsurgical varicocelectomy for isolated asthenospermia. *J Urol* 2008;180:2129-32.
 24. Cakiroglu B, Sinanoglu O, Gozukucuk R. The effect of varicocelectomy on sperm parameters in subfertile men with clinical varicoceles who have asthenozoospermia or teratozoospermia with normal sperm density. *ISRN Urol* 2013;2013:698351.
 25. Okeke L, Ikuerowo O, Chiekwe I, Etukakpan B, Shittu O, Olapade-Olaopa O. Is varicocelectomy indicated in subfertile men with clinical varicoceles who have asthenospermia or teratospermia and normal sperm density? *Int J Urol* 2007;14:729-32.
 26. Coetzee K, Kruger TF, Lombard CJ. Predictive value of normal sperm morphology: a structured literature review. *Hum Reprod Update* 1998;4:73-82.
 27. Danis RB, Samplaski MK. Sperm morphology: history, challenges, and impact on natural and assisted fertility. *Curr Urol Rep* 2019;20:43.
 28. Kohn TP, Kohn JR, Ramasamy R. Effect of sperm morphology on pregnancy success via intrauterine insemination: a systematic review and meta-analysis. *J Urol* 2018;199:812-22.
 29. Choe JH, Seo JT. Is varicocelectomy useful for subfertile men with isolated teratozoospermia? *Urology* 2015;86:1123-8.
 30. Ilktac A, Hamidli S, Ersoz C, Dogan B, Akcay M. Efficacy of varicocelectomy in primary infertile patients with isolated teratozoospermia. A retrospective analysis. *Andrologia* 2020;52:e13875.
 31. Cakan M, Bakirtas H, Aldemir M, Demirel F, Altug U. Results of varicocelectomy in patients with isolated teratozoospermia. *Urol Int* 2008;80:172-6.
 32. De Braekeleer M, Nguyen MH, Morel F, Perrin A. Genetic aspects of monomorphic teratozoospermia: a review. *J Assist Reprod Genet* 2015;32:615-23.
 33. Dumont A, Barbotin AL, Lefebvre-Khalil V, Mitchell V, Rigot JM, Boitrelle F, et al. [Necrozoospermia: from etiologic diagnosis to therapeutic management]. *Gynecol Obstet Fertil Senol* 2017;45:238-48. French.
 34. Ribas-Maynou J, Yeste M, Becerra-Tomás N, Aston KI, James ER, Salas-Huetos A. Clinical implications of sperm DNA damage in IVF and ICSI: updated systematic review and meta-analysis. *Biol Rev Camb Philos Soc* 2021;96:1284-300.
 35. Lara-Cerrillo S, Gual-Frau J, Benet J, Abad C, Prats J, Amengual MJ, et al. Microsurgical varicocelectomy effect on sperm telomere length, DNA fragmentation and seminal parameters. *Hum Fertil (Camb)* 2022;25:135-41.
 36. Lira Neto FT, Roque M, Esteves SC. Effect of varicocelectomy on sperm deoxyribonucleic acid fragmentation rates in infertile men with clinical varicocele: a systematic review and meta-analysis. *Fertil Steril* 2021;116:696-712.
 37. Qiu D, Shi Q, Pan L. Efficacy of varicocelectomy for sperm

- DNA integrity improvement: a meta-analysis. *Andrologia* 2021;53:e13885.
38. Saleh RA, Agarwal A, Sharma RK, Said TM, Sikka SC, Thomas AJ Jr. Evaluation of nuclear DNA damage in spermatozoa from infertile men with varicocele. *Fertil Steril* 2003;80:1431-6.
 39. Smith R, Kaune H, Parodi D, Madariaga M, Rios R, Morales I, et al. Increased sperm DNA damage in patients with varicocele: relationship with seminal oxidative stress. *Hum Reprod* 2006;21:986-93.
 40. Ammar O, Tekeya O, Hannachi I, Sallem A, Haouas Z, Mehdi M. Increased sperm DNA fragmentation in infertile men with varicocele: relationship with apoptosis, seminal oxidative stress, and spermatic parameters. *Reprod Sci* 2021;28:909-19.
 41. Jeremias JT, Belardin LB, Okada FK, Antoniassi MP, Fraietta R, Bertolla RP, et al. Oxidative origin of sperm DNA fragmentation in the adult varicocele. *Int Braz J Urol* 2021;47:275-83.
 42. Fathi A, Mohamed O, Mahmoud O, Alsagheer GA, Reyad AM, Abolyosr A, et al. The impact of varicocele repair on sperm DNA fragmentation and pregnancy rate in subfertile men with normal semen parameters: a pilot study. *Arab J Urol* 2021;19:186-90.
 43. Esteves SC, Roque M, Agarwal A. Outcome of assisted reproductive technology in men with treated and untreated varicocele: systematic review and meta-analysis. *Asian J Androl* 2016;18:254-8.
 44. Kirby EW, Wiener LE, Rajanahally S, Crowell K, Coward RM. Undergoing varicocele repair before assisted reproduction improves pregnancy rate and live birth rate in azoospermic and oligospermic men with a varicocele: a systematic review and meta-analysis. *Fertil Steril* 2016;106:1338-43.
 45. Tan TY, Lau SK, Loh SF, Tan HH. Female ageing and reproductive outcome in assisted reproduction cycles. *Singapore Med J* 2014;55:305-9.
 46. Firat F, Erdemir F. The effect of age on semen quality and spontaneous pregnancy rates in patients who treated with microsurgical inguinal varicocele. *Cureus* 2020;12:e7744.
 47. Hsiao W, Rosoff JS, Pale JR, Greenwood EA, Goldstein M. Older age is associated with similar improvements in semen parameters and testosterone after subinguinal microsurgical varicocele. *J Urol* 2011;185:620-5.
 48. Asafu-Adjei D, Judge C, Deibert CM, Li G, Stember D, Stahl PJ. Systematic review of the impact of varicocele grade on response to surgical management. *J Urol* 2020;203:48-56.
 49. Birowo P, Prasetyo DT, Pujianto DA, Atmoko W, Rasyid N, Sini IR. Effect of varicocele repair on sperm retrieval rate and testicular histopathological patterns in men with nonobstructive azoospermia. *Asian J Androl* 2022;24:85-9.
 50. Cantoro U, Catanzariti F, Lacetera V, Quaresima L, Giovanni M, Polito M. Percentage change of FSH value: new variable to predict the seminal outcome after varicocele. *Andrologia* 2015;47:412-6.
 51. Zhou T, Zhang W, Chen Q, Li L, Cao H, Xu CL, et al. Effect of varicocele repair on testis volume and semen parameters in adolescents: a meta-analysis. *Asian J Androl* 2015;17:1012-6.
 52. Culha M, Mutlu N, Acar O, Baykal M. Comparison of testicular volumes before and after varicocele. *Urol Int* 1998;60:220-3.
 53. Sakamoto H, Saito K, Ogawa Y, Yoshida H. Effects of varicocele repair in adults on ultrasonographically determined testicular volume and on semen profile. *Urology* 2008;71:485-9.
 54. Almekaty K, Zahran MH, Zoeir A, Minhas S, Salem K. The role of artery-preserving varicocele repair in subfertile men with severe oligozoospermia: a randomized controlled study. *Andrology* 2019;7:193-8.
 55. Majzoub A, ElBardisi H, Covarrubias S, Mak N, Agarwal A, Henkel R, et al. Effect of microsurgical varicocele repair on fertility outcome and treatment plans of patients with severe oligozoospermia: an original report and meta-analysis. *Andrologia* 2021;53:e14059.
 56. Enatsu N, Yamaguchi K, Chiba K, Miyake H, Fujisawa M. Clinical outcome of microsurgical varicocele repair in infertile men with severe oligozoospermia. *Urology* 2014;83:1071-4.
 57. Dada R, Kumar R, Shamsi MB, Sidhu T, Mitra A, Singh S, et al. Azoospermia factor deletions in varicocele cases with severe oligozoospermia. *Indian J Med Sci* 2007;61:505-10.
 58. Samplaski MK, Jarvi KA. Prognostic factors for a favorable outcome after varicocele repair in adolescents and adults. *Asian J Androl* 2016;18:217-21.
 59. Samplaski MK, Yu C, Kattan MW, Lo KC, Grober ED, Zini A, et al. Nomograms for predicting changes in semen parameters in infertile men after varicocele repair. *Fertil Steril* 2014;102:68-74.
 60. Kamal KM, Jarvi K, Zini A. Microsurgical varicocele repair in the era of assisted reproductive technology: influence of initial semen quality on pregnancy rates. *Fertil Steril* 2001;75:1013-6.
 61. Ding H, Tian J, Du W, Zhang L, Wang H, Wang Z. Open non-microsurgical, laparoscopic or open microsurgical varicocele repair for male infertility: a meta-analysis of randomized controlled trials. *BJU Int* 2012;110:1536-42.
 62. Lundy SD, Sabanegh ES Jr. Varicocele management for infertility and pain: a systematic review. *Arab J Urol* 2017;16:157-70.

63. Cocuzza M, Pagani R, Coelho R, Srougi M, Hallak J. The systematic use of intraoperative vascular Doppler ultrasound during microsurgical subinguinal varicocelectomy improves precise identification and preservation of testicular blood supply. *Fertil Steril* 2010;93:2396-9.
64. Mehta A, Goldstein M. Microsurgical varicocelectomy: a review. *Asian J Androl* 2013;15:56-60.
65. Wang J, Xia SJ, Liu ZH, Tao L, Ge JF, Xu CM, et al. Inguinal and subinguinal micro-varicocelectomy, the optimal surgical management of varicocele: a meta-analysis. *Asian J Androl* 2015;17:74-80.
66. Colpi GM, Carmignani L, Nerva F, Piediferro G, Castiglioni F, Grugnetti C, et al. Surgical treatment of varicocele by a subinguinal approach combined with antegrade intraoperative sclerotherapy of venous vessels. *BJU Int* 2006;97:142-5.
67. Cassidy D, Jarvi K, Grober E, Lo K. Varicocele surgery or embolization: which is better? *Can Urol Assoc J* 2012;6:266-8.
68. Sayfan J, Adam YG, Soffer Y. A new entity in varicocele subfertility: the "cremasteric reflux". *Fertil Steril* 1980;33:88-90.
69. Goldstein M, Gilbert BR, Dicker AP, Dwosh J, Gnecco C. Microsurgical inguinal varicocelectomy with delivery of the testis: an artery and lymphatic sparing technique. *J Urol* 1992;148:1808-11.
70. Ramasamy R, Schlegel PN. Microsurgical inguinal varicocelectomy with and without testicular delivery. *Urology* 2006;68:1323-6.
71. Hou Y, Zhang Y, Zhang Y, Huo W, Li H. Comparison between microsurgical subinguinal varicocelectomy with and without testicular delivery for infertile men: is testicular delivery an unnecessary procedure. *Urol J* 2015;12:2261-6.
72. Allameh F, Hasanzadeh Haddad A, Abedi A, Ranjbar A, Qashqai H, Fadavi B, et al. Varicocelectomy with primary gubernaculum veins closure: a randomised clinical trial. *Andrologia* 2018. doi: 10.1111/and.12991 [Epub].
73. Ou N, Zhu J, Zhang W, Liang Z, Hu R, Song Y, et al. Bilateral is superior to unilateral varicocelectomy in infertile men with bilateral varicocele: systematic review and meta-analysis. *Andrologia* 2019;51:e13462.
74. Niu Y, Wang D, Chen Y, Pokhrel G, Xu H, Wang T, et al. Comparison of clinical outcome of bilateral and unilateral varicocelectomy in infertile males with left clinical and right subclinical varicocele: a meta-analysis of randomised controlled trials. *Andrologia* 2018;50:e13078.
75. Sun XL, Wang JL, Peng YP, Gao QQ, Song T, Yu W, et al. Bilateral is superior to unilateral varicocelectomy in infertile males with left clinical and right subclinical varicocele: a prospective randomized controlled study. *Int Urol Nephrol* 2018;50:205-10.
76. Zheng YQ, Gao X, Li ZJ, Yu YL, Zhang ZG, Li W. Efficacy of bilateral and left varicocelectomy in infertile men with left clinical and right subclinical varicoceles: a comparative study. *Urology* 2009;73:1236-40.
77. Chehval MJ, Purcell MH. Deterioration of semen parameters over time in men with untreated varicocele: evidence of progressive testicular damage. *Fertil Steril* 1992;57:174-7.
78. Addar AM, Nazer A, Almardawi A, Al Hathal N, Kattan S. The yield of microscopic varicocelectomy in men with severe oligospermia. *Urol Ann* 2021;13:268-71.
79. Chan PT, Wright EJ, Goldstein M. Incidence and postoperative outcomes of accidental ligation of the testicular artery during microsurgical varicocelectomy. *J Urol* 2005;173:482-4.
80. Barazani Y, Nagler HM. Other work has highlighted the limitations of using histopathology to predict success after varicocelectomy. *Fertil Steril* 2011;95:487.
81. Lund L, Roebuck DJ, Lee KH, Sørensen HT, Yeung CK. Clinical assessment after varicocelectomy. *Scand J Urol Nephrol* 2000;34:119-22.
82. Akçar Değirmenci N, Turgut M, Ozkan R. [Recurrence rate after varicocelectomy in infertile men]. *Tani Girisim Radyol* 2004;10:144-6. Turkish.
83. Rotker K, Sigman M. Recurrent varicocele. *Asian J Androl* 2016;18:229-33.
84. Cayan S, Shavakhov S, Kadioğlu A. Treatment of palpable varicocele in infertile men: a meta-analysis to define the best technique. *J Androl* 2009;30:33-40.
85. Franco G, Iori F, de Dominicis C, Dal Forno S, Mander A, Laurenti C. Challenging the role of cremasteric reflux in the pathogenesis of varicocele using a new venographic approach. *J Urol* 1999;161:117-21.
86. Kim KH, Lee JY, Kang DH, Lee H, Seo JT, Cho KS. Impact of surgical varicocele repair on pregnancy rate in subfertile men with clinical varicocele and impaired semen quality: a meta-analysis of randomized clinical trials. *Korean J Urol* 2013;54:703-9.
87. Baazeem A, Belzile E, Ciampi A, Dohle G, Jarvi K, Salonia A, et al. Varicocele and male factor infertility treatment: a new meta-analysis and review of the role of varicocele repair. *Eur Urol* 2011;60:796-808.
88. Fukuda T, Miyake H, Enatsu N, Matsushita K, Fujisawa M. Assessment of time-dependent changes in semen parameters in infertile men after microsurgical varicocelectomy. *Urology* 2015;86:48-51.
89. Al Bakri A, Lo K, Grober E, Cassidy D, Cardoso JP, Jarvi K. Time for improvement in semen parameters after varicocelectomy. *J Urol* 2012;187:227-31.
90. Ghaed MA, Makian SA, Moradi A, Maghsoudi R, Gandomi-

- Mohammadabadi A. Best time to wait for the improvement of the sperm parameter after varicocelectomy: 3 or 6 months? *Arch Ital Urol Androl* 2020;92. doi: 10.4081/aiua.2020.3.259.
91. Machen GL, Johnson D, Nissen MA, Naber E, Sandlow JI. Time to improvement of semen parameters after microscopic varicocelectomy: when it occurs and its effects on fertility. *Andrologia* 2020;52:e13500.
 92. Masterson TA, Greer AB, Ramasamy R. Time to improvement in semen parameters after microsurgical varicocelectomy in men with severe oligospermia. *Can Urol Assoc J* 2019;13:E66-9.
 93. Seo JT, Kim KT, Moon MH, Kim WT. The significance of microsurgical varicocelectomy in the treatment of subclinical varicocele. *Fertil Steril* 2010;93:1907-10.
 94. Cantoro U, Polito M, Muzzonigro G. Reassessing the role of subclinical varicocele in infertile men with impaired semen quality: a prospective study. *Urology* 2015;85:826-30.
 95. Elzanaty S. Varicocele repair in non-obstructive azoospermic men: diagnostic value of testicular biopsy - a meta-analysis. *Scand J Urol* 2014;48:494-8.
 96. Weedon JW, Khera M, Lipshultz LI. Varicocele repair in patients with nonobstructive azoospermia: a meta-analysis. *J Urol* 2010;183:2309-15.
 97. Esteves SC, Miyaoka R, Roque M, Agarwal A. Outcome of varicocele repair in men with nonobstructive azoospermia: systematic review and meta-analysis. *Asian J Androl* 2016;18:246-53.
 98. Berookhim BM, Schlegel PN. Azoospermia due to spermatogenic failure. *Urol Clin North Am* 2014;41:97-113.
 99. Abdel-Meguid TA. Predictors of sperm recovery and azoospermia relapse in men with nonobstructive azoospermia after varicocele repair. *J Urol* 2012;187:222-6.
 100. Lee JS, Park HJ, Seo JT. What is the indication of varicocelectomy in men with nonobstructive azoospermia? *Urology* 2007;69:352-5.
 101. Sharma RK, Gupta S, Agarwal A, Finelli R, Kuroda S, Saleh R, et al. Role of cyto centrifugation combined with nuclear fast picroindigocarmine staining in detecting cryptozoospermia in men diagnosed with azoospermia. *World J Mens Health* 2022. doi: 10.5534/wjmh.210210 [Epub].
 102. Krausz C, Riera-Escamilla A, Moreno-Mendoza D, Holleman K, Cioppi F, Algaba F, et al. Genetic dissection of spermatogenic arrest through exome analysis: clinical implications for the management of azoospermic men. *Genet Med* 2020;22:1956-66.
 103. Inci K, Hascicek M, Kara O, Dikmen AV, Gürkan T, Ergen A. Sperm retrieval and intracytoplasmic sperm injection in men with nonobstructive azoospermia, and treated and untreated varicocele. *J Urol* 2009;182:1500-5.
 104. Haydardedeoglu B, Turunc T, Kilicdag EB, Gul U, Bagis T. The effect of prior varicocelectomy in patients with nonobstructive azoospermia on intracytoplasmic sperm injection outcomes: a retrospective pilot study. *Urology* 2010;75:83-6.