

# Clinical characteristics and outcomes of ocular injuries in pediatric patients

Sezin Akça Bayar, M.D.,<sup>1</sup> Zeynep Kayaarası Öztürker, M.D.,<sup>2</sup> Gürsel Yılmaz, M.D.<sup>1</sup>

<sup>1</sup>Department of Ophthalmology, Başkent University Ankara Hospital, Ankara-Turkey

<sup>2</sup>Department of Ophthalmology, Başkent University İstanbul Hospital, İstanbul-Turkey

## ABSTRACT

**BACKGROUND:** Childhood eye injuries are one of the most common causes of acquired unilateral blindness. In this study, our purpose was to investigate the demographics, etiology, and outcome of pediatric patients with ocular injury.

**METHODS:** The charts of children with ocular trauma who presented to Baskent University Hospitals, between January 1, 2017 and December 31, 2019 were retrospectively reviewed. All patients who were under 16 years of age were included. Data were collected on age, sex, time of trauma, injury type, associated injuries, treatments, visual impairment, intraocular pressure (IOP), and ophthalmic sequelae. Ocular traumas were classified according to the Birmingham Eye Trauma Terminology (BETT) system.

**RESULTS:** A total of 21 patients were identified. Male-female ratio was 13/8. The mean age of the patients was  $8.5 \pm 3.4$  years. Mean post-treatment follow-up was  $8.2 \pm 4.3$  months. Injury was unilateral in all cases (10 right eye, 11 left eye). Fifteen patients (71.4%) had open globe, and 6 (28.5%) had closed globe injury. Type of injury was rupture in 7 cases, perforation in 5, penetration in 4, and intraocular foreign body in 4. A total of 5 cases were documented to have retinal detachment during the follow-up. Sharp injuries were documented in 11 (64.7%) cases, and blunt in 6 (35.2%). The most frequent finding was hyphema in blunt injury, and corneal laceration in perforating injury. Five patients had choroidal hemorrhage, 3 had commotio retinae, 2 had intravitreal hemorrhage, 1 had subhyaloidal hemorrhage, 1 had macular hole, and 1 had optic nerve avulsion. Lens aspiration was performed in 12 (57.1%) cases, and 2 of them had intraocular lens implantation. In children whose initial vision was able to be taken, 4 had no light perception, 7 had light perception-counting fingers, and 5 had best-corrected visual acuity of 0.05–0.3. At final visit, 61.9% of patients had a VA of 0.05–0.8. Corneal scar or leucoma was observed in 14 (66.6%) cases at last visit. One eye was enucleated due to post-traumatic endophthalmitis that did not respond to treatment. At final visit, IOP <6 mmHg was identified in 2 cases and >21 mmHg in 4.

**CONCLUSION:** Anterior segment damage is the main cause of visual morbidity in pediatric ocular trauma. Injuries with sharp objects occur twice as often as blunt trauma and reduce vision with residual corneal scarring in about two-thirds of patients. Understanding the pattern of eye injuries is useful in determining the strategies required to protect children's eye health.

**Keywords:** Ocular trauma; pediatric ophthalmology; visual acuity.

## INTRODUCTION

Ocular trauma is an important cause of acquired monocular blindness worldwide and represents 8–14% of all injuries in children.<sup>[1–4]</sup> The prognosis of eyes with globe injury is variable and depends on the type of injury, the location of the wound, the extent of the laceration, posterior segment involvement, and the presence of infection.<sup>[5,6]</sup> Although one-quarter of the

injuries are non-penetrating, perforating injuries of the eye are a frequent cause of unilateral visual loss.<sup>[4,7–9]</sup>

From a public health perspective, eye injuries affect not only the eyes but also the quality of life and productivity of the patients. Post-traumatic visual impairment can lead to significant handicap with deep psychological and social impact on the child.<sup>[8]</sup> Therefore, it is important to better understand

Cite this article as: Akça Bayar S, Kayaarası Öztürker Z, Yılmaz G. Clinical characteristics and outcomes of ocular injuries in pediatric patients. *Ulus Travma Acil Cerrahi Derg* 2022;28:654-661.

Address for correspondence: Zeynep Kayaarası Öztürker, M.D.

Başkent Üniversitesi İstanbul Hastanesi, Göz Hastalıkları Anabilim Dalı, İstanbul, Turkey

Tel: +90 216 - 554 15 00 E-mail: zeynepkayaa@yahoo.com

*Ulus Travma Acil Cerrahi Derg* 2022;28(5):654-661 DOI: 10.14744/tjtes.2021.54524 Submitted: 09.12.2020 Accepted: 18.01.2021

Copyright 2022 Turkish Association of Trauma and Emergency Surgery



ocular injury patterns to implement appropriate prevention and management strategies. It is indicated that up to 90% of eye injuries could be prevented with better education, supervision, and proper safety eyewear.<sup>[10]</sup>

The differences in pediatric eye anatomy and more severe inflammatory reaction than adults can change the prognosis in pediatric patients. In addition, children are vulnerable to amblyopia which remains a difficult management problem. Initial evaluation is difficult due to an often unreliable and variable history and poor cooperation during ocular examination. Such difficulties often persist during the follow-up period. In this study, we aimed to identify the demographics and clinical features of globe injuries in children presenting to a tertiary care hospital, Baskent University, Ophthalmology Clinics in 3 years period. We also reviewed the outcomes of these injuries. Our review of English literature revealed that in the past two decades only four pediatric studies from two major cities of Turkey, Ankara and Istanbul, have been published describing globe injuries. The information from this study may provide added insight in the development of strategies to prevent ocular injuries in Turkish population.

## MATERIALS AND METHODS

We retrospectively reviewed the medical records of patients under 16-years-old who presented to the Ophthalmology Department of Baskent University, from January 1, 2017 to December 31, 2019.

The study adhered to the tenets of the Declaration of Helsinki, and ethical approval was obtained from the ethical committee of Baskent University. Informed consent for patient information and images to be published was provided by the patient's legally authorized representative.

A data file was built to register the patients' demographics which include age, gender, and laterality. The initial clinical examination included best-corrected visual acuity (BCVA) on presentation, the presence or absence of a relative afferent pupil defect and red reflex, and ocular motility. These were followed by the biomicroscopic examination to assess the anterior segment damage (subconjunctival hemorrhage, corneal/scleral laceration, hyphema, inflammation, irregular pupil, iris prolapse, lens subluxation, and cataract), and/or the posterior segment damage (vitreous hemorrhage, retinal detachment, and choroidal hemorrhage). Gonioscopic examination was applied to exclude angle recession and iridodiagnosis. The traumatizing object was also identified. Ocular injuries were classified according to the Birmingham Eye Trauma Terminology (BETT) system.<sup>[6]</sup> The BETT distinguishes closed- and open-globe injuries (penetration [one entrance] and perforating lesions [entrance and exit wound] and the presence of an intraocular foreign body [IOFB]). The data also included the final BCVA, the mean time from trauma to patient admission and mean time from patient admission to the op-

erating room, concomitant ocular findings, endophthalmitis, additional surgeries, duration of follow-up, the status of the eye at the last visit, and intraocular pressure (IOP). IOP was measured with applanation tonometer only in the absence of open globe injury. Otherwise, digital eye palpation was applied. Eyes with IOP <6 mmHg were defined as hypotony, and eyes with IOP >21 mmHg without evidence of glaucomatous damage in the optic nerve head were accepted as ocular hypertension.

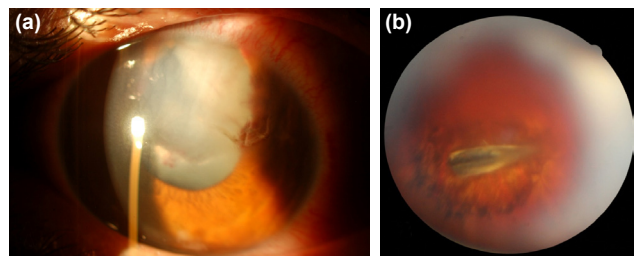
Self-adhesive wounds or cases with delayed admission to the clinic were included in the study. However, injuries that underwent primary suturing in another facility and referred for secondary surgery were excluded from the study.

## Statistical Analysis

Data were analyzed using SPSS® (version 20.0; IBM Inc., Chicago, IL, USA). Descriptive analysis was done, where categorical variables were presented as frequencies and percentages and continuous variables in the form of mean ( $\pm$ standard deviation) and range (minimum to maximum). A p-value below 0.05 was interpreted as an indicator of statistical significance.

## RESULTS

Demographics and types of ocular injuries of the patients are shown in Table 1. During the study period, 21 pediatric patients were identified to have undergone treatment for traumatic globe injury. The mean age was  $8.5\pm 3.4$  (range: 3–16) years. The male-female ratio was 1.6:1. The injury was unilateral in all cases, and the left eye was injured in 11 (52.4%). Fifteen patients (71.4%) had open globe injury, and 6 (28.5%) had closed globe injury. The most common type of injury was rupture in 7 (33.3%) cases. In one eye, there was a self-sealed corneal wound. Sharp injuries were documented in 52.3% of the cases, and knife was the most common tool (45.4%). Wood/organic material (40%) was the most frequent cause of injury in blunt trauma. Among eyes with open globe injury, IOFB was seen in 4 (26.6%) eyes, and the most frequent causative agents were glass (n=3), and wood (n=1) (Fig. 1).



**Figure 1.** Anterior segment photograph of an injured eye indicating a corneal perforation by IOFB, and traumatic cataract with ruptured anterior capsule (a). Fundus photograph showing a piece of intraocular foreign body embedded on the retina, with appearance of metallic components surrounded by retinal pigmented endothelial cell atrophy (b). IOFB: Intraocular foreign body.

**Table 1.** Demographics and types of injuries in children with ocular trauma

Variables	n	%
Gender		
Male	13	61.9
Female	8	38.0
Age (mean±SD) (min–max) (years)	8.5±3.4 (3–16)	
Injured eye		
Right	10	47.6
Left	11	52.3
Type of injury		
Closed globe	6	28.5
Contusion	5	
Lamellar laceration	1	
Open globe	15	71.4
Globe rupture	7	
Perforating injury	5	
Penetrating injury	4	
Intraocular foreign body	4	
Cause of injury		
Sharp injury	11	52.3
Knife	5	
Glass	4	
Metallic object	1	
Pen/pencil	1	
Blunt injury	10	47.6
Wood/organic material	4	
Stone	3	
Animal inflicted	1	
Toy	1	
Sport ball	1	

SD: Standard deviation.

**Table 2.** Clinical presentation and treatment of pediatric eye injuries

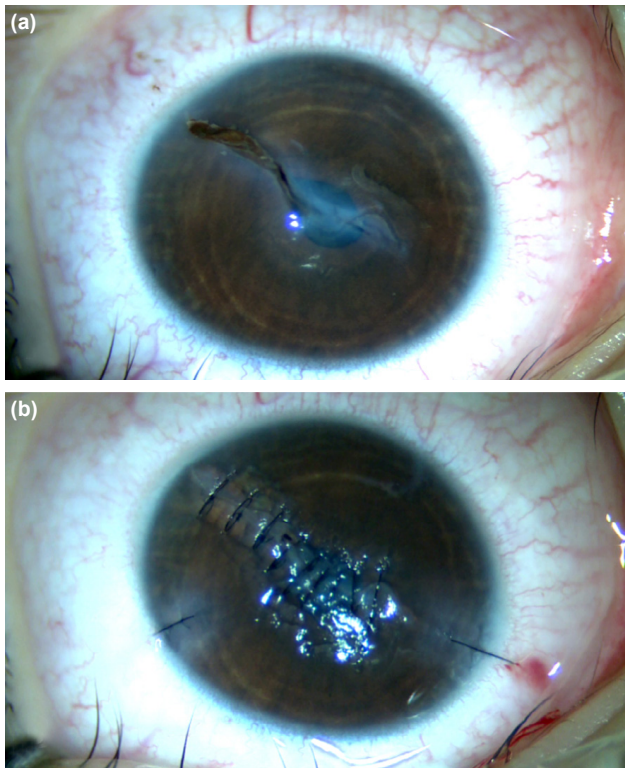
Variables	n	%
Time to admission (mean±SD) (range) (hours)	8.0±1.3 (3–25)	
Time to surgery (mean±SD) (range) (hours)	2±1.0 (1–6)	
Concomitant ocular findings		
Corneal laceration	11	52.3
Retinal detachment	5	23.8
Choroidal hemorrhage	5	23.8
Hyphema	4	19.0
Comotio retinae	3	9.5
Intravitreal hemorrhage	2	9.5
Retinal dialysis	1	4.7
Optic nerve avulsion	1	4.7
Macular hemorrhage	1	4.7
Macular hole	1	4.7
Endophthalmitis	1	4.7
Treatment		
Primary repair	15	71.4
Lensectomy	12	57.1
Pars plana vitrectomy	6	28.5
Intraocular lens implantation	2	9.5
Enucleation	1	4.7

SD: Standard deviation.

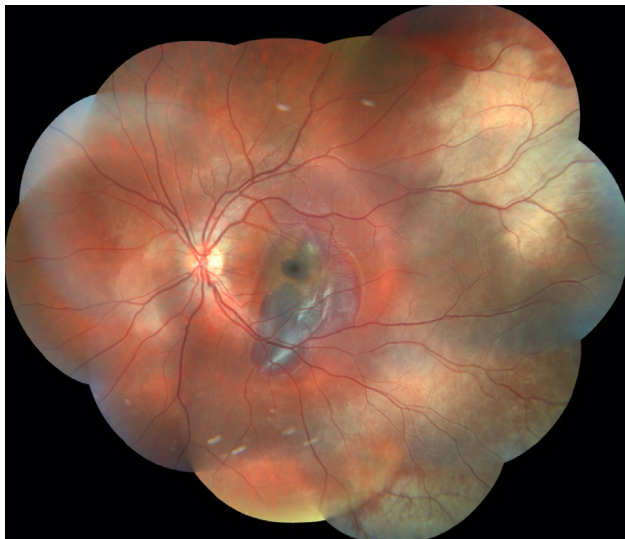Table 2 shows the clinical presentation and treatment of eye injuries. The mean time from trauma to patient admission was 8.0±1.3 h. One patient who had optic nerve avulsion due to blunt trauma came from outside the city and presented later than 24 h after the incident. The mean time from patient admission to the operating room for primary repair was 2±1.0 h. The mean duration of follow-up until the last visit was 8.5±4.5 (range: 6–32) months.

In 11 patients, there was full-thickness corneal laceration that required primary suturation (Fig. 2). Retinal detachment was observed in 6 (28.5%) cases. Of them, 3 had an IOFB, and 2 had sharp injury by knife and glass. The patients underwent pars plana vitrectomy (PPV) and lens aspiration, on average of 10 days (range: 7–16) after primary repair. In these patients, the lens capsule was intact and anterior chamber was quiet.

Thus, combined surgery was performed after the corneal and scleral wounds were healed and corneal clarity was achieved. In 5 patients, there was suprachoroidal hemorrhage determined by B-scan ultrasonography. The most frequent finding was corneal laceration in sharp injury (n=11, 64.7%), and hyphema in blunt injury (n=4, 23.5%). Two cases had intravitreal hemorrhage and PPV was performed on days 15 and 18, consecutively. One patient had proliferative vitreoretinopathy at 3.5 months postoperatively, and he was recommended a repeat PPV. However, the patient did not accept surgery. In 3 cases, commotio retinae has been diagnosed. One of them had concurrent subhyaloid hemorrhage in the macula (Fig. 3). One patient had an edema around the optic disc with splinter hemorrhages and a concurrent macular hole following a blunt wooden stick injury (Fig. 4). Retinal dialysis was observed in one patient injured by stone and treated with C3F8 tamponade and argon laser photocoagulation after vitrectomy (Fig. 5). One patient had a traumatic optic neuropathy secondary to a blunt ball-impact eye trauma. The patient had no light perception and was diagnosed as optic nerve avulsion with positivity of relative afferent pupillary defect and fundus examination. Optic nerve-globe relationship was evaluated by B-scan ultrasonography. Optic nerve separation and widened and altered nerve-globe junction with lamina cribrosa were monitored with orbital MRI, and it was evaluated as partial



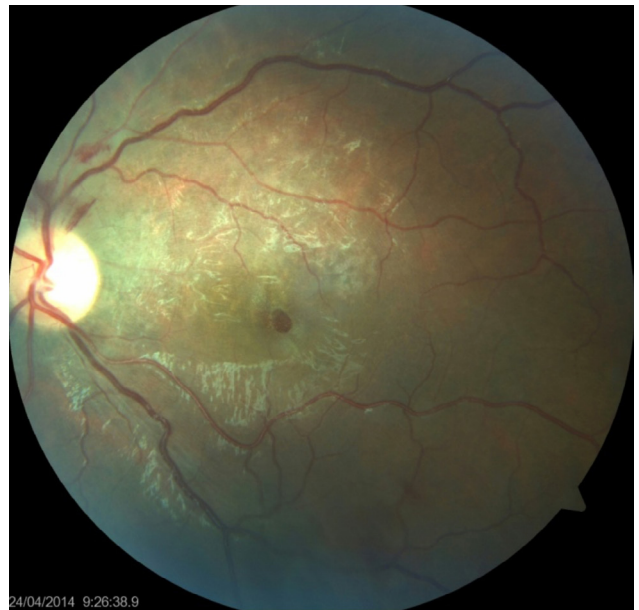**Figure 2.** An 8 year old boy with full-thickness corneal laceration by knife (a). One day postoperatively, the wound was nicely closed with no gape using five 10-0 nylon sutures (b).



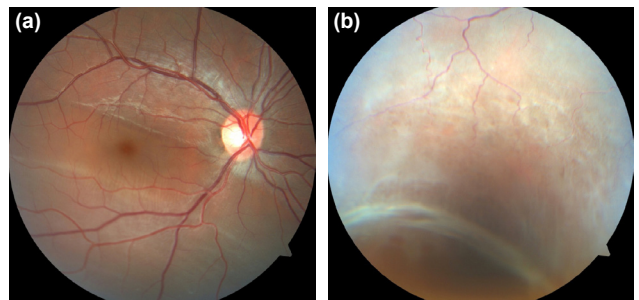
**Figure 3.** Blunt trauma-related ocular injury in a 12-year-old child. Left eye shows commotio-retinae involving the superior and inferior temporal arcade and adjacent macular area with subhyaloid hemorrhage.

optic nerve avulsion. The VEP test was performed at an external center for the patient whose vision did not change during follow-up.

Lens aspiration was performed in 11 (64.7%) cases due to traumatic cataract and/or lens fragmentation. Of them, 3



**Figure 4.** Commotio retinae of the superior macula following blunt trauma. Notable findings include a macular hole and superficial optic disc hemorrhages.



**Figure 5.** Fundus photograph of the right eye showing subretinal fluid and commotio retinae (a) and retinal dialysis located in the inferior and temporal quadrant extending up to the equator (b).

had combined PPV. Two patients had intraocular lens implantation, and 9 (52.9%) had aphakia. In patients with lens implantation, we prescribed pediatric glasses with progressive lenses. Among children with apakhia, 6 children with regular corneal surface had aphakic silicone hydrogel contact lenses, and 3 had glasses with hyperopic refractive correction.

After repair of globe rupture, one eye (5.8%) had the clinical diagnosis of posttraumatic endophthalmitis. This patient had a history of perforation with an organic foreign body. The timeframe for endophthalmitis development was 4 days after repair. Although the vitreous culture was negative, prophylactic systemic, topical and intravitreal antibiotic therapy was applied. However, due to lack of response to treatment, antifungal therapy was initiated because of the high suspicion despite no fungal growth in culture media. The patient underwent enucleation as a result of no response to treatment and development of phthisis bulbi.

**Table 3.** Visual acuity of the patients (n=21) with ocular injury before and after treatment

BCVA	At presentation	At 1 <sup>st</sup> month of follow-up	At last follow-up
NLP	4	2	1
LP-HM	3	3	2
CF	4	9	5
20/400-20/63	5	–	–
20/400-20/40	–	7	–
20/400-20/25	–	–	13
N/A	5	–	–

BCVA: Best-corrected visual acuity; NLP: No light perception; LP: Light perception; HM: Hand motion; CF: Counting fingers; N/A: Non-applicable.

The mean suture removal duration was 2.3 months (range: 1–3). After suture removal, all children were rehabilitated with an appropriate optical correction due to the risk of amblyopia. Eye patching of the non-amblyopic eye was performed in the necessary cases.

We were able to record initial vision in 16 (76.1%) children. Of them, 4 had no light perception, 3 had light perception, and 9 had BCVA between counting fingers and 0.3. BCVA at 1<sup>st</sup> month after treatment was recorded in all 21 children. Of them, 2 eyes (9.5%) had no light perception, 3 (14.2%) had light perception, 9 eyes (42.8%) had counting fingers, and 7 (33.3%) had a mean BCVA of  $0.2 \pm 0.9$  (range: 0.05–0.5). In terms of final visual outcomes, one eye had no light perception due to optic nerve avulsion, 2 had light perception, 5 had counting fingers, and 13 had BCVA of  $0.3 \pm 0.2$  (range: 0.05–0.8) (Table 3).

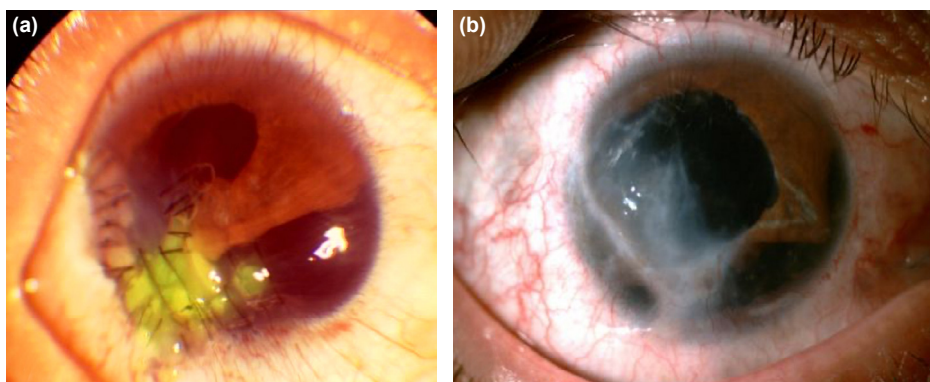
The final IOP was documented in 10 (58.8%) cases. IOP <6 mmHg was identified in 2 (9.5%) cases and >21 mmHg in 4 (19%) cases. In patients with IOP of 21–25 mmHg, topical antiglaucoma treatment, particularly B-blocker, was initiated. Although IOP was controlled in most patients, additional oral

acetazolamide was given in resistant cases. In two patients, topical and oral antiglaucomatous treatment was started because of anterior chamber hyphema. However, due to the lack of sufficient drop, hyphema was cleaned surgically and the pressure was reduced to normal values. Corneal scar was observed in 12 (57.1%) cases, and corneal leukoma was observed in 2 (9.5%) at the final visit (Fig. 6).

## DISCUSSION

This study demonstrated the causes and characteristics of severe eye injuries that require hospitalization in children. We found that injuries with sharp objects occur twice as much as blunt trauma, and decrease vision with residual scarring in two-thirds of the patients.

The mean age of our patients was  $8.5 \pm 3.4$  years, similar to studies conducted on pediatric globe injuries.<sup>[11,12]</sup> It is recognized that one-third of all eye injuries occur due to childhood trauma. Especially in this age group, a child begins school and is often interested in a variety of physical activities. Since children are inexperienced about the forthcoming dangers, such injuries are inevitable if they are not well supervised. Therefore, preventive strategies such as educational support for



**Figure 6.** Sharp ocular trauma in a child causing large corneal perforation including corneascleral junction, iridodialysis, and cataract. The picture shows the cornea immediately following primary suturing (a). Repaired corneal perforation with secondary cataract extraction and scleral fixation intraocular lens implantation. A large corneal scar formation is seen in the follow-up (b).

children and patient awareness are needed in this particular age group.<sup>[13,14]</sup>

Our study showed that traumatic globe injury is more prevalent in males than females which is consistent with previous reports.<sup>[15,16]</sup> Various studies also showed a higher incidence of eye injuries in males.<sup>[5,17]</sup> This pattern of male predominance is explained by the participation of boys in more active and intense activities than girls.

A review of injuries revealed that perforating and penetrating traumas accounted for half of the cases followed by penetrating trauma and IOFB. The mean time from injury to patient admission was 6 h. The majority of the cases (95%) presented to the hospital within 24 h, which is slightly higher than the studies conducted in Nigeria, Egypt, and Pakistan.<sup>[18–20]</sup> In most cases, the time between admission to hospital and surgery was at most 6 h, which may be due to the affordability of rapid response to eye injuries in the two major cities in Turkey.

The majority of the traumatic globe injuries in our study were open globe injuries. Open globe wounds have a worse visual prognosis since they usually require surgery. Unlike adult injuries, the risk of amblyopia also makes visual rehabilitation difficult in childhood trauma. Two-thirds of our study population had accidents with sharp objects, including knife, glass, metallic object, and pen. Other prevalent materials were wood and stone that caused blunt trauma. Previously, knife has been documented as the most frequent culprit of pediatric trauma under age 16.<sup>[12–21]</sup> IOFBs accounted for 20% of open globe injuries and most of them were glass or organic material.

After the primary globe repair, 12 (57%) patients had lensectomy, and 5 (24%) had PPV for IOFB and intravitreal hemorrhage. The development of cataracts as a result of ocular damage is not rare.<sup>[22–24]</sup> Unfortunately, lens injury is an indicator of serious eye damage which can require multiple surgeries and a lengthy period of visual recovery. It is reported that traumatic cataracts in childhood have significantly worse visual outcome than nontraumatic cataracts.<sup>[24]</sup> It is reasonable to perform traumatic cataract surgery as an early procedure in this age group to shorten the period of visual rehabilitation and to start the amblyopic therapy earlier. However, it is also recommended that the traumatic cataract surgery be performed in quiet eyes. Thus, if the lens capsule is intact in the presence of severe corneal damage and edema, it is better to postpone lensectomy for more accurate IOL calculation, better visualization during surgery, less post-operative inflammation, and better assessment of visual improvement after surgery.<sup>[25]</sup> Post-operative rehabilitation with optical correction and occlusion is required to achieve a better visual outcome for the risk of amblyopia.

PPV was administered within a maximum of 18 days after trauma in our series. It is reported that vitrectomy for globe injury should be performed in <4 weeks to decrease the

incidence of traumatic proliferative vitreoretinopathy and preserve eyeball integrity.<sup>[26]</sup> Enucleation was performed in a single patient with no light perception for globe rupture and uncontrolled endophthalmitis. This enucleation rate is lower than studies reported by Farr and Lesniak but higher than the 3% reported by Hill.<sup>[27–29]</sup> Risk factors for endophthalmitis are ruptured lens capsule, dirty wound, IOFB, and injuries in rural settings.<sup>[30]</sup> Post-traumatic endophthalmitis is known to be a poor prognostic factor for the final visual outcome.

Initial VA could not be assessed in approximately a quarter of the patients in this study due to the lack of cooperation. Previous studies report obtaining an initial vision in 75–92% of pediatric patients, compared with 76% in our study.<sup>[29–31]</sup> Since VA is an important parameter in the management of globe injury, the correct assessment of VA is crucial when it comes to making significant decisions on immediate care. At final examination, two-thirds of our patients attained good visual outcome with a VA of 0.05–0.8. However, the mean final VA of  $0.3 \pm 0.2$  showed a significant loss of vision, and 38% of the patients had monocular vision impairment. Anterior segment damage and retinal pathologies were the major causes of visual morbidity in the patients. These findings indicate that despite substantial advancements in microsurgery, pediatric globe injury tends to cause a significant visual disturbance. Visual acuity at final examination in our study was consistent with other studies suggesting that 21–51% of patients maintain VA of 0.5 in the injured eye.<sup>[11,29–32]</sup> In a study conducted by Narang et al.,<sup>[30]</sup> VA  $\geq 0.05$  was attained only in 52% of children. It is proposed that good visual acuity at presentation and early primary repair are essential factors for a better final visual outcome. In general, penetrating injuries have worse visual outcomes relative to blunt injuries, and posterior segment involvement adversely affects visual outcomes.<sup>[33]</sup>

The main limitations in our study were that the study was in a retrospective design, and the reported data were limited to the records of the patients. It was difficult to monitor the variables in the pediatric population, particularly the initial VA was the most common data deficiency. This report also underestimates the total number of hospitalized pediatric eye injuries, as only injuries treated in a tertiary hospital have been included. Patients who had mild self-resolving ocular damage and closed globe injury treated in primary care centers were also omitted. Although our sample size is smaller than other series, our results address an important public health problem and may guide future studies

## Conclusion

The results of this study help us to better understand the pattern of childhood eye injuries. While most eye injuries in children are preventable, they have the potential to cause serious physical and mental sequelae. It should be recognized that visual prognosis in severely traumatized eyes remains

poor. Knowing the most common causes of ocular injury in the pediatric population will be effective in raising public awareness and establishing preventive strategies. A variety of policies and standards for the implementation of educational programs need to be developed to promote eye protection and reduce the incidence of pediatric eye trauma.

**Ethics Committee Approval:** This study was approved by the Baskent University Faculty of Medicine Ethics Committee (Date: 08.12.2020, Decision No: KA20/435).

**Peer-review:** Internally peer-reviewed.

**Authorship Contributions:** Concept: S.A.B.; Design: S.A.B.; Supervision: S.A.B.; Resource: S.A.B.; Materials: S.A.B., G.Y.; Data: S.A.B., Z.K.Ö.; Analysis: S.A.B., Z.K.Ö.; Literature search: Z.K.Ö.; Writing: S.A.B., Z.K.Ö.; Critical revision: G.Y.

**Conflict of Interest:** None declared.

**Financial Disclosure:** The authors declared that this study has received no financial support.

## REFERENCES

- Schein OD, Hibberd PL, Shingleton BJ, Kunzweiler T, Frambach DA, Seddon JM, et al. The spectrum and burden of ocular injury. *Ophthalmology* 1988;95:300–5. [CrossRef]
- Brophy M, Sinclair SA, Hostetler SG, Xiang H. Pediatric eye injury-related hospitalizations in the United States. *Pediatrics* 2006;117:e1263–71. [CrossRef]
- MacEwen CJ, Baines PS, Desai P. Eye injuries in children: The current picture. *Br J Ophthalmol* 1999;83:933–6. [CrossRef]
- Matsa E, Shi J, Wheeler KK, McCarthy T, McGregor ML, Leonard JC. Trends in US emergency department visits for pediatric acute ocular injury. *JAMA Ophthalmol* 2018;136:895–903. [CrossRef]
- Rahman I, Maino A, Devadason D, Leatherbarrow B. Open globe injuries: Factors predictive of poor outcome. *Eye* 2006;20:1336–41. [CrossRef]
- Kuhn F, Morris R, Witherspoon CD, Mester V. The birmingham eye trauma terminology system (BETT). *J Fr Ophtalmol* 2004;27:206–10.
- Abbott J, Shah P. The epidemiology and etiology of pediatric ocular trauma. *Surv Ophthalmol* 2013;58:476–85. [CrossRef]
- Bučan K, Matas A, Lovrić JM, Batistić D, Borjan IP, Puljak L, et al. Epidemiology of ocular trauma in children requiring hospital admission: A 16-year retrospective cohort study. *J Glob Health* 2017;7:010415. [CrossRef]
- Yardley AE, Hoskin AK, Hanman K, Sanfilippo PG, Lam GC, Mackey DA. Paediatric ocular and adnexal injuries requiring hospitalisation in Western Australia. *Clin Exp Optom* 2017;100:227–33. [CrossRef]
- Coody D, Banks JM, Yetman RJ, Musgrove K. Eye trauma in children: Epidemiology, management, and prevention. *J Pediatr Health Care* 1997;11:182–8. [CrossRef]
- Ahmadabadi MN, Alipour F, Tabataei SA, Karkhane R, Rezaei H, Ahmadabadi EN. Sharp-object-induced open-globe injuries in Iranian children admitted to a major tertiary center: A prospective review of 125 cases. *Ophthalmic Res* 2011;45:149–54. [CrossRef]
- Tok O, Tok L, Ozkaya D, Eraslan E, Ornek F, Bardak Y. Epidemiological characteristics and visual outcome after open globe injuries in children. *J AAPOS* 2011;15:556–61. [CrossRef]
- Niiranen M, Raivio I. Eye injuries in children. *Br J Ophthalmol* 1981;65:436–8. [CrossRef]
- Rapaport I, Romem M, Kinek M, Koval R, Teller J, Belkin M, et al. Eye injuries in children in Israel. A nationwide collaborative study. *Arch Ophthalmol* 1990;108:376–9. [CrossRef]
- Kadappu S, Silveira S, Martin F. Aetiology and outcome of open and closed globe eye injuries in children. *Clin Exp Ophthalmol* 2013;41:427–34. [CrossRef]
- Eliacik M, Erdoğan F, Karaman S, Gökkuş D, İpek II. Evaluation of childhood ocular trauma: 5-year single-center experience. *J Pediatr Res* 2014;1:70–5.
- Kusbeci T, Yiğit T, Demirhan E, Çatal Ç, Tezcan S. Epidemiologic evaluation of childhood ocular trauma. *Kocatepe Tıp Derg* 2012;13:153–9.
- Ashaye AO. Eye injuries in children and adolescents: A report of 205 cases. *J Natl Med Assoc* 2009;101:51–6. [CrossRef]
- El-Sebaity DM, Soliman W, Soliman AM, Fathalla AM. Pediatric eye injuries in upper Egypt. *Clin Ophthalmol* 2011;5:1417–23. [CrossRef]
- Jahangir T, Butt NF, Hamza U, Tayyab H, Jahangir S. Pattern of presentation and factors leading to ocular trauma. *Pak J Ophthalmol* 2011;27:96–102.
- Karagöz IK, Sarı ES, Kubaloğlu A, Elbay A, Çallı Ü, Pinero DP, et al. Characteristics of pediatric and adult cases with open globe injury and factors affecting visual outcomes: A retrospective analysis of 294 cases from Turkey. *Ulus Travma Acil Cerrahi Derg* 2018;24:31–8.
- Khokhar S, Gupta S, Agarwal T. Epidemiology and intermediate-term outcomes of open- and closed-globe injuries in traumatic childhood cataract. *Eur J Ophthalmol* 2014;24:124–30. [CrossRef]
- Ram J, Verma N, Chaudhary M. Effect of penetrating and blunt ocular trauma on the outcome of traumatic cataract in children in northern India. *J Trauma Acute Care Surg* 2012;73:726–30. [CrossRef]
- Shah MA, Shah SM, Shikhanje KA. Visual outcome of traumatic cataract in pediatric age group. *Eur J Ophthalmol* 2012;22:956–63. [CrossRef]
- Gogate P, Sahasrabudhe M, Shah M, Patil S, Kulkarni A. Causes, epidemiology, and long-term outcome of traumatic cataracts in children in rural India. *Indian J Ophthalmol* 2012;60:481–6. [CrossRef]
- Feng K, Hu YT, Ma Z. Prognostic indicators for no light perception after open-globe injury: Eye injury vitrectomy study. *Am J Ophthalmol* 2011;152:654–62.e2. [CrossRef]
- Farr AK, Hairston RJ, Humayun MU, Marsh MJ, Pieramici DJ, MacCumber MW, et al. Open globe injuries in children: A retrospective analysis. *J Pediatr Ophthalmol Strabismus* 2001;38:72–7. [CrossRef]
- Lesniak SP, Bauza A, Son JH, Zarbin MA, Langer P, Guo S, et al. Twelve-year review of pediatric traumatic open globe injuries in an urban U.S. population. *J Pediatr Ophthalmol Strabismus* 2012;49:73–9. [CrossRef]
- Hill JR, Crawford BD, Lee H, Tawansy KA. Evaluation of open globe injuries of children in the last 12 years. *Retina* 2006;26 Suppl 7:S65–8.
- Narang S, Gupta V, Simalandhi P, Gupta A, Raj S, Dogra MR. Paediatric open globe injuries. Visual outcome and risk factors for endophthalmitis. *Indian J Ophthalmol* 2004;52:29–34.
- Grieshaber MC, Stegmann R. Penetrating eye injuries in South African children: Aetiology and visual outcome. *Eye* 2006;20:789–95. [CrossRef]
- Gupta A, Rahman I, Leatherbarrow B. Open globe injuries in children: Factors predictive of a poor final visual acuity. *Eye* 2009;23:621–5. [CrossRef]
- Jandek C, Kellner U, Bornfeld N, Foerster MH. Open-globe injuries in children. *Graefes Arch Clin Exp Ophthalmol* 2000;238:420–6. [CrossRef]

ORIJİNAL ÇALIŞMA - ÖZ

## Çocukluk çağı göz yaralanmalarının klinik özellikleri ve tedavi sonuçları

Dr. Sezin Akça Bayar,<sup>1</sup> Dr. Zeynep Kayaarası Öztürker,<sup>2</sup> Dr. Gürsel Yılmaz<sup>1</sup>

<sup>1</sup>Başkent Üniversitesi Ankara Hastanesi, Göz Hastalıkları Anabilim Dalı, Ankara

<sup>2</sup>Başkent Üniversitesi İstanbul Hastanesi, Göz Hastalıkları Anabilim Dalı, İstanbul

**AMAÇ:** Çocukluk çağı göz yaralanmaları edinsel tek taraflı körlüğün en yaygın nedenlerinden biridir. Bu çalışmada çocukluk çağı göz yaralanmalarının nedenleri, hastaların demografik özellikleri ve tedavi sonuçlarının değerlendirilmesi amaçlanmıştır.

**GEREÇ VE YÖNTEM:** Bu geriye dönük çalışmada Başkent Üniversitesi Hastanesi Göz Klinikleri'ne 1 Ocak 2017–31 Aralık 2019 tarihleri arasında başvuran oküler travmalı çocuklar değerlendirildi. Çalışmaya 16 yaşın altındaki tüm hastalar dahil edildi. Olgular yaş, cinsiyet, travmanın zamanı, yaralanma tipi, eşlik eden yaralanmalar, tedavi, görme bozukluğu, göz içi basıncı (GİB) ve gelişen oftalmik sekeller açısından değerlendirildi. Oküler travmalar, Birmingham Göz Travma Terminolojisi (BETT) sistemine göre sınıflandırıldı.

**BULGULAR:** Çalışmaya toplam 21 hasta alındı. Erkek-kadın oranı 13/8 idi. Hastaların ortalama yaşı  $8.5 \pm 3.4$  idi. Ortalama tedavi sonrası takip  $8.2 \pm 4.3$  aydı. Olguların tümünde yaralanma tek taraflı idi (10 sağ göz, 11 sol göz). On beş hastada (%71.4) açık glob yaralanması ve altı hastada (%28.5) kapalı glob yaralanması mevcuttu. Yedi olguda rüptür, beş olguda perforasyon, dört olguda penetrasyon ve dört olguda göz içi yabancı cisim tespit edildi. Takip süresi boyunca beş olguda retina dekolmanı saptandı. On bir (%52.3) olguda kesici tarzda, 10 (%47.6) olguda künt tarzda yaralanma görüldü. En sık eşlik eden bulgular perforan yaralanmada kornea laserasyonu ve künt yaralanmada hifema idi. Beş olguda koroidal hemoraji, üç olguda kommosyo retina, iki olguda vitre içi kanama, bir olguda retina diyalizi, bir olguda makulada subhyaloidal hemoraji, bir olguda makula deliği ve bir olguda optik sinir avulsiyonu saptandı. On iki (%57.1) olguya lensektomi uygulandı ve bunların ikisine göz içi lens implantasyonu yapıldı. İlk başvuruda görme keskinliği alınabilen çocukların dördünde ışık persepsiyonu yoktu. Yedi olguda görme ışık persepsiyonu ve parmak sayma düzeyindeydi. Beş hastada en iyi düzeltilmiş görme keskinliği (EİDGK) 0.05–0.3 arasında idi. Son kontrolde, olguların %61.9'unda EİDGK 0.05–0.8 düzeyinde idi. Takip sonunda 14 (%66.6) olguda korneada skar, veya lökom izlendi. Bir olguya tedaviye yanıt vermeyen posttravmatik endoftalmi nedeniyle enükleasyon uygulandı. Son muayenede, iki olguda GİB  $<6$  mmHg, dört olguda GİB  $>21$  mmHg idi.

**TARTIŞMA:** Çocukluk çağı göz yaralanmalarında ön segment hasarı, görme azlığının başlıca nedenidir. Keskin nesnelere olan yaralanmalar, künt travmaya göre iki kat daha sık meydana gelir ve hastaların yaklaşık üçte ikisinde korneada rezidüel yara izi ile görmeyi azaltır. Travmaların özelliklerinin bilinmesi çocuk göz sağlığını korumak açısından gerekli olan stratejilerin belirlenmesinde faydalı olacaktır.

**Anahtar sözcükler:** Görme keskinliği; göz travması; pediatrik oftalmoloji.

Ulus Travma Acil Cerrahi Derg 2022;28(5):654-661 doi: 10.14744/tjtes.2021.54524