



## Ductal Adenocarcinoma: A Rare Entity of Prostate Gland in a Chronic Lymphocytic Leukemia/Small Lymphocytic Lymphoma Patient

### Kronik Lenfositik Lösemi/Küçük Hücreli Lenfositik Lenfomalı Bir Hastada Prostatın Nadir Bir Antitesi: Duktal Adenokarsinoma

KLL/SLL'li Bir Hastada Prostatın Duktal Adenokarsinoma / Prostatic Ductal Adenocarcinoma in a CLL/SLL Patient

Tumay Ozgur<sup>1</sup>, Murat Mehmet Rifaioğlu<sup>2</sup>, Ahmet Taner Sümbül<sup>3</sup>, Füsün Aydoğan<sup>4</sup>, Nesrin Atıcı<sup>5</sup>

<sup>1</sup>Pathology Department, Mustafa Kemal University, School of Medicine, <sup>2</sup>Urology Department, Mustafa Kemal University, School of Medicine, <sup>3</sup>Oncology Department, Adana Başkent University, School of Medicine, <sup>4</sup>Nuclear Medicine Department, Mustafa Kemal University, School of Medicine, <sup>5</sup>Radiology Department, Mustafa Kemal University, School of Medicine, Hatay, Turkey

*This case was presented as a poster in Avrasian Urooncology congress in 2015.*

#### Özet

Prostat kanseri erkeklerde en sık gözlenen prostat malignansilerindedir ve duktal adenokarsinom klinik ve histolojik özellikleri ile belirgin patolojik bir subtipidir. Yetmiş altı yaşında Kronik lenfositik lösemi/Küçük hücreli lenfositik lenfomalı (KLL/SLL) erkek hasta alt üriner sistem semptomları ile hastanemize başvurdu. Son prostat spesifik antijen seviyesi (PSA) 26 ng/ml ile bir çok transrektal ultrason ve rehberliğindeki biopsiler uygulandı ve patoloji raporları benign prostat hiperplazisi ve non-spesifik prostatit olarak sonuçlandı. Semptomların devam etmesi üzerine prostata transuretral rezeksiyon uygulandı. Materyalin patolojik değerlendirilmesinde benign hiperplazik prostat dokuları arasında stroması olmayan adenokarsinom odakları gözlemlendi. Tümör 4+4 Gleason patern skoru ile duktal adenokarsinom olarak tanı aldı. Metastaza bağlı lomber vertebrada kemik sintigrafisinde aktivite tutulumu vardı. Bilgisayarlı tomografide önceki KLL/SLL 'ye bağlı inguinal ve sağ iliak lenfadenopati izlendi. Total androjen kısıtlama tedavisi ve bilateral orşiektomi uygulandı. 3 ay sonra biokimyasal ve radyolojik görüntüleme sonuçlarına göre radyoterapi tedavisi planlandı. Duktal adenokarsinoma konvansiyonel adenokarsinomdan farklı klinik davranışı olan prostatın nadir bir subtipidir. Diğer yandan KLL/SLL takibi yapılan bir hastada sekonder bir malignensi olarak ortaya çıkması olguyu değerli kılmaktadır.

#### Anahtar Kelimeler

Duktal Adenokarsinoma; KLL/SLL; Prostat

#### Abstract

Prostate cancer is the most common malignancy in men and ductal adenocarcinoma is a pathologic subtype with specific histological and clinical features. Seventy-six year-old male patient with chronic lymphocytic leukemia/small lymphocytic lymphoma (CLL/SLL) admitted to our hospital with lower urinary tract symptoms. The last prostate specific antigen (PSA) level was 26 ng/ml and serial transrectal ultrasound guided biopsies were administered and benign prostate hyperplasia and non-specific prostatitis were the results of pathology reports. Due to the persistence of the symptoms transurethral resection of the prostate was performed. In the pathologic evaluation of the material adenocarcinoma focuses without stroma has been observed between the hyperplastic prostate tissues. The tumor has been diagnosed as ductal adenocarcinoma with 4+4 Gleason pattern score. Bone scintigraphy was revealed activity uptake on lumbar vertebral column due to metastasis. Computerized tomography was revealed previous bilateral inguinal and right iliac lymphadenopathy due to CLL/SLL. Total androgen deprivation therapy and bilateral orchiectomy was applied. After three months according to biochemical and imaging results, radiotherapy cure began. Ductal adenocarcinoma is a rare subtype of prostate carcinoma with clinical behavior from that seen in conventional adenocarcinoma. On the other hand it is worth to point out the occurrence of this entity as second malignancy during follow-up of CLL/SLL.

#### Keywords

CLL/SLL; Ductal Adenocarcinoma; Prostate

DOI: 10.4328/JCAM.3560

Received: 11.05.2015 Accepted: 23.05.2015 Published Online: 24.05.2015

Corresponding Author: Tumay Ozgur, Pathology Department, Mustafa Kemal University, School of Medicine, 31100, Serinyol, Hatay, Turkey.  
T.: +90 3262291000-3329 F.: +90 3262455654 E-Mail: ozgurtumay@yahoo.com

## Introduction

Ductal adenocarcinoma (DA) of the prostate is a rare histologic subtype of prostate cancer that was first defined by Melicow et al. as endometrial carcinoma of prostatic utricle in 1967 [1]. Prostate specific antigen levels (PSA) seem to be in normal levels and the behaviour of the tumor is uncertain [2].

DA usually presents with aciner adenocarcinoma and the pure form is rare constituting 0.4-0.8 % of all radical prostatectomy and biopsy specimens [3]. It may be misdiagnosed as various benign, precancerous and malign lesions like prostatic urethral polyps, high grade prostatic intraepithelial neoplasia (HG-PIN) and colorectal adenocarcinoma.

Prostatic DA may originate either from large primary periurethral prostatic ducts or rarely from peripheral prostatic ducts [4].

We would like to describe our case which we diagnosed in transurethral resection specimen incidentally as DA with mild PSA levels and prostatism symptoms in a chronic lymphocytic leukemia/small lymphocytic lymphoma (CLL/SLL) patient.

## Case Report

Seventy-six year-old male patient with CLL/SLL admitted to Mustafa Kemal University hospital Urology department outpatient clinic with lower urinary tract symptoms. Prostate gland was 90 gram in ultrasonography (US) examination. The last total PSA and free PSA level was 23.3 and 5.7 ng/ml, respectively and three consecutive twelve core transrectal ultrasound guided biopsies were administered and benign prostate hyperplasia and non-specific prostatitis were the results of pathology reports. Due to the persistence of the symptoms transurethral resection of the prostate (TURP) was performed, during TURP procedure there was a papillary lesion protruded from right apex of the prostatic urethra and the material has been sent to pathology laboratory. In the microscopic evaluation of the specimen adenocarcinoma focuses without stroma has been observed between the hyperplastic prostate tissues (Figure 1). The nuclear morphology was different from classic acinar adenocarcinoma. To confirm the diagnosis and differentiate it from metastatic tumors an immunohistochemical panel was applied. While CK7, CK20 were negative, PSA and AMACR were positive in immunohistochemical studies (Figure 2-3). The tumor has been diagnosed as ductal adenocarcinoma with 4+4 Gleason pattern score. Bone scintigraphy was revealed activity uptake on lumbar vertebral column. Computerized tomography was revealed previous bilateral inguinal and right iliac lymphadenopathy due to CLL. Total androgen deprivation therapy and orchiectomy was applied, after three mounts according to biochemical and imaging results, radiotherapy cure was began.

## Discussion

Prostatic DA is a rare variant most commonly growing as exophytic mass lesions in the uretra. There are various mimickers of this entity that it should be recognised by pathologists and uropathologists in daily practice [4].

DAs are often localised at the central ducts of the gland. Therefore they are usually seen in TURP and radical prostatectomy specimens and less diagnosed in needle biopsies. Our case had also two serial transrectal US guided biopsies but final proce-

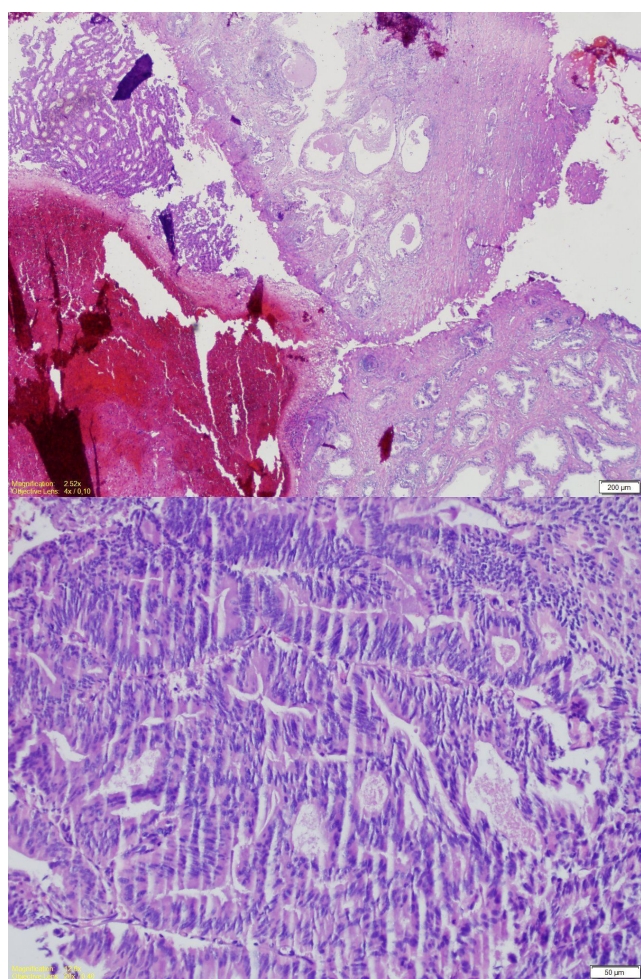


Figure 1-2. Adenoid and cribriform structures with atypical columnar epithelium without stroma between the benign prostate glands (Hematoxylin&EosinX200).

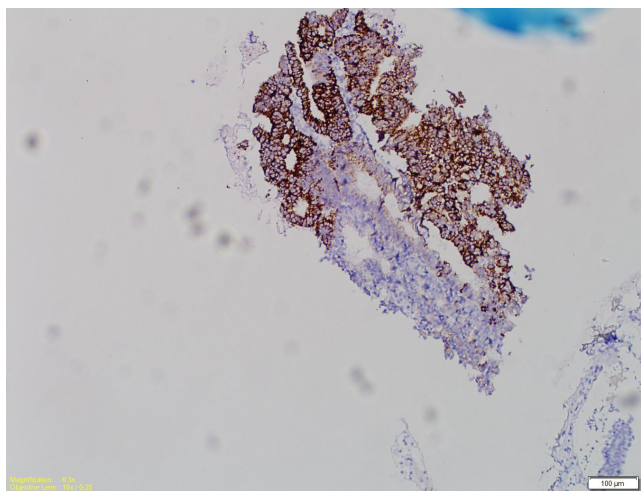


Figure 3. AMACR positivity in tumor cells (AMACRX100).

cedure with TURP demonstrated the tumor. Sfoungaristos et al. reported an 82 year old Caucasian man with DA that was diagnosed in TURP specimen like our case [5].

DA is seen in elderly man with a range of 65 to 87 with obstructive symptoms and gross hematuria [6]. Our patient was 76 years old at the time of diagnosis and admitted to our clinic with lower urinary tract symptoms.

DA cells express PSA but PSA levels are not always high in these tumors as in our patient (26 ng/ml) that could be in inflammation or hyperplasias of the gland.

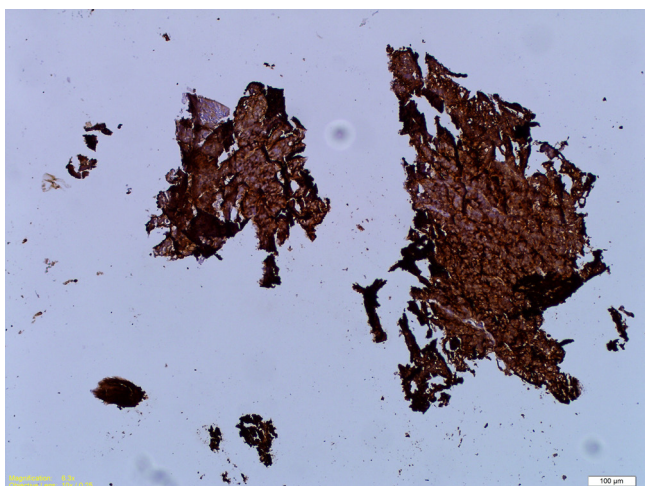


Figure 4. PSA positivity in tumor cells (PSAX100).

The cystourethroscopic appearance of DA is described as exophytic and polypoid mass projecting into the uretra or near the verumontanum [6]. Kan et al. defined 10 of their cases as intra luminal growth masses during cystoscopy in their review of Hong Kong DA series [2]. We have observed an exophytic mass lesion projecting into the lumen at the prostate apex with right wall laterilization.

DA has benign and malign mimickers. Prostatic urethral polyp is a polipoid lesion lined by benign appearing prostatic glandular epithelium and it can be confused with DA in fragmentated needle biopsies. HG-PIN cribriform type is a difficult entity that should be remembered in differential diagnosis. HG-PIN constitutes with micropapillary cores while DA presents with true papillary cores. Beside this DA is recognisable with distinct atypia and large, back to back glands and usually comedonecrosis. DA might be confused with colorectal carcinoma metastasis. The verification of the diagnosis need immunohistochemical studies like PSA and PSAP. Another tumoral lesion that we should remember is papillary urothelial carcinoma in differential diagnosis; the cribriform architecture of DA is missing and nuclei of the tumor cells are more pleomorphic [4]. In the microscobic evaluation of the specimen we have found tumor composed of cribriform and adenoid structures with atypical columnar cells between the hyperplastic prostatic tissues. We have immunostained the tumoral tissue by Cytokeratin 7 and 20, AMACR, P63 and PSA. While Cytokeratin 7, 20 were negative, AMACR and PSA were strong and diffuse positive confirming our diagnosis of prostatic DA. P63 was diminished in neoplastic ducts.

In the literature DA is defined as a more aggressive neoplasm compared to aciner adenocarcinoma. DA is mostly graded as 4+4= 8 whereas in cases of mixed ductal and aciner patterns ductal component should be assigned to Gleason patern 4 according to Gleason histopathologic scoring system [2]. We have also reported our case as 4+4=8 with its morphologic architecture and ductal differentiation.

Kan et al. reported bone and rectum invasions in 7 of their 20 DAs [2]. Our patient has lomber vertebra metastasis and alive receiving radiotherapy with no morbidity.

Engin et al. declared the incidence of multipl primary cancers as 0.83% among cancer patients [7]. CLL/SLL patients are candidates for developing a second cancer and an increased frequency of certain cancer types twice times more compared

to normal population because of disease or therapy related immunosuppression. Tsimberidau et al. reported prostate carcinoma synchronous with CLL in 12.8 % of their series [8]. Our patient is also under follow-up for CLL/SLL for three years and developed DA after two years.

DA of the prostate has unique morphological, clinical features and aggressive behaviour. It should be remembered in cases with non-specific pathologic findings in periferic prostate biopsies of patients with persisant lower urinary tract symptoms. We should also point out this rare entity with its occurrence during CLL/SLL follow-up.

#### Competing interests

The authors declare that they have no competing interests.

#### References

1. Melicow MM, Pachter MR. Endometrial carcinoma of prostatic utricle (uterus masculinus). *Cancer* 1967;20(10):1715-22.
2. Kan RWM, Kan CF, Wong JHM, Fu KK, Ng CF, Chan SW. Ductal adenocarcinoma of the prostate: a Hong Kong case series. *Int Urol Nephrol* 2014;46:2133-37.
3. Greene LF, Farrow GM, Ravits JM, Tomera FM. Prostatic adenocarcinoma of ductal origin. *J Urol* 1979;121:303-5.
4. Epstein JI. Prostatic ductal adenocarcinoma: A Mini Review. *Medl Princ Pract* 2010;19:82-5.
5. Sfoungaristos S, Katafigiotis IS, Tyrizis S, Kavouras A, Kanatas P, Petas A. An 82-year-old Caucasian man with a ductal prostate adenocarcinoma with unusual cystoscopic appearance: a case report. *J Med Case Rep* 2011; 5:4.
6. Brinker DA, Potter SR, Epstein JI. Ductal adenocarcinoma of the prostate diagnosed on needle biopsy: correlation with clinical and radical prostatectomy findings and progression. *Am J Surg Pathol* 1999;23:1471-9.
7. Engin K. Cancers in multipl primary sites. *Int Surg* 1994;79:33-7.
8. Tsimberidou AM, Wen S, McLaughlin P, et al. Other malignancies in chronic lymphocytic leukemia/small lymphocytic lymphoma. *J Clin Oncol* 2009; 27:904-10.

#### How to cite this article:

Ozgur T, Rifaioğlu MM, Sünbül AT, Aydoğan F, Atıcı N. Ductal Adenocarcinoma: A Rare Entity of Prostate Gland in a Chronic Lymphocytic Leukemia/Small Lymphocytic Lymphoma Patient. *J Clin Anal Med* 2015; DOI: 10.4328/JCAM.3560.