



CASE REPORT

Extraction Orthodontic Treatment in an Autistic Patient

Ömür Polat Özsoy, Sinem İnce Bingöl

Department of Orthodontics, Başkent University School of Dentistry, Ankara, Turkey

ABSTRACT

Autism is a condition that restricts brain development. Early diagnostic criteria are as follows: less responsive to social stimuli, inability to develop natural speaking skills, lack of communication skills, and limited and repetitive behaviors. Orthodontic treatment is a challenging process for doctors in autistic patients. The clinical and cephalometric examination of a 17-year and 7-month-old autistic patient revealed class I malocclusion, increased vertical dimensions, proclined upper and lower incisors, and inconsistent lip closure. The treatment plan involved four premolar extractions from each quadrant. Upper and lower 1. premolar extraction with fixed treatment caused reduction in vertical dimensions and significant improvement in lip closure and incisor inclination. Due to the increased metabolic activity in these patients, treatment was completed in 13 months. As a result, autistic patients can be successfully treated. In this process, it is important to include communication as a major part of treatment.

Keywords: Autism, extraction treatment, fixed appliances

INTRODUCTION

Autism spectrum disorder (ASD), which is a condition that restricts brain development, begins before the age of three and continues throughout life. It impacts a person's social interaction, communication skills, and cognitive functions. Autistic patients have limited and repetitive behaviors. In 2009, the Centers for Disease Control and Prevention announced that approximately 1 in 100 eight-year-old children have ASD (1).

Early diagnostic criteria for autism are as follows: less responsive to social stimuli, inability to develop natural speaking skills, lack of language and communication skills, and limited and repetitive behaviors. Autistic children are difficult to treat due to the lack of communication during dental health care. It is also known that orthodontic treatment is a challenging process for doctors in autistic patients due to reduced patient cooperation. In addition, as malocclusion is more prevalent in autistic individuals than in the general population, the needs of orthodontic treatment are higher in autistic children (2).

Angle class I malocclusion is the most prevalent malocclusion that is caused by spacing, crowding, congenitally missing teeth, rotations, and over or under eruption. Class I malocclusions can be seen with vertical plane anomalies such as deep bite and open bite and transverse plane anomalies such as cross bite and buccal nonocclusion. In this case report, the clinical treatment of an autistic patient with class I malocclusion and crowding is presented.

CASE PRESENTATION

A 17-year-old male was referred to the Department of Orthodontics at Başkent University School of Dentistry. He was previously diagnosed as having ASD. During his initial clinical examination, he was very uncomfortable in the hospital environment. His parents informed us that he did like to hear order sentences such as "Listen to me." After the preliminary evaluation, we decided to take diagnostic records at the next visit to give him time to get acquainted to the environment. At the next visit, he was more cooperative, and orthodontic records containing extraoral, intraoral photos, and study models were taken. His intraoral clinical examination indicated that he had a super class I molar and canine relationship, severe crowding in both arches, upper midline shift to the right side, dental rotations, and increased overjet. Further, all his permanent teeth, including his third molars, had

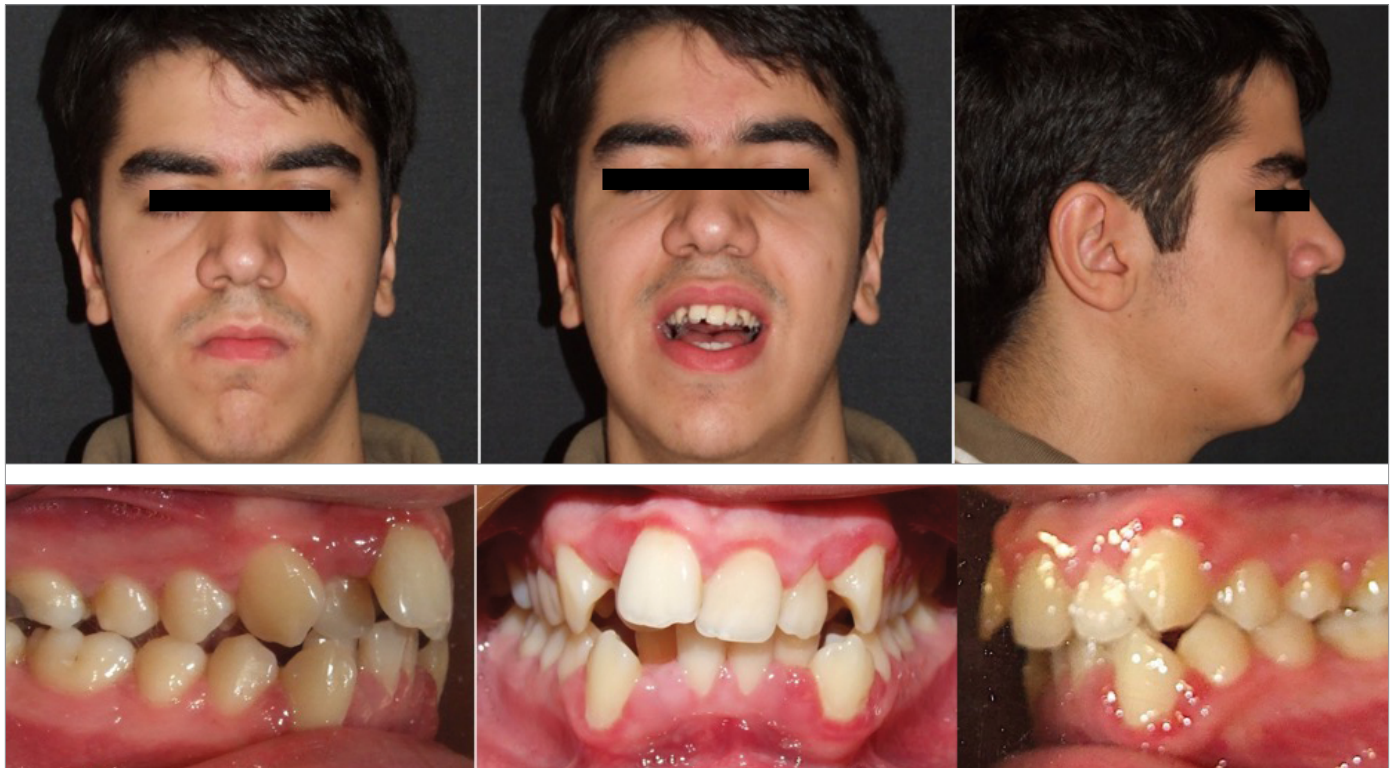

Figure 1. Pretreatment extra- and intraoral records (T1)

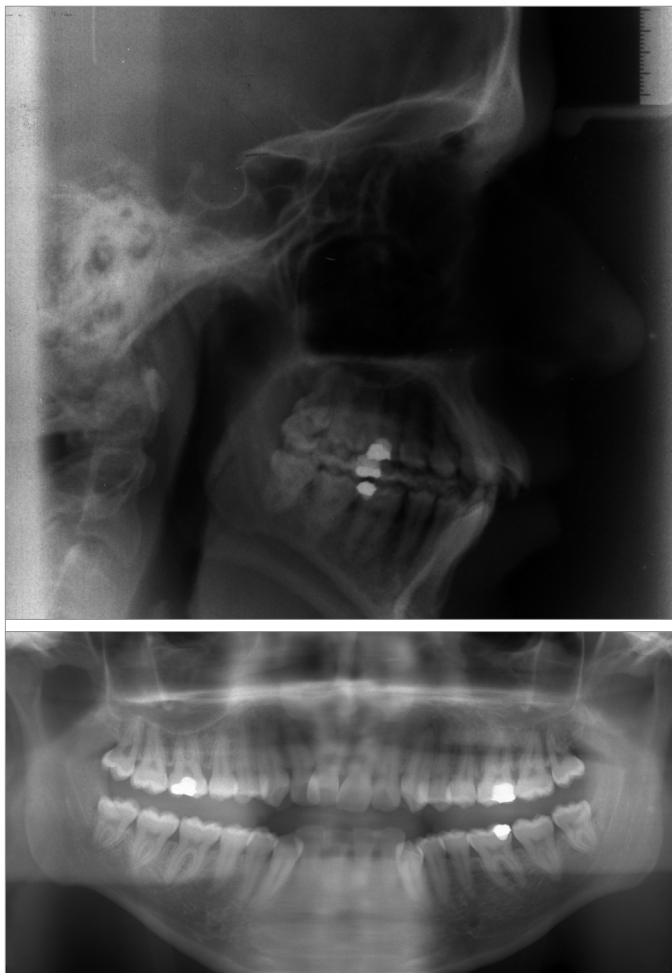


Figure 2. Pretreatment panoramic and lateral cephalometric films

Table 1. Pre- and post-treatment cephalometric measurements

	Norm values	T1	T2
SNA (°)	80±2	79	80
SNB (°)	78±2	75	76
ANB (°)	2±2	4	4
GoGnSN (°)	32±6	38	35
Gonial angle (°)	130±7	136	132
ANS-Me (mm)	71	79	77
U1-NA (°)	22±5	40	19
U1-NA (mm)	4	10	4
IMPA (°)	90±3	86	88
L1-NB (mm)	4	7	6
Upper lip (mm)	-4	-4	-4
Lower lip (mm)	-2	0	0
Overjet (mm)	3	8	3
Overbite (mm)	3	0	3

SNA: sella-nasion- A point angle; SNB: sella-nasion- B point angle; ANB: A point, nasion, B point; GoGnSN: Angle that is measured at the junction of the planes Gonion to Gnathion and Sella-Nasion; ANS-ANS-Me: Distance between ANS and Me points; IMPA: incisor mandibular plane angle; U1-U1:NA: Angle between upper incisor inclination and NA plane; L1-NB: Angle between lower incisor inclination and NB plane

erupted. His extraoral examination revealed that he had a dolichocephalic facial type with a convex profile, protrusive lower lip, and inconsistent lip closure with mental muscle hyperactivity (Figure 1a-h).

Lateral cephalometric and panoramic radiographs were obtained. Cephalometric analysis revealed a skeletal class I relation-

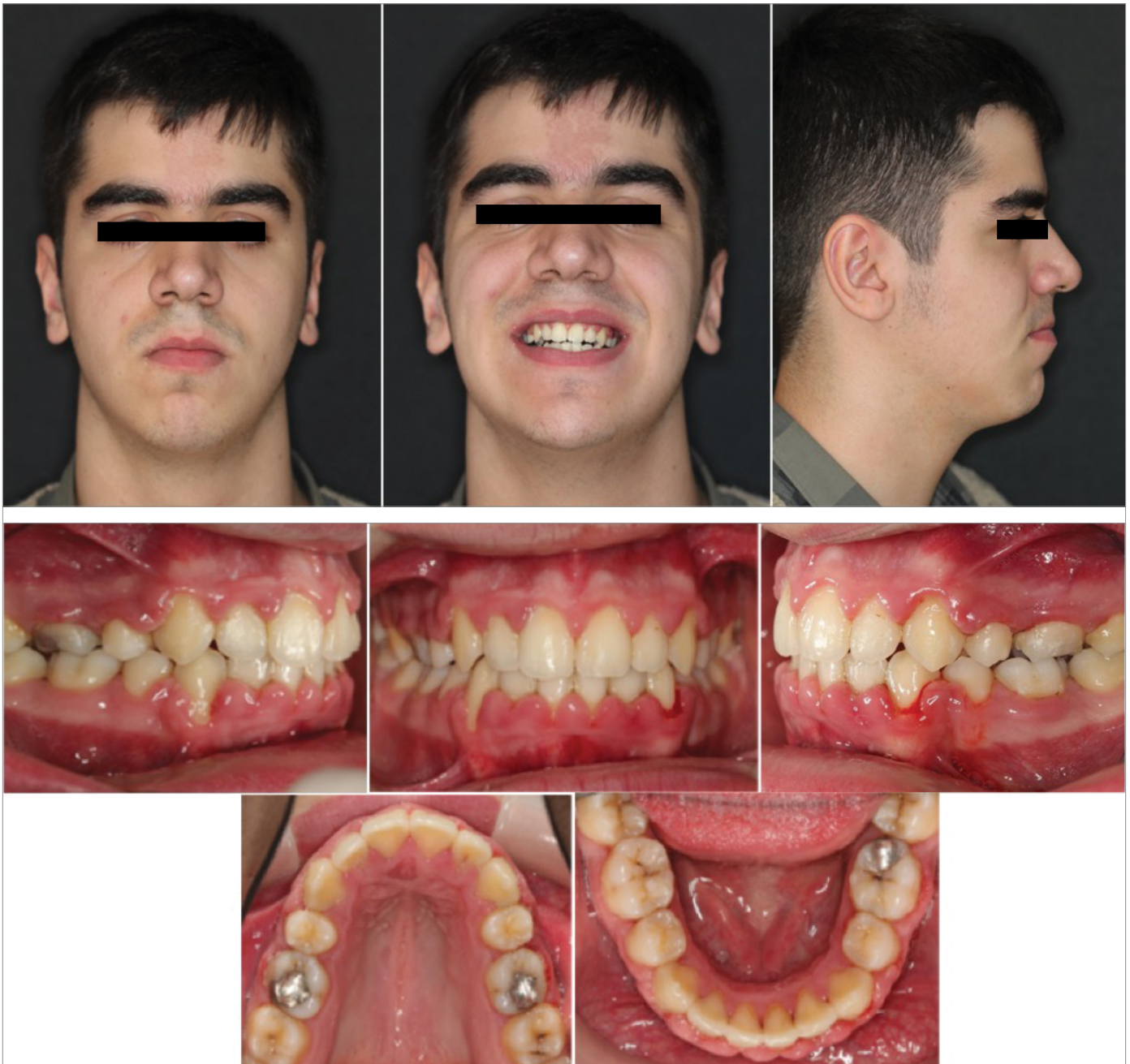


Figure 3. Post-treatment extra- and intraoral records (T2)

ship, proclined upper and lower incisors, and increased vertical dimensions (Figure 2). Cephalometric measurements are shown in Table 1.

The treatment goals were to improve the class I molar and canine relationship, eliminate dental crowding, and obtain ideal overjet and overbite. The treatment plan involved four premolar extractions from each quadrant to achieve the goals. Written informed consent was obtained from patients' parents for the publication of treatment results.

Treatment Sequence

After the extractions, 0.018 slot edgewise brackets with an MBT prescription were bonded. Canines were distalized using lab-backs. No retraction arches were placed, and the remaining

spaces were closed using a closed power chain. Due to cooperation issues, no intermaxillary elastic was used during treatment. Treatment was completed in 13 months.

Gingival inflammation due to poor oral hygiene was the main problem faced during treatment. The patient had some difficulty in focusing on problematic areas; therefore, his parent tried to aid him during brushing.

After treatment, the patient had a class I molar and canine relationship, improvement in lip closure, and compatible midlines (Figure 3a-h). Pre- and post-treatment cephalometric measurements are shown in Table 1. The post-treatment panoramic radiograph showed proper root parallelism, and there was no sign of root resorption (Figure 4). Essix retain-

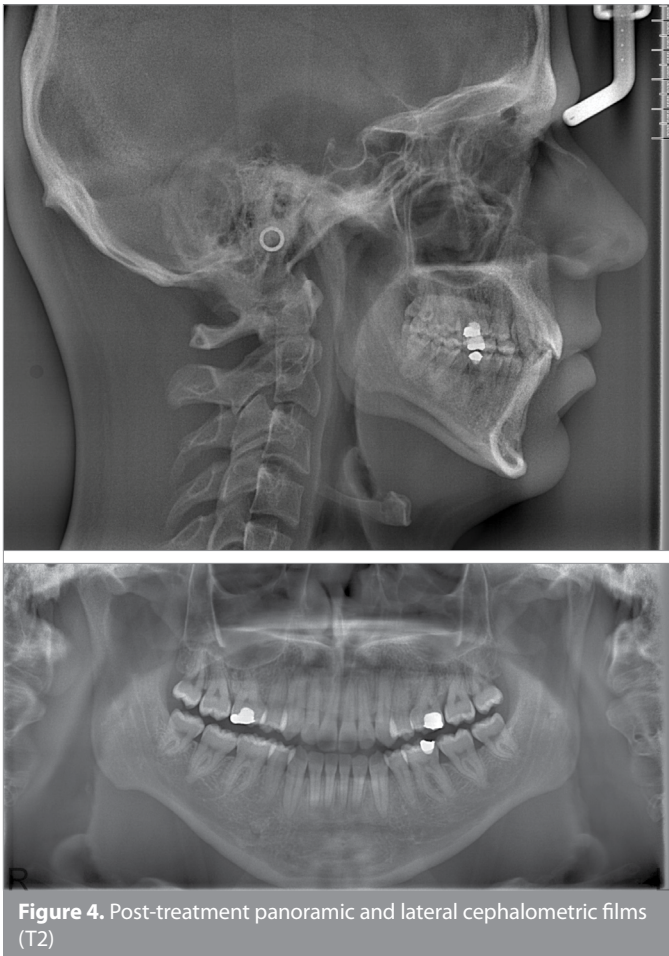


Figure 4. Post-treatment panoramic and lateral cephalometric films (T2)

ers were used for retention, and the patient was instructed to wear them full time for 6 months and night time for another 6 months. The superimposition of pre- and post-treatment lateral cephalometric radiographs showed retroclination of the upper and lower incisors and mesialization of the upper and lower molars (Figure 5).

DISCUSSION

Autism spectrum disorder limits social interaction, communication skills, language skills, and cognitive functions. Autistic patients have limited and repetitive behaviors. There are many difficulties in performing orthodontic treatment to eliminate malocclusion in autistic patients due to the fact that orthodontic treatment is not a single-session treatment and needs cooperation. It also needs a long chair time, particularly during bonding procedures. It can be painful during the initial stages of treatment, and it may be difficult to get used to braces in the mouth even for normally developing patients. Hygiene problems are also an obstacle for patients with special needs.

Chaushu and Becker (3) have stated that several problems may arise during the treatment of patients with special needs. Reduced understanding and increased anxiety, short attention periods, and limited tolerance are among the main problems. Such patients have difficulties in controlling limb and head movements, and they may be unable to sit on dental chairs.

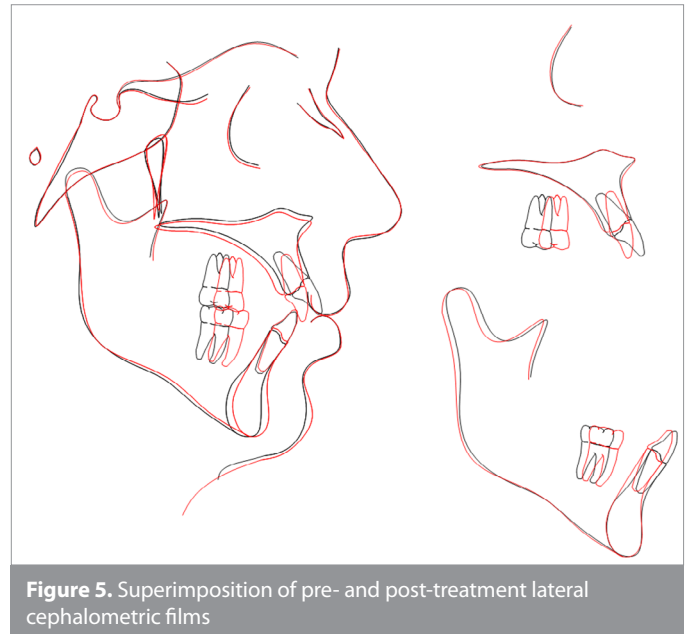


Figure 5. Superimposition of pre- and post-treatment lateral cephalometric films

Moreover, decreased cooperation levels and exaggerated gag reflexes are complications when performing routine procedures (4).

During the treatment of the patient mentioned in this paper, every detail and step was explained to the patient using simple sentences until he was calm enough to undergo treatment. The clinician aimed to gain the trust of the patient right from the start of treatment. The tell-show-do technique, voice control, positive reinforcement, and behavior modification helped improve his acceptance to the orthodontic treatment (5). When he got excited or frightened, he started to sing his favorite songs, but he did not like to hear someone else singing. Special attention was given to relax him.

Kamen and Skier (6) indicated that the use of a physical restraint was unnecessary and ineffective in managing problematic behaviors. Other investigators reported that the use of restraint boards had a calming effect on patients (7,8). This theory has been adapted from literature on occupational therapy, which indicated that experiencing deep pressure can be calming to the sensory systems of people with ASD, justifying the use of a restraint board (9,10). On the other hand, our patient had moderate behavior problems with orthodontic treatment; therefore, we did not use a physical restraint as there was no need for it (11,12).

No other previous reports were found on the orthodontic treatment of an autistic patient with extractions in the orthodontic literature. In our patient, treatment was completed in 13 months, which was markedly shorter than usual extraction treatments (13,14). It was previously reported that boys with ASD have a lower bone mineral density than controls (15). The shortened treatment duration may be related to decreased bone mineral density levels, resulting in faster tooth movement. We believe that this topic needs further investigation in future studies.

CONCLUSION

Autism has a wide spectrum. Orthodontic malocclusions in mild autistic patients can be successfully treated. During this process, it is important to include communication as a major part of treatment.

Ethics Committee Approval: N/A.

Informed Consent: Written informed consent was obtained from the parents of the patient who participated in this study.

Peer-review: Externally peer-reviewed.

Author Contributions: Materials - Ö.P.Ö.; Analysis and/or Interpretation - Ö.P.Ö, S.İ.B.; Writing Manuscript – S.İ.B., Ö.P.Ö.; Other - S.İ.B., Ö.P.Ö.

Conflict of Interest: No conflict of interest was declared by the authors.

Financial Disclosure: The authors declared that this study has received no financial support.

REFERENCES

- Centers for Disease Control and Prevention. CDC Features: CDC study—an average of 1 in 110 children have an ASD. <http://www.cdc.gov/features/countingautism/>. Accessed Dec. 24, 2009.
- Luppanapornlarp S, Leelataweewud P, Putongkam P, Ketanont S. Periodontal status and orthodontic treatment need of autistic children. *World J Orthod* 2010; 11: 256-61.
- Chaushu S, Becker A. Behaviour management needs for the orthodontic treatment of children with disabilities. *Eur J Orthod* 2000; 22: 143-9. [CrossRef]
- Becker A, Shapira J, Chaushu S. Orthodontic treatment for the special needs child. *Prog Orthod* 2009; 10: 34-47.
- Hernandez P, Ikkanda Z. Applied behavior analysis: behavior management of children with autism spectrum disorders in dental environments. *J Am Dent Assoc* 2011; 142: 281-7. [CrossRef]
- Kamen S, Skier J. Dental management of the autistic child. *Spec Care Dentist* 1985; 5:20-3. [CrossRef]
- Lindemann R, Henson JL. Self-injurious behavior: management for dental treatment. *Spec Care Dentist* 1983; 3: 72-6. [CrossRef]
- Klein U, Nowak AJ. Autistic disorder: a review for the pediatric dentist. *Pediatr Dent* 1998; 20: 312-7.
- Grandin T. Calming effects of deep touch pressure in patients with autistic disorder, college students, and animals. *J Child Adolesc Psychopharmacol* 1992; 2: 63-72. [CrossRef]
- Zissermann L. The effects of deep pressure on self-stimulating behaviors in a child with autism and other disabilities. *Am J Occup Ther* 1992; 46: 547-51. [CrossRef]
- Aydemir H, Nebioglu-Dalci O, Altug AT, Toygar-Memikoglu U. The effects of tooth extraction and nonextraction on the soft tissue profile in patients with class ii division 2 malocclusion. *Turkish J Orthod* 2014; 27: 63-69. [CrossRef]
- Colakoglu S, Nalcaci R, Aktepe E, Ozyer G. Do different orthodontic malocclusions affect patients' self-concept and psychosocial status? *Turkish J Orthod* 2016; 29: 27-30. [CrossRef]
- Tsichlaki A, Chin SY, Pandis N, Fleming PS. How long does treatment with fixed orthodontic appliances last? A systematic review. *Am J Orthod Dentofacial Orthop* 2016; 149: 308-18. [CrossRef]
- Janson G, Maria FR, Barros SE, Freitas MR, Henriques JF. Orthodontic treatment time in 2- and 4- premolar extraction protocols. *Am J Orthod Dentofacial Orthop* 2006; 129: 666-71. [CrossRef]
- Neumeyer AM, Gates A, Ferrone C, Lee H, Misra M. Bone density in peripubertal boys with autism spectrum disorders. *J Autism Dev Disord* 2013; 43: 1623-9.[CrossRef]