

Abnormal subcortical activity in congenital mirror movement disorder with RAD51 mutation

Pınar Demirayak 


Onur Emre Onat 

Aslıhan Örs Gevrekci 

Süleyman Gülsüner 

Hilmi Uysal 

Rengin Bilgen 

Katja Doerschner 

Tayfun Özçelik 

Hüseyin Boyacı 

PURPOSE

Congenital mirror movement disorder (CMMD) is characterized by unintended, nonsuppressible, homologous mirroring activity contralateral to the movement on the intended side of the body. In healthy controls, unilateral movements are accompanied with predominantly contralateral cortical activity, whereas in CMMD, in line with the abnormal behavior, bilateral cortical activity is observed for unilateral motor tasks. However, task-related activities in subcortical structures, which are known to play critical roles in motor actions, have not been investigated in CMMD previously.

METHODS

We investigated the functional activation patterns of the motor components in CMMD patients. By using linkage analysis and exome sequencing, common mutations were revealed in seven affected individuals from the same family. Next, using functional magnetic resonance imaging (fMRI) we investigated cortical and subcortical activity during manual motor actions in two right-handed affected brothers and sex, age, education, and socioeconomically matched healthy individuals.

RESULTS

Genetic analyses revealed heterozygous RAD51 c.401C>T mutation which cosegregated with the phenotype in two affected members of the family. Consistent with previous literature, our fMRI results on these two affected individuals showed that mirror movements were closely related to abnormal cortical activity in M1 and SMA during unimanual movements. Furthermore, we have found previously unknown abnormal task-related activity in subcortical structures. Specifically, we have found increased and bilateral activity during unimanual movements in thalamus, striatum, and globus pallidus in CMMD patients.

CONCLUSION

These findings reveal further neural correlates of CMMD, and may guide our understanding of the critical roles of subcortical structures for unimanual movements in healthy individuals.

From the Neuroscience Graduate Program (P.D.

✉ pınarboyaci@bilkent.edu.tr, K.D., H.B.), A.S. Brain Research Center and National Magnetic Resonance Research Center (P.D., K.D., H.B.), and the Departments of Molecular Biology and Genetics (O.E.O., T.Ö.) and Psychology (K.D., H.B.), Bilkent University, Ankara, Turkey; Department of Psychology (A.Ö.G.), Başkent University, Ankara, Turkey; Department of Genome Sciences (S.G.), University of Washington, Seattle, WA, USA; Department of Neurology (H.U.), Akdeniz University School of Medicine, Antalya, Turkey; Department of Neurology (R.B.), Bezmialem University School of Medicine, İstanbul, Turkey; Department of Psychology (K.D., H.B.), J.L. Giessen University, Giessen, Germany.

Received 8 March 2018; revision requested 28 March 2018; last revision received 30 April 2018; accepted 6 May 2018.

DOI 10.5152/dir.2018.18096

Imagine yourself at a dining table. You are holding a glass of drink with one hand while with the other one you are reaching and grasping a salt shaker, then pouring salt on your dish, and finally you are putting the shaker on the table, releasing your grasp. While performing all the actions with the salt shaker, you easily hold your other hand steady, no water spills over (usually!) or you do not drop the glass. We routinely perform tasks that require unimanual movements such as this one effortlessly, without thinking, without even being aware of performing them. Yet, such unimanual movements actually require complex and intricate interactions between the components of the motor system: the system must suppress any movement on the unintended side, while performing the action on the intended side. Indeed bimanual symmetric hand movements are easier to perform, and “mirror movements”, involuntary, nonsuppressible, mirroring movements of extremities on one side of the body along with the homologous movements on the intended side, are common during development at early ages of life (1). With the completion of myelination of the corpus callosum and neurologic development in motor pathways mirror movements disappear (2, 3, 4). If the mirror movements do not disappear and persist in adulthood, they are considered abnormal (5).

You may cite this article as: Demirayak P, Onat OE, Örs Gevrekci A, et al. Abnormal subcortical activity in congenital mirror movement disorder with RAD51 mutation. *Diagn Interv Radiol* 2018; 24:392–401.

The etiology of abnormal mirror movements is diverse, including central nervous system disorders such as Klippel-Feil syndrome (6, 7), X-linked Kallman syndrome (8), ischemic stroke (9), and hemiplegic cerebral palsy (10). Unlike the aforementioned central nervous system disorders, congenital mirror movement disorder (CMMD) is characterized by persistent mirror movements with no other neurologic abnormalities (11). Genetic origin of CMMD may be familial or sporadic. Familial CMMD usually has an autosomal dominant inheritance pattern (12, 13). *RAD51* haploinsufficiency causes CMMD in humans (14). *RAD51* gene plays a critical role in healthy motor system development. It has a focal expression at the pyramidal decussation during critical neurodevelopmental stages. *RAD51* expression was detected in corticospinal axons at the pyramidal decussation in two-day-old mouse models and its deficiency specifically alters the development of an intact decussation tract (14). Results of other studies on affected human individuals suggest that heterozygous mutations in *DCC* gene also causes CMMD (15). The *DCC* gene is a receptor protein for netrin, which is involved in axonal migration of neurons across the body's midline during the developmental stage (16). Abnormalities in axon guidance and the corticospinal tract (CST) are observed in the absence of ephrin or *DCC* genes in knock-out animal studies (17, 18).

As we have discussed previously, abnormal cortical activity accompanies the mirror movements in CMMD (19, 20). However, the motor loop contains not only cortical areas, but also subcortical structures. Subcortical components of the motor system, including basal ganglia and cerebellum, provide effective control mechanisms. Thalamus is another key player for the information flow: it receives projections from the subcortical

nuclei and projects onto the cerebral cortex (21). These structures are critical to initiate, gate and terminate motor movements, but their roles in mirror movement disorder remain unknown. To address this knowledge gap in literature, using functional magnetic resonance imaging (fMRI), we investigated task-related brain activity, including that in thalamus and basal ganglia, in two CMMD patients with *RAD51* mutations and matched healthy participants.

Methods

Participants

Two brothers (aged, 29 and 30 years) exhibiting familial CMMD on the distal upper limbs were studied in task-based fMRI scans (see Supplementary Fig. 1). The patients were from a Turkish family with seven affected members. For the genetic assessments three generations of the family were examined, which revealed a *RAD51* deleterious mutation (see Supplementary Figs. 2–4). All affected individuals of the family exhibit mirror movements in hands, fingers, and forearms with onset in infancy without any associated neurologic abnormalities. Also, there were no structural abnormalities including infarction on their structural T1-weighted images. Ten age and sex-matched healthy participants (mean age, 30.9±5.04 years) were included as a control group.

Neurologic examinations of the patients were conducted by neurologists who were experienced on electrophysiology and movement disorders in our group. Severity of CMMD was rated by Wood-Teuber scale (0, no mirror movement; 1, hardly perceivable with repetitive mirror movement; 2, barely discernible with sustained mirror movement or obvious with brief-periodic mirror movements; 3, obvious and sustained repetitive mirror movement; 4, strong mirror movement activity in unintended side). Our patients were rated 3 in mirror movement scale with no mental retardation, normal speech and walking skills.

Informed written consent was obtained from all participants in accordance with the declaration of Helsinki and procedures and protocols were approved by the Institutional Human Subjects Ethics Committee (Approval Number:2010_08_32_2).

fMRI data acquisition

MRI data were acquired in a Siemens 3T MAGNETOM Trio scanner fitted with a 12-channel phase-array head-coil. High

resolution T1-weighted three-dimensional MPRAGE images were acquired in each session (single shot turbo flash; voxel size, 1×1×1 mm³; repetition time [TR], 2600 ms; echo time [TE], 3.02 ms; flip angle, 8 degrees; field of view [FOV], 256 × 224 mm²; slice orientation, sagittal; phase encode direction, anterior-posterior; number of slices, 176; acceleration factor (GRAPPA), 2). For the functional scans an echo-planar imaging (EPI) sequence was used (voxel size, 3×3×3 mm³; TR, 2000 ms; TE, 40 ms; flip angle, 71 degrees; FOV, 192×192 mm²; slice orientation, transverse; number of slices, 26). Subjects participated in two scanning sessions; each started with the structural scan, followed by the task-based functional runs.

Experimental procedures

In a block-design protocol participants performed index finger tapping movement following visually presented cues during a 12 s active block. Active blocks were repeated for five times interspersed with 12 s rest blocks. Visual stimuli were composed of a green arrow placed at the center of the stimulus display and pointed to the side of required movement (left, right and both) for the active conditions as well as a closed-end green line for the rest condition. Our group created the experimental stimulus using the Java programming platform.

Data were preprocessed using the tools in Statistical Parametric Mapping software (SPM8, <http://www.fil.ion.ucl.ac.uk/spm/software/spm8/>) implemented in MATLAB (Mathworks, Inc.). Preprocessing steps included image realignment, slice acquisition-time correction, and functional and anatomical image coregistration. Functional images were normalized to Montreal Neurological Institute's (MNI) template by fitting mean functional images to the single reference EPI standard SPM template, and smoothed with a 6 mm Gaussian kernel to reduce spatial noise. Next, first level statistical parameters were computed for each participant using the GLM procedure implemented in FSL fMRI Expert Analysis Tool FEAT, version 5.6.3. Contrasts of right finger movement versus rest, left finger movement versus rest, and bimanual finger movement versus rest were defined to obtain z-score maps over the whole brain. To compare control and patient groups, spherical regions of interest (ROIs) were created by using FSL in the bilateral M1s (hand area), SMA, thalamus, globus pallidus, putamen and caudate with 6 mm Gaussian

Main points

- Congenital mirror movement disorders (CMMD) are closely related to abnormal primary motor cortex and supplementary motor area activity during unimanual movements.
- Increased bilateral activity is present in CMMD patients in thalamus, striatum, and globus pallidus during unimanual movements.
- Activity of subcortical nuclei was higher in CMMD patients, which shows that involvement of these structures is also critical for unimanual movements.

kernel radius on each participants' functional data (Table 1). Putamen and caudate ROIs were combined and analyzed as striatum since they are histologically identical and both are composed of similar projection fibers (22). Then these ROIs were binarized and applied onto the z-score maps of individuals for each contrast.

Statistical analysis

The mean z-scores were analyzed by conducting a mixed design 3-way ANOVA (Group × Task side × Hemisphere) to compare activations in unimanual movements. Bilateral movements were analyzed through a mixed design 2-way ANOVA (Group × Hemisphere). Tukey's post hoc analyses

were performed where appropriate. Statistical parametric maps were projected onto 3D morphed brain surface to visualize the cortex activation, and onto 2D T1-weighted images to visualize activation in subcortical structures by using BrainVoyager QX 2.8.

Results

We measured fMRI BOLD (blood-oxygen-level-dependent) activity in thalamus, striatum, globus pallidus, supplementary motor area (SMA) and the hand area of primary motor cortex (M1) during a finger tapping task (left, right, bimanual). We summarized demographic characterization of both groups and statistical results in Table 2. Also, Figs. 1 and 2 show the statistical parametric maps on inflated cortices as well as average fMRI responses in some of the predefined ROIs. fMRI responses, more specifically the z-scores, in the ROIs were compared between the patients and controls by using mixed-design ANOVAs and Tukey's post-hoc correction where appropriate. For the bimanual movement we found no main effect of group or hemisphere in any of the areas tested. During the bimanual movement BOLD activity in predefined ROIs was not statistically different between the patient and control groups nor between right and left hemispheres. For the unimanual movements, activations of M1, thalamus, and striatum showed group main effect (M1: $F(1, 10)=10.761$, $P = 0.008$; thalamus: $F(1, 10)=8.686$, $P = 0.015$; striatum:

Table 1. MNI coordinates of the center of the spherical ROIs that were used in task-based fMRI comparisons

Region	MNI coordinates (x, y, z)
Left primary motor cortex	-42, -16, 52
Right primary motor cortex	39, -22, 52
Left supplementary motor area	-9, -16, 67
Right supplementary motor area	12, -16, 67
Left thalamus	-12, -19, 4
Right thalamus	12, -19, 4
Left putamen	-21, 8, -5
Right putamen	24, 8, -5
Left caudate	-15, 14, 10
Right caudate	15, 14, 10
Left globus pallidus	-15, -4, -5
Right globus pallidus	18, -4, -5

MNI, Montreal Neurological Institute; fMRI, functional magnetic resonance imaging.

Table 2. Demographic characteristics and summary of the unimanual task-based fMRI comparisons

	CMMD	Controls	ANOVA F(1,10)			Interaction	t statistics t (df=10)
			Factor 1: Group	Factor 2: Task	Factor 3: Hemisphere		
n	2	10	-	-	-	-	-
Sex (M/F)	2/0	10/0	-	-	-	-	-
Age (y)	29.5	30.9±5.04	-	-	-	-	0.377 (10)
M1	-	-	10.761 ^b	0.018	0.019	factor 2 × factor 3 20.235 ^b	L M1:-2.686 ^a R M1:-4.014 ^b
SMA	-	-	0.822	0.077	6.884 ^a	factor 2 × factor 3 5.666 ^a factor 1 × factor 3 9.225 ^a	NS
THA	-	-	8.686 ^a	0.049	0.064	factor 2 × factor 3 10.028 ^a	L THA:-2.935 ^a R THA:-2.495 ^a
GP	-	-	4.893	0.487	0.586	NS	NS
STR	-	-	7.069 ^a	0.769	0.868	NS	R STR:-3.337 ^b

fMRI, functional magnetic resonance imaging; ANOVA, analysis of variance; CMMD, congenital mirror movement disorder; M, male; F, female; NS, not significant; M1, primary motor cortex; L, left, R, right; SMA, supplementary motor area; THA, thalamus; GP, globus pallidus; STR, striatum.

^a $P < 0.05$, ^b $P < 0.01$, ^c $P < 0.001$.

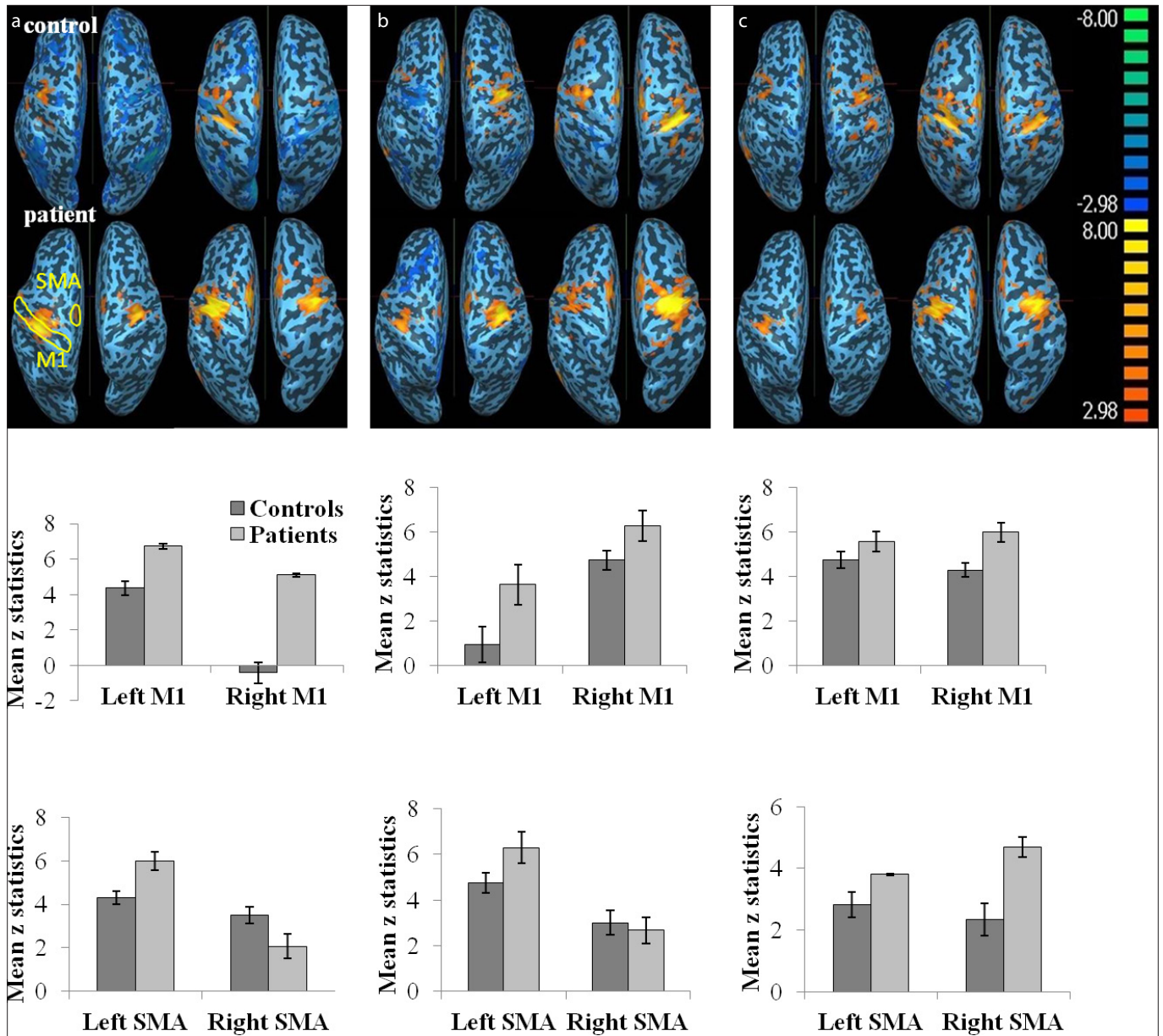


Figure 1. a–c. Comparison of fMRI responses in patients and controls in primary motor cortex hand area (M1) and supplementary motor area (SMA). Panels indicate right hand (a), left hand (b), and both hand (c) movements. Top row: Statistical parametric maps for a representative control and a patient during finger tapping. Bar plots: fMRI responses in predefined regions of interest (ROIs). Abnormal lateralization in M1 in patients is clearly seen in the statistical parametric maps. Abnormal activity pattern was also observed in SMA in patients: in controls, left SMA activity was always larger than right SMA activity, but not in patients. Error bars show ± 1 standard deviation. Color bar for the statistical parametric map indicates the t-score ranging from -8 (blue) to 2.98 (yellow). Maps are thresholded at an alpha level of 0.05.

$F(1,10)=7.069, P=0.024$). Activity in M1, thalamus, and striatum was statistically different between patients and healthy controls during the unimanual movement execution. However, the activity in globus pallidus showed a marginal trend toward significance between patient group and healthy controls. In globus pallidus, group main effect during unimanual movements was observed with marginal statistical significance (globus pallidus: $F(1,10)=4.893, P=0.051$). There was an interaction between hemisphere and

task side in M1, thalamus, and SMA (M1: $F(1, 10)=20.235, P=0.001$; thalamus: $F(1, 10)=10.028, P=0.010$; SMA: $F(1, 10)=5.666, P=0.039$). The interaction showed that ipsilateral motor activity was greater in patients compared with controls in M1, thalamus, and SMA areas, whereas there was less or no intergroup difference in the contralateral side during both right and left unimanual finger movements. In SMA we also found a main effect of hemisphere ($F(1, 10)=6.884, P=0.025$) and interaction between hemisphere and

group ($F(1, 10)=9.225, P=0.013$). The activity in SMA was statistically different between left and right hemispheres during the unimanual right and left finger movements in both patient and control groups. Also, motor activity was statistically different in the left SMA between patients and control groups (i.e., mean z-score of the left SMA was always larger in controls), whereas the difference was smaller during the right finger movement or nonsignificant during the left finger movement in the right SMA (Fig. 1, Table 2).

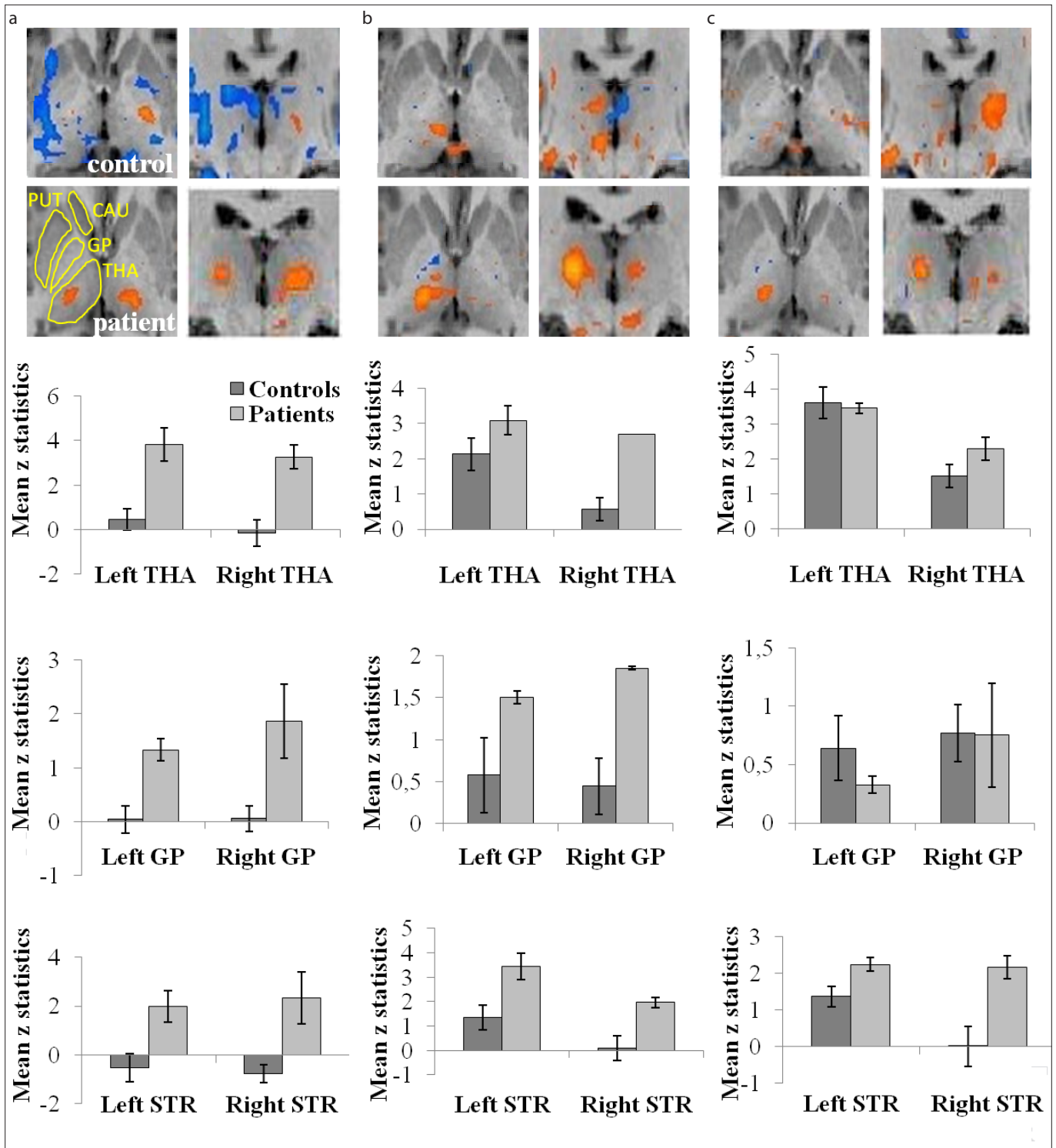


Figure 2. a–c. Comparison of fMRI responses in patients and controls in thalamus (THA), globus pallidus (GP), and striatum (STR, consisting of caudate nucleus [CAU] and putamen [PUT]) shows abnormal activity in patients. Panels indicate right hand (a), left hand (b), and both hand (c) movements. Top row: Statistical parametric maps for a representative control and a patient during finger tapping. Bar plots: fMRI responses in pre-defined regions of interest (ROIs). Error bars show ± 1 standard deviation. Color bar for the statistical parametric map indicates the t-score ranging from -8 (blue) to 2.98 (yellow). Maps are thresholded at an alpha level of 0.05.

Further group comparisons between statistically significant variables were performed by using independent samples t-test. Our analyses revealed statistically significant differences during right finger movement

between groups in M1 and thalamus bilaterally and in the right striatum (Left M1: $t(10) = -2.686$, $P = 0.023$, right M1: $t(10) = -4.014$, $P = 0.002$; left thalamus: $t(10) = -2.935$, $P = 0.015$, right thalamus: $t(10) = -2.495$, $P = 0.032$; right

striatum: $t(10) = -3.337$, $P = 0.008$). Critically, in M1 there was a significant difference between left and right finger movements in controls (Right M1: $t(9) = -7.779$, $P < 0.001$, left M1: $t(9) = 9.976$, $P = 0.003$) but not in patients

(Right M1: $t(1)=-2.021$, $P = 0.293$, left M1: $t(1)=2.992$, $P = 0.205$). Responses obtained from thalamus during unimanual movements were significantly higher in patients (Fig. 2). In globus pallidus, a similar trend was observed with marginal statistical significance ($F(1,10)=4.893$, $P = 0.051$).

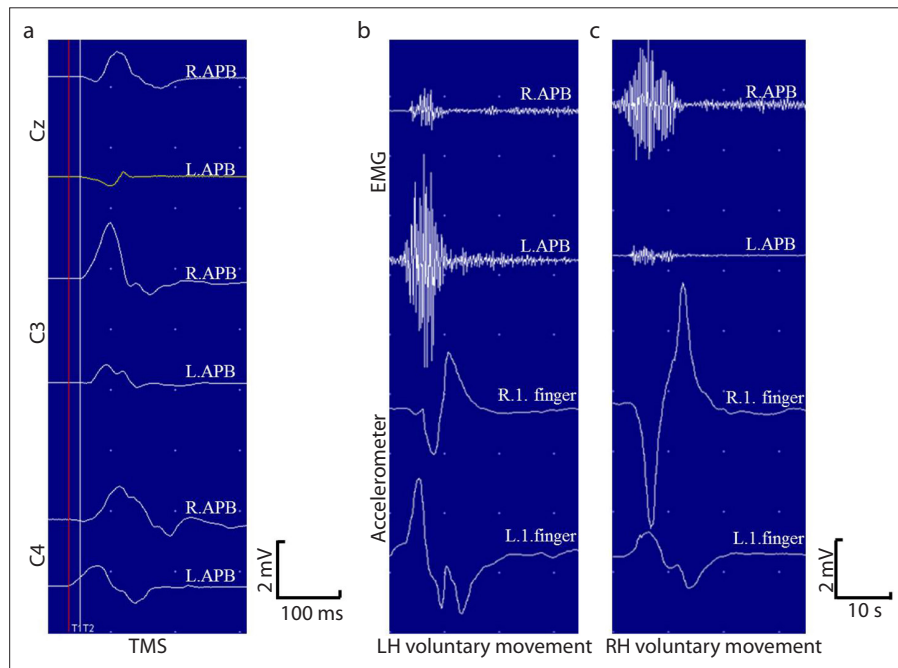
In summary, our analyses revealed abnormal lateralization in M1 and SMA during unimanual movements, which is consistent with previous findings in the literature (19). Furthermore, we have also found previously unknown abnormal activation in thalamus, and in the components of basal ganglia.

Discussion

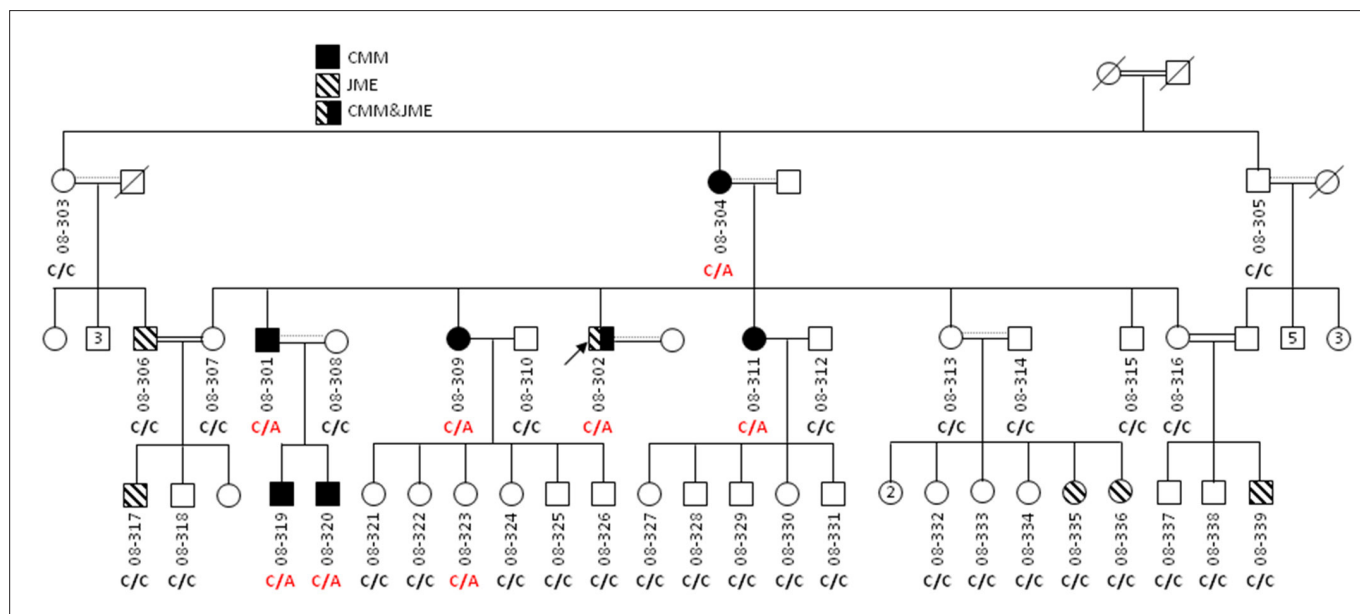
We investigated task-related activity within the components of the motor system of CMMD patients with *RAD51* mutation. Task-related fMRI results showed abnormal activity in M1, thalamus, striatum, globus pallidus (marginally significant) and SMA in the patients. Results highlight that execution of unilateral motor movements critically depends on the healthy interactions not only at the cortical level but also at subcortical levels.

Two main, but not mutually exclusive, hypotheses have been proposed to explain the mirror movement disorder at the nervous system level. One hypothesis posits that mirror movements occur because of abnormally uncrossed corticospinal fibers originating in primary motor cortices (M1) (23). This hypothesis is supported by the temporal characteristics of bilateral electromyography (EMG) activity during the unilateral M1 activation (24, 25), and motor evoked potentials (MEPs) in transcranial magnetic stimulation (TMS) studies (19). In the neurologic examination part of the study our TMS results replicate the findings in the literature (Supplementary Fig. 1). Thus, abnormally uncrossed corticospinal fibers could be a contributing mechanism to CMMD with *RAD51* mutation.

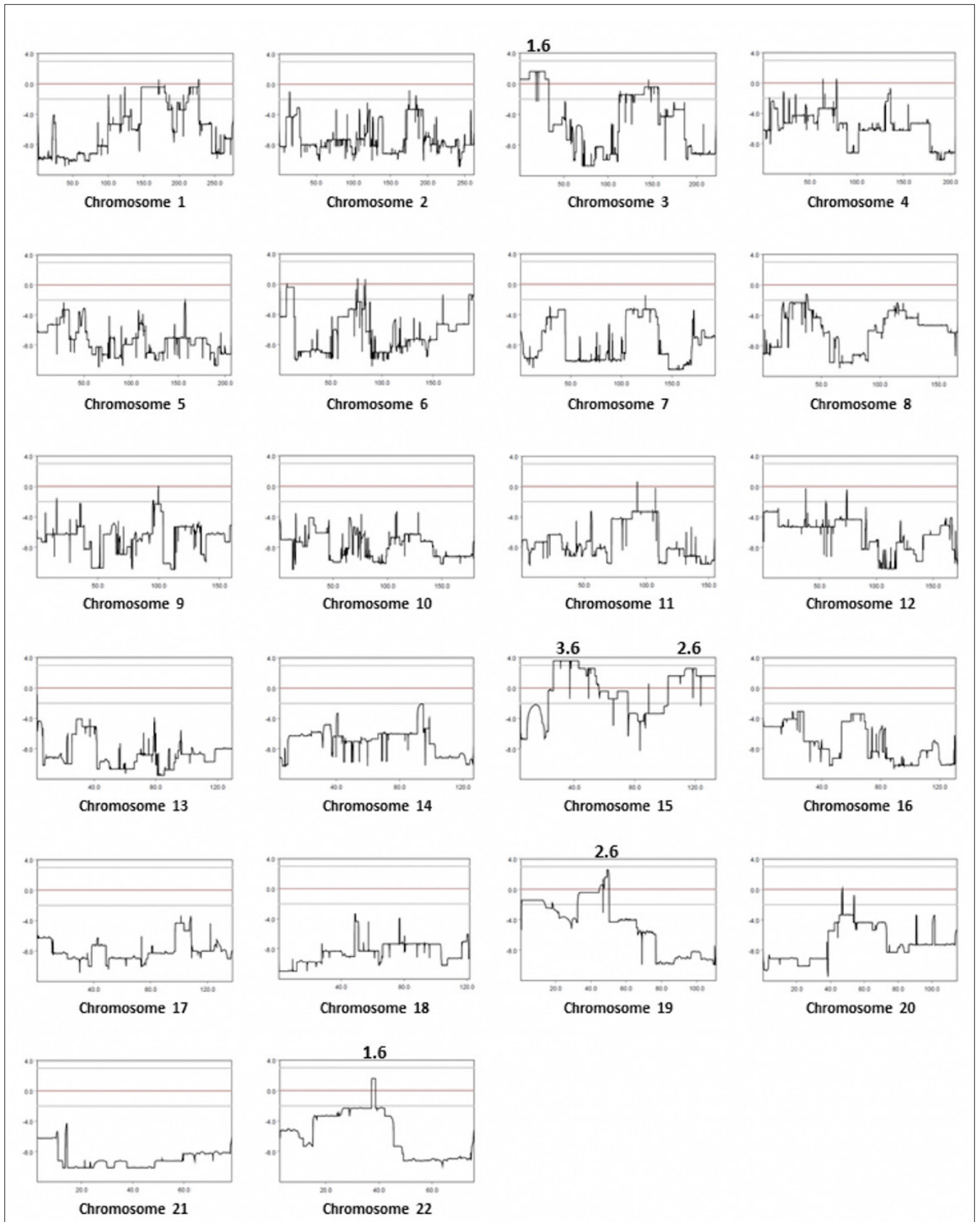
According to the other hypothesis, abnormally reduced lateralization of activity in M1 leads to mirror movements. In healthy individuals M1 activity is largely restricted to the contralateral side of the intended



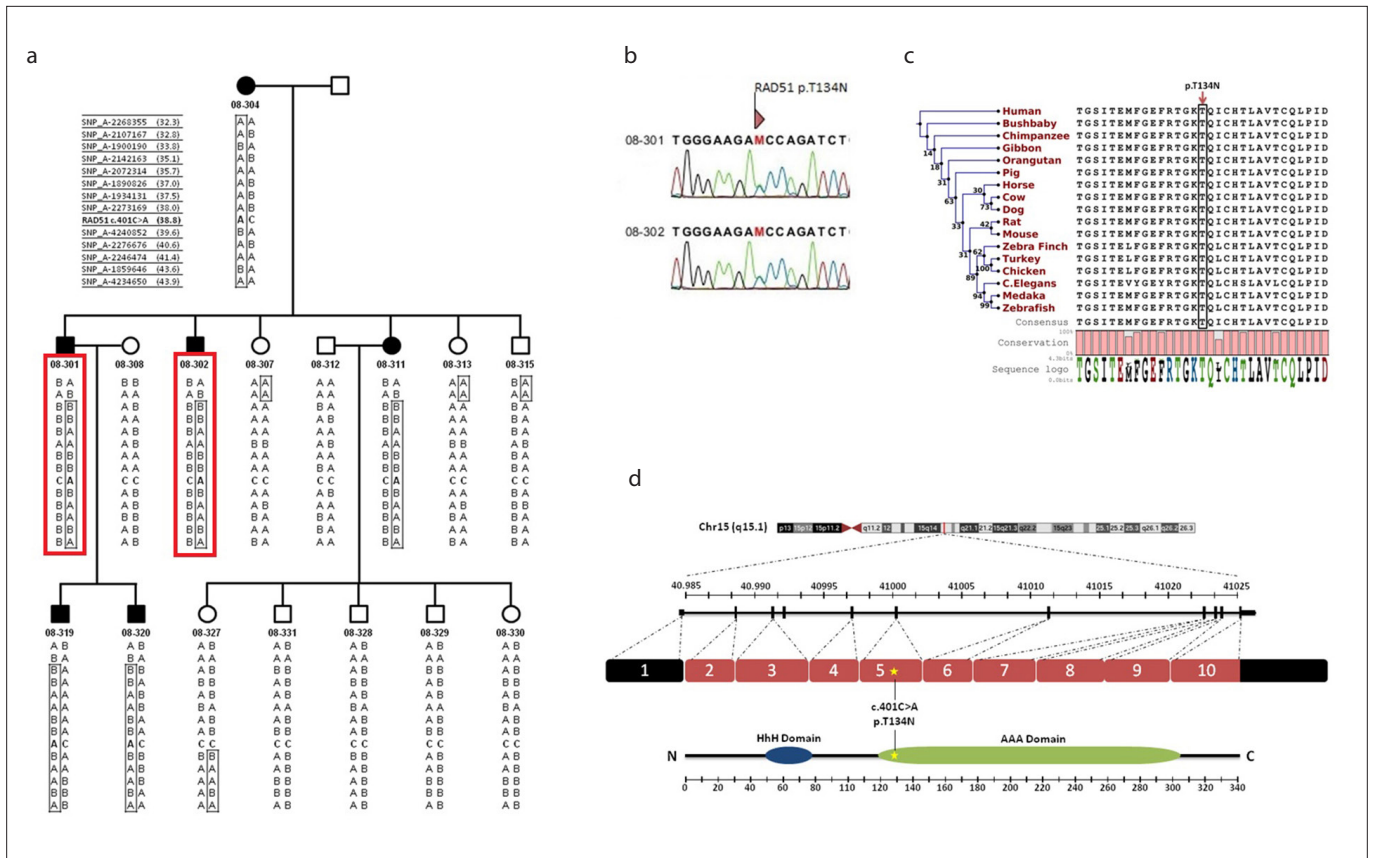
Supplementary Figure 1. TMS-induced motor evoked potentials (MEPs) and muscle activity during voluntary unimanual finger movements in a representative CMMD patient. Nonvanishing muscle activity on the unintended side clearly shows the signs of persistent mirror movements. Under the TMS-induced movements, the average latency between the MEPs from the intended and unintended sides was 1.7 ms. Cz, central midline stimulation; C3, left motor cortex hand area stimulation; C4, right motor cortex hand area stimulation; APB, abductor pollicis brevis; TMS, transcranial magnetic stimulation; LH, left hand; RH, right hand.



Supplementary Figure 2. Representation of the *RAD51* c.401C>A mutation co-segregated with the autosomal dominant CMMD in a family pedigree.



Supplementary Figure 3. Genome-wide linkage analysis. Selected participants' DNA from peripheral blood samples were genotyped using Asymetrix Gene Chip Human Mapping 250K Nsp microarrays. Experiments were performed according to the manufacturer's instructions (Asymetrix). Multipoint LOD scores were calculated with Merlin 1.1.2 software (1) (autosomal-dominant trait, disease AF of 0.0001, penetrance of 90%).



Supplementary Figure 4. a–d. Panel (a) shows the pedigree of selected members of autosomal dominant MM family with haplotype structure of the disease interval on chromosome 15q15.1. Haplotype segregating with the disease is boxed. RAD51 c.401C>A mutation is bold. Two brothers who participated in the MRI study are shown in a red box. Panel (b) shows conformation of the RAD51 c.401C>A mutation cosegregated with CMMD in all family members using Sanger sequencing. Panel (c) shows multiple amino acid sequence alignments indicating the sequence homology of RAD51 protein in vertebrates. T134 residue is indicated with a box. Panel (d) shows graphical representation of the predicted functional and structural elements of RAD51. The mutation lies in the N terminal of the AAA domain (yellow star).

unimanual movements. However, in CMMD patients there is an abnormally increased activity in M1 that is ipsilateral to the side of the intended voluntary movement, leading to a bilateral activation pattern in M1s (19, 20). The cause of this bilateral activity is largely unknown. Reduced or absent interhemispheric (19) or intracortical (26) inhibition could lead to this bilateral activation pattern. For example, irregular activity of secondary motor areas, which regulate the M1 activity, could lead to the abnormal bilateral M1 activity (23). In a recent study, Gallea et al. (19) investigated CMMD patients with RAD51 haploinsufficiency by using single-pulse TMS, diffusion-weighted imaging, and fMRI techniques. In those patients abnormal decussation of CST, bilateral M1 activity during intended unimanual movements, and abnormal interhemispheric inhibition were found (19). Furthermore, effective connectivity analyses of fMRI data revealed abnormal interaction between SMA and M1 during unimanual and

bimanual movements (19). In the present study, M1 activity was largely contralateral to the side of unimanual finger movements in healthy participants, whereas it was bilateral in patients. This kind of abnormal lateralization was previously observed in CMMD patients (7, 20). However, its cause is not clearly understood. It is known that the activity of M1 is regulated by other cortical and subcortical areas. For example, during a unimanual action, the activity of the M1 ipsilateral to the intended hand is temporarily suppressed (27). TMS studies also showed interhemispheric inhibitory interactions between the two M1s (28). Thus, it is possible that the abnormal ipsilateral M1 activity arises because of a lack of interhemispheric inhibition between the two M1s (19). At the cortex, SMA also showed abnormal activation pattern during unimanual movements in CMMD patients, once again consistent with previous findings (19). In normal controls left SMA activity was larger under all conditions (right, left, bimanual move-

ments). However, in patients activity was not equally strongly lateralized to the left SMA.

Although cortical abnormalities have been well documented in the literature, and shown to be consistent with our findings, activity patterns in subcortical structures have not been studied previously, despite their critical involvement in motor movements. Our results show that activity of thalamus, a subcortical structure, was also abnormal in the CMMD patients. Overall thalamic activity was larger in patients during intended unimanual finger movements. Similarly, BOLD activity in the other subcortical structures including the components of basal ganglia, namely striatum and globus pallidus, activity was statistically different between patient and healthy control groups during unimanual finger movements (in globus pallidus statistically marginally significant). Thalamus is an important gateway for information projecting to and from the cortex, including the links

to sensory organs. Thus, any abnormality in the activity of thalamus could have severe repercussions in motor actions. Likewise, basal ganglia plays a key role in sequential movements in timing and selecting the specific muscles for the execution of movement (29). Basal ganglia consist of a set of nuclei located in cerebrum and has inhibitory GABAergic projection neurons (30). When striatal projections are activated by the cortex, due to their neurochemical properties they tend to suppress the tonically active pallidal output that projects to thalamus (30). By means of this pathway, activity of the striatal neurons may lead phasic decrease of discharge of activity of pallidal neurons, which in turn disinhibits the activity of the thalamus. Outcome of this disinhibition is facilitation of the motor cortex. SMA receives strong indirect projections from the basal ganglia via the thalamus (31). Abnormal connectivity between SMA and M1, along with the increased globus pallidus, striatum, and thalamic activity during task execution in patients may lead to mirror movements through blocking the non-mirroring transformation of unilateral movement in SMA.

Our patients carry *RAD51* mutation. *RAD51* gene is involved in repairing DNA double stranded breaks by homologous recombination (32). In addition, it is also linked to the development of the decussation tract in the spinal cord (33). Our findings suggest that the effect of *RAD51* mutation may not be limited to the organization of the decussation tract but also extend to overall organization of the motor system. The findings presented here could also be a consequence of a reorganization of the nervous system to compensate for the direct impact of the mutation during development. Longitudinal studies, including the developmental stages can help researchers resolve this confound. To better understand the biological background of the reorganization of cortical and subcortical nuclei, *in vivo* studies would also be needed. Functional and structural connectivity analyses between the components of the motor loop in CMMD with larger patient population may provide further information. Nevertheless, such a rare case study provides valuable information about the possible extent of the effects of *RAD51* mutation on human anatomical and functional brain architecture.

There are some limitations of our study that need to be taken into account when

interpreting the data. First, our patient group consists of only two individuals who have the same mutational locus. Despite the apparent uniformity of clinical features, functional effects of genetic heterogeneity of the disorder on motor circuit is not clear (33). Although we had conducted genetic analyses to a few other family members, we include only two individuals with the same genetic mutation to be able to conduct a controlled experiment to understand the effect of *RAD51* mutation on brain functions of individuals with congenital mirror movements. Second, with such a small sample size statistically significant differences may arise due to individual variability in brain anatomy (34). We therefore recruited 10 healthy controls to obtain normal distribution and increase our statistical power. Third, our study subjects do not have strictly balanced age and sex distribution, and hand preference is not equally represented. To be able to minimize the effect of age, sex, and hand preference on motor circuitry, demographic variables were kept constant between the patient group and healthy control group as in the literature (2).

In conclusion, we have found widespread functional abnormalities in brain structures of the motor loop in CMMD patients with *RAD51* mutation. Our findings suggest that mirror movements are highly correlated with abnormal neuronal activity not only in cortex but also in subcortical structures during the performance of unimanual finger movements. These findings highlight the critical roles of different components and connections in the motor system to accomplish coordinated unimanual movements in healthy individuals.

Financial disclosure

This work was funded by a grant of the Turkish National Scientific and Technological Council (TUBITAK 1001- 1085355).

Conflict of interest disclosure

The authors declared no conflicts of interest.

References

1. Cincotta M, Ziemann U. Neurophysiology of unimanual motor control and mirror movements. *Clin Neurophysiol* 2008; 119:744–762. [CrossRef]
2. Koerte I, Eftimov L, Laubender RP, et al. Mirror movements in healthy humans across the lifespan: effects of development and ageing. *Dev Med Child Neurol* 2010; 52:1106–1112. [CrossRef]
3. Heinen F, Glocker FX, Fietzek U, Meyer BU, Lücking CH, Korinthenberg R. Absence of transcallosal inhibition following focal magnetic stimulation in preschool children. *Ann Neurol* 1998; 43:608–612. [CrossRef]

4. Mayston MJ, Harrison LM, Stephens JA. A neurophysiological study of mirror movements in adults and children. *Ann Neurol* 1999; 45:583–594.
5. Reitz M, Müller K. Differences between congenital mirror movements' and associated movements' in normal children: a neurophysiological case study. *Neurosci Lett* 1998; 256:69–72. [CrossRef]
6. Farmer SF, Ingram DA, Stephens JA. Mirror movements studied in a patient with Klippel-Feil syndrome. *J Physiol* 1990; 428:467. [CrossRef]
7. Royal SA, Tubbs RS, D'Antonio MG, Rauzzino MJ, Oakes WJ. Investigations into the association between cervicomedullary neuroschisis and mirror movements in patients with Klippel-Feil syndrome. *Am J Neuroradiol* 2002; 23:724–729.
8. Krams M, Quinton R, Mayston MJ. Mirror movements in X-linked Kallmann's syndrome. II. A PET study. *Brain* 1997; 120:1217–1228. [CrossRef]
9. Lindenberg R, Renga V, Zhu LL, Nair D, Schlaug GM. Bihemispheric brain stimulation facilitates motor recovery in chronic stroke patients. *Neurology* 2010; 75:2176–2184. [CrossRef]
10. Farmer SF, Harrison LM, Ingram DA, Stephens JA. Plasticity of central motor pathways in children with hemiplegic cerebral palsy. *Neurology* 1991; 41:1505–1505. [CrossRef]
11. Cincotta M, Borgheresi A, Boffi P, et al. Bilateral motor cortex output with intended unimanual contraction in congenital mirror movements. *Neurology* 2002; 58:1290–1293. [CrossRef]
12. Sharafaddinzadeh N, Bavarsad R, Yousefkhah M, Aleali A. Familial mirror movements over five generations. *Neurol India* 2008; 56:482–483. [CrossRef]
13. Srour M, Philibert M, Dion MH, et al. Familial congenital mirror movements: report of a large 4-generation family. *Neurology* 2009; 73:729–731. [CrossRef]
14. Depienne C, Bouteiller D, Méneret A, et al. *RAD51* haploinsufficiency causes congenital mirror movements in humans. *Am J Hum Genet* 2012; 90:301–307. [CrossRef]
15. Srour M, Rivière JB, Pham JM, et al. Mutations in *DCC* cause congenital mirror movements. *Science* 2010; 328:592. [CrossRef]
16. Depienne C, Cincotta M, Billot S, et al. A novel *DCC* mutation and genetic heterogeneity in congenital mirror movements. *Neurology* 2011; 76:260–264. [CrossRef]
17. Kullander K, Croll SD, Zimmer M, et al. Ephrin-B3 is the midline barrier that prevents corticospinal tract axons from recrossing, allowing for unilateral motor control. *Genes Dev* 2001; 15:877–888. [CrossRef]
18. Finger JH, Bronson RT, Harris B, Johnson K, Przyborski SA, Ackerman SL. The netrin 1 receptors *Unc5h3* and *Dcc* are necessary at multiple choice points for the guidance of corticospinal tract axons. *J Neurosci* 2002; 22:10346–10356. [CrossRef]
19. Gallea C, Popa T, Hubsch C, et al. *RAD51* deficiency disrupts the corticospinal lateralization of motor control. *Brain* 2013; 136:3333–3346. [CrossRef]
20. Cox BC, Cincotta M, Espay AJ. Mirror movements in movement disorders: a review. *Tremor Other Hyperkinet Mov* 2012; 2:tre-02-59-398-1.

21. Hoshi E, Jean F, Carras PL, Strick PL. The cerebellum communicates with the basal ganglia. *Nat Neurosci* 2005; 8:1491. [\[CrossRef\]](#)
22. Jain M, Armstrong RJ, Barker RA, Rosser AE. Cellular and molecular aspects of striatal development. *Brain Res Bull* 2001; 55:533–540. [\[CrossRef\]](#)
23. Carson RG. Neural pathways mediating bilateral interactions between the upper limbs. *Brain Res Rev* 2005; 49:641–662. [\[CrossRef\]](#)
24. Foltys H, Sparing R, Boroojerdi B. et al. Motor control in simple bimanual movements: a transcranial magnetic stimulation and reaction time study. *Clin Neurophysiol* 2001; 112:265–274. [\[CrossRef\]](#)
25. Mayston MJ, Harrison LM, Quinton R, Stephens JA, Krams M, Bouloux PM. Mirror movements in X-linked Kallmann's syndrome. I. A neurophysiological study. *Brain* 1997; 120:1199–216. [\[CrossRef\]](#)
26. Cincotta M, Borgheresi A, Balzini L, et al. Separate ipsilateral and contralateral corticospinal projections in congenital mirror movements: neurophysiological evidence and significance for motor rehabilitation. *Mov Disord* 2003; 18:1294–1300. [\[CrossRef\]](#)
27. Leocani L, Cohen LG, Wassermann EM, Ikoma K, Hallett M. Human corticospinal excitability evaluated with transcranial magnetic stimulation during different reaction time paradigms. *Brain* 2000; 123:1161–1173. [\[CrossRef\]](#)
28. Wahl M, Lauterbach-Soon B, Hattingen E, et al. Human motor corpus callosum: topography, somatotopy, and link between microstructure and function. *J Neurosci* 2007; 27:12132–12138. [\[CrossRef\]](#)
29. Jueptner M, Weiller C. A review of differences between basal ganglia and cerebellar control of movements as revealed by functional imaging studies. *Brain* 1998; 121:1437–1449. [\[CrossRef\]](#)
30. Yin HH, Knowlton BJ. The role of the basal ganglia in habit formation. *Nat Rev Neurosci* 2006; 7:464–476. [\[CrossRef\]](#)
31. Hoover JE, Strick PL. Multiple output channels in the basal ganglia. *Science* 1993; 259:819–821. [\[CrossRef\]](#)
32. Kawabata M, Kawabata T, Nishibori M. Role of recA/RAD51 family proteins in mammals. *Acta medica Okayama* 2005; 59.
33. Schott GD, Wyke MA. Congenital mirror movements. *J Neurol Neurosurg Psychiatry* 1981; 44: 586–599. [\[CrossRef\]](#)
34. Scarpazza C, Sartori G, De Simone MS, Mechelli A. When the single matters more than the group: very high false positive rates in single case voxel based morphometry. *Neuroimage* 2013; 70:175–188. [\[CrossRef\]](#)